

The U wave in the electrocardiogram. More than an academic curiosity

Raúl Carrillo-Esper,* Luis Daniel Carrillo-Córdova,**
Dulce María Carrillo-Córdova,*** Carlos Alberto Carrillo-Córdova***

RESUMEN

La onda U fue descrita por Einthoven en 1903. A pesar del tiempo transcurrido desde su descripción inicial las bases electrofisiológicas que expliquen su génesis no son claras, por lo que se han propuesto varias teorías. La adecuada evaluación e interpretación de la onda U es importante en la práctica clínica, ya que su presencia puede ser marcador de enfermedad cardíaca. El objetivo de este artículo es revisar los conceptos actuales relacionados con la onda U, su génesis, significado y adecuada interpretación.

Palabras clave. Onda U. Electrocardiograma. Cardiopatía isquémica.

ABSTRACT

The electrocardiographic U wave was describe by Einthoven in 1903. Despite the time elapsed since its description the electrophysiological basis underlying the genesis of the U wave has not been precisely elucidated and several hypothesis have been proposed. Proper evaluation and interpretation of the U wave is useful to the clinician because it is a marker of heart disease. The aim of this paper is to review current concepts related to U wave, its genesis, significance and proper interpretation.

Key words. U wave. Electrocardiogram. Ischemic heart disease.

THE U WAVE IN THE ELECTROCARDIGRAM. MORE THAN ACADEMIC CURIOSITY

Willem Einthoven developed the first electrocardiograph machine. It was a simple string galvanometer capable of measuring small changes in the electrical potential as the heart contracted and relaxed (Figure 1).

After having decribed the electrocardiogram (ECG) in 1895, Einthoven first recognized in 1903 the U wave and extended the notion of the ECG in a seminal paper published in the Lancet in 1912. Einthoven described the U wave as being of considerable height in pathological cases, but as present also in normal hearts as a wave of small amplitude, present in 50% of all persons. The source of the U wave remained obscure to Einthoven but described two observations. First, the U wave was not of equal height in all hearts. Second, the end of the U wave lies after the second heart sound.^{1,2}



Figure 1. Dr. Willen Einthoven and the first electrocardiograph.

* Academia Nacional de Medicina. Academia Mexicana de Cirugía. Jefatura UTI, Fundación Clínica Médica Sur.

** Servicio Social, Fundación Clínica Médica Sur. *** Facultad de Medicina. UNAM.

Correspondencia:

Dr. Raúl Carrillo-Esper

Unidad de Terapia Intensiva. Fundación Clínica Médica Sur

Puente de Piedra, Núm. 150. Col. Toriello Guerra, C.P. 14050, México, D.F.

Tel. 5424-7200, Ext. 4139. Correo electrónico: revistacma95@yahoo.com.mx

The U wave is the last, inconstant, smallest, rounded and upward deflection, except in aVR, of the ECG. The U wave in normal subjects always has the same polarity as the T wave, and so when it inverts with respect to the T-wave is of diagnostic importance. With regard to their polarity relative to the T wave, three variants have been described: Patients with negative T waves and positive U waves are named Type I discordance, positive T waves with negative U waves are named Type II discordance, and the combination of negative T and negative U waves are named concordant polarity.³

The source of the U wave is uncertain. Since Einthoven's initial description of the U waves, a number of theories have been advanced to explain its origin including ventricular septum, papillary muscles, negative afterpotentials, Purkinje system, mechano-electrical feedback and early or delayed afterdepolarizations but controversies persist regarding whether the U wave is a purely electrical or mechano-electrical phenomenon.

In general five hypotheses addressing the genesis of U wave that have been put forth included:^{4,5}

- Delayed repolarization of the His-Purkinje system.
- Delayed repolarizations of some other portions of the left ventricle, principally the papillary muscles, named by Bufalari⁶ the "syndrome of the papillary muscles". The authors describe three different patterns:
 - a) Left papillary muscles syndrome. Negative U wave in left leads DI, aVL, V5-V6. Its observed in anterior myocardial infarction, hypertension and aortic valvular disease.

- b) Right papillary muscle syndrome. Negative U wave in DIII and sometimes in aVF and right precordial leads. Its observed in right ventricular enlargement and congenital heart disease.
- c) Biventricular papillary muscle syndrome. Negative U wave in all precordial leads, DII and aVL. Its observed in biventricular enlargement.

- Alteration in the normal action potential shape by after-potentials.
- After potentials caused by the mechanical forces in the ventricular Wall. New investigations indicate the electro-mechanical theory is true, except in the cases of long QT interval, where the M cell would have a decisive role.
- Prolonged repolarization in the cells of the mid-myocardium or M-cells. The M cells are a cell subpopulation located in the midmyocardium with very differentiated electrophysiological and pharmacological features. Antzelevich⁷ proposed that M-cells more abundant in mass and having a prolonged repolarization time comparable to Purkinje cells may be responsible for the recording of the U wave.

In the ECG the U wave is the deflection that follows the waves of depolarization (QRS complex) and repolarization (T wave). The U wave is not only the last electrical event of the cardiac cycle discernible with the ECG, is also the smallest. It has an asymmetric shape with rapid ascending limb and more slow descending limb and it is 170 ± 30 ms. In the frontal plane normal U wave is located $+60^\circ$ thus U wave is positive in II, III and aVF and negative in aVR and isoelectric in aVL. U wave is always lower than

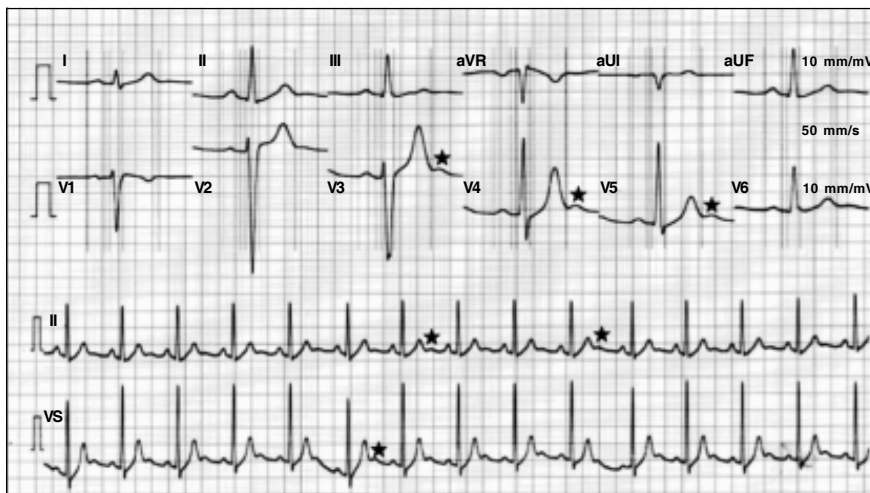


Figure 2. Electrocardiogram with U waves.

50% of the width of the preceding T and between 3 to 24% of it. It does not exceed 1 mm being in average of 0.33 mm (Figure 2).⁵

It is an extremely important wave, as it may be the earliest and the only marker of heart disease. There are two U wave patterns characteristic of heart disease.

U wave inverted

A negative U wave is highly specific for the presence of heart disease and is associated with other ECG abnormalities in 93% of cases. The main causes of negative U wave are:⁸⁻¹⁰

- Ischemic heart disease.
- High blood pressure.
- Valvular heart disease.
- Congenital heart disease.
- Hyperthyroidism.
- Primary cardiomyopathy.

Prominent U waves

U wave is considered prominent or high if it reaches 1.5 mm or more. The main causes of prominent U waves are:¹⁰⁻¹⁴

- Bradycardia.
- Early repolarization variant.
- Hypokalemia.
- Hypomagnesemia.
- Hypocalcemia.
- Hypothermia.
- Effect of class IA and III antiarrhythmic drugs.
- Digitalis effect.
- Mitral valve prolapse.
- Endocranial hypertension.
- Cardiomyopathies.
- Acquired complete atrioventricular block.
- Congenital long QT syndrome:

- a) U wave is an important clue in identifying the congenital long QT syndrome, such as the Jervel, Lange-Nielsen and the Romano Ward syndromes.¹⁵

CONCLUSIONS

Based on current knowledge the U wave is no longer a curiosity. It can occur in healthy subjects but may be a marker of heart disease. The proper evaluation of their characteristics is essential for correct diagnosis of its etiology which will be important to initiate the best treatment.

REFERENCES

1. Einthoven W. Die galvanometrische registrierung des menschlichen elektrokardiogram. *Pfugers Arch* 1903; 99: 472-8.
2. Einthoven W. The different forms of the human electrocardiogram and their signification. *Lancet* 1912; 1: 853-61.
3. Reining MG, Harizi R, Spodick DH. Electrocardiographic T-and U-wave discordance. *Ann Noninvasive Electrocardiol* 2005; 10: 41-6.
4. Bernardo DD, Murray A. Origin on the electrocardiogram of U-waves and abnormal U-wave inversion. *Cardiovasc Res* 2002; 53: 202-8.
5. Pérez RA, Ferreira C, Ferreira FC, Ferreira M, Meneghini A, Hiroshi A, et al. The enigmatic sixth wave of the electrocardiogram: The U wave. *Cardiol J* 2008; 15: 408-21.
6. Bufalari A, Furbetta D, Santucci F, Solinas P. Abnormality of the U wave and the T-U segment of the electrocardiogram: the syndrome of the papillary muscles. *Circulation* 1956; 14: 1129-37.
7. Antzelevitch C, Sicouri S. Clinical relevance of cardiac arrhythmias generated by after depolarizations. Role of M cells in the generation of U waves, triggered activity and torsades de pointes. *J Am Coll Cardiol* 1994; 23: 259-77.
8. Kishida H, Cole JS, Surawicz B. Negative U wave: A highly specific but poorly understood sign of heart disease. *Am J Cardiol* 1982; 49: 2030-6.
9. Sovari AA, Farokhi F, Kocheril AG. Inverted U wave, a specific electrocardiographic sign of cardiac ischemia. *Am J Emerg Med* 2007; 25: 235-7.
10. Girish MP, Gupta MD, Mukhopadhyay S, Yusuf J, Sunil TN, Trehan V. U wave: An important noninvasive electrocardiographic diagnostic marker. *Indian Pacing Electrophysiol J* 2005; 5: 63-5.
11. Viskin S, Heller K, Barron HV. Postextrasystolic U wave augmentation, a new marker of increased arrhythmic risk in patients without the long QT syndrome. *J Am Coll Cardiol* 1996; 28: 1746-52.
12. Hlaing T, DiMino T, Kowey PR, Yan GX. ECG repolarization waves: Their genesis and clinical implications. *Ann Noninvasive Electrocardiol* 2005; 10: 211-23.
13. Conrath CE, Opthof T. The patient U wave. *Cardiovas Res* 2005; 67: 184-6.
14. Viskin A, Zeltser D, Antzelevitch Ch. When U say "U waves," What Do U Mean. *Pacing Clin Electrophysiol* 2004; 27: 145-7.
15. Kirchhof P, Franz MR, Bardai A. Giant T-U Waves precede Torsades de Pointes in long QT syndrome. *JAAC* 2009; 54: 143-9.