



# Temporomandibular joint ankylosis treated with arthroplasty in a patient with reumathoid arthritis. A case report

## *Tratamiento con artroplastia de anquilosis de la articulación temporomandibular en un paciente con artritis reumatoide.*

### *Reporte de un caso*

Blanca Miranda Hernández,\* José Ernesto Miranda Villasana<sup>§</sup>

#### ABSTRACT

Temporomandibular joint (TMJ) ankylosis is a degenerative disease that produces a limitation of mouth opening, causing problems during feeding, occlusal disharmony, upper way obstruction and facial asymmetry in developing children. It presents a multifactorial aetiology with diverse factors as trauma, infections, inflammatory diseases, radiation-therapy, microsomnia, tumors and congenital diseases. Trauma is considered the most common factor. Rheumatoid Arthritis (RA) is a systemic chronic, inflammatory and autoimmune disease affecting diarthroidal joints and frequently a variety of organs. Rheumatoid Arthritis (RA) occurs worldwide, in all ethnic groups, with a prevalence of 0.3% to 1.5% of cases in the population. Females are 2.3 times more likely to be affected than males, the peak onset being between the fourth and sixth decades of life, but it may begin in childhood (JRA) <sup>1,2</sup> or later in life. Temporomandibular joint affects 50 to 60% of all patients with RA a year after the disease has become systemic.<sup>3,4</sup>

Case report: A 39 year old female patient with RA with a severe mouth opening limitation (4 mm) that had caused her malnutrition. The patient was receiving treatment at the Rheumatology and Maxillofacial Surgery Clinic where surgical procedure was performed carried out (bilateral TMJ arthroplasty and left side coronoidectomy), after the surgery the patient was able to open the mouth 31 mm; in a control appointment 18 months after the surgery there were no signs of recurrence.

**Key words:** Temporomandibular joint, ankylosis, arthroplasty.

**Palabras clave:** Articulación temporomandibular, anquilosis, artroplastia.

#### RESUMEN

La anquilosis de la articulación temporomandibular (atm) es un proceso degenerativo que implica una limitación de la apertura bucal, ocasionando trastornos en la alimentación, desarmonías oclusales, obstrucción de la vía aérea y en personas en desarrollo produce asimetrías faciales. Los factores etiológicos son multifactoriales entre los que encontramos traumatismos, infecciones, enfermedades inflamatorias, radioterapia, microsomnia, tumoraciones, aunque también puede ser congénita, siendo el trauma la causa más común. La artritis reumatoide (AR) es una enfermedad sistémica, crónica, autoinmune e inflamatoria que afecta preferentemente articulaciones diartroidales y frecuentemente una gran variedad de órganos. La artritis reumatoide (AR) se presenta en todo el mundo, no tiene predilección étnica y se presenta en un 0.3 a 1.5% de toda la población. Las mujeres se afectan 2:3 veces más que los hombres, en una edad entre la cuarta y sexta décadas de la vida; si se presenta antes se le llama artritis reumatoide juvenil (ARJ).<sup>1,2</sup> La ATM está involucrada en el 50 a 60% de los pacientes con AR un año posterior al comienzo de la enfermedad generalizada.<sup>3,4</sup> Se presenta el caso de paciente femenino de 39 años de edad, con AR y limitación de la apertura bucal de 4 mm, que le ocasionó un estado de desnutrición, bajo tratamiento por los Servicios de Reumatología y Cirugía Maxilofacial se realizó procedimiento quirúrgico de artroplastia bilateral y coronoidectomía unilateral izquierda, obteniendo las paciente una apertura bucal de 31 mm postoperatorios; teniendo un control a 18 meses con la misma apertura bucal sin presentar recidiva.

#### INTRODUCTION

Temporomandibular Joint (TMJ) ankylosis causes a mouth opening limitation that ranges from partial to complete mandibular immobility. This is a result of several diseases that affect the Temporomandibular Joint (TMJ) and the adjacent structures.

TMJ ankylosis is classified according to its location (intra or extra capsular) and according to tissues affected (osseous, fibrous or mixed).<sup>5</sup>

\* Maxillofacial Surgeon-Professor of Oral and Maxillofacial Surgery. Ignacio Zaragoza Regional Hospital -Mexico city- Mexico.

§ Maxillofacial Surgeon, Pemex Central Hospital -Professor at Iztacala Campus- National University of Mexico.

Received: 19 August 2005.

Accepted: 28 November 2005.

Este artículo puede ser consultado en versión completa en <http://www.medigraphic.com/facultadodontologiaunam>

In 1985, Sawhney classified TMJ ankylosis into four types according to severity. This classification is supported by tomographic observations.

**TYPE I:** Fibrous adhesion around the TMJ, interarticular space reduction causing condylar displacement restriction.

**TYPE II:** Bone bridge formation between the condyle and glenoid fossa.

**TYPE III:** When a fracture of condylar process presents and the condyle (head and neck) suffers ankylosis to the glenoid fossa.

**TYPE IV:** The whole TMJ architecture is replaced by an bone fusion of condyle, sigmoid notch and coronoid process to the glenoid cavity.<sup>6</sup>

Ankylosis causes asymmetry with mandibular deviation towards the affected side, a slight displacement of the occlusal plane meanwhile retrognathia and anterior open bite are commonly observed in patients suffering bilateral ankylosis.

The etiological factors of Rheumatoid Arthritis (RA) are unknown, although the susceptibility to this disease is genetically determined.

Most of the patients have an increased level of Human Leukocyte Antigen (HLA-DR4); these antigens have been related to the increased levels of Rheumatoid Arthritis and the severity of articular destruction (radiographically).

The RA has an autoimmune component, in 75% of the patients: a) the Rheumatoid Factor is linked with an acute and active period of the disease; b) the values of globular sedimentation and immunoglobulins (IgG and IgM) during the acute and chronic phases are higher; c) It is very common to find normocytic and hypochromic anemia; d) the amount of leukocytes can be normal or slightly increased although leukopenia can be found in cases of splenomegaly;<sup>7</sup> e) synovial liquid can be turbid with decrease of viscosity and increase of protein content and a slightly less glucose than normal, the leukocyte count oscillates from 5 to 50,000 cells per microlite.<sup>7-9</sup>

Surgical techniques have been classified in three groups:

1. Arthroplasty
2. Interposition technique
3. Complete articular reconstruction

Alloplastic and autogenous grafts are used to prevent the ossification of the joint, among the main

problems found with alloplastic grafts are fragmentation of the graft and migration of the graft and a reactions against it as a foreign body.<sup>10</sup> In relation to the autogenous grafts, a variety of autogenous materials have been used, such as costochondral grafts, dermis, and temporalis muscle or fascia, metatarsal fourth, fibula proximal end, sternoclavicular articulation, iliac bone, articular cartilage, etc.<sup>11</sup> however, besides the increase in operative time and sophistication of the procedure, complications at the donor site (eg, pneumothorax, pleuritic pain, infection) and at the recipient site (eg, resorption of the graft, fibrosis, and ossification) can occur.<sup>12</sup>

One of the most important risks lies in placing the condylar prosthesis close to the cerebral lobule; this kind of prosthesis is very expensive and placing it is only recommended when the placement of autogenous grafts have failed. Eggers used tantalum in 1946 as an interpositional graft. In 1960, Robinson used stainless steel to reconstruct the pit (cavity), he named his prosthesis Christensen. Nowadays the material used is *vitallium*. The AO/ASIF designed the type of prosthesis Ken-Vitek (K-V) for the pit, it has a condylar component.

Nowadays the most utilized prosthesis is produced by the Biomet-Lorenz group and has two components (a cavity built of high molecular weight polyethylene and a condylar prosthesis made with vitallium).<sup>13</sup> However, recurrence is a great problem, being present in 50% of the post surgical cases.<sup>14</sup>

Politis et al.<sup>15</sup> in 1987 proposed that the treatment of temporomandibular joint ankylosis should meet the following requirements:

1. Restore the vertical and protrusive movements and the laterality of movements of the mandible and an adequate opening of the mouth.
2. Restore and maintain the facial vertical dimension to obtain an adequate dental occlusion.
3. To obtain facial symmetry when at rest and during movements; during and after the period of development of the patient.
4. To avoid the post-surgical re-ankylosis.

In this paper an arthroplasty surgical technique of condylar and glenoid fossa remodeling as treatment of TMJ ankylosis is proposed; in a patient with RA with 14 years of evolution; the treatment was bilateral with a retroauricular modified approach in «E», and unilateral coronoidectomy.

An improvement in the mouth opening was obtained and at control follow up 18 months later no recurrence was observed.

## METHODS

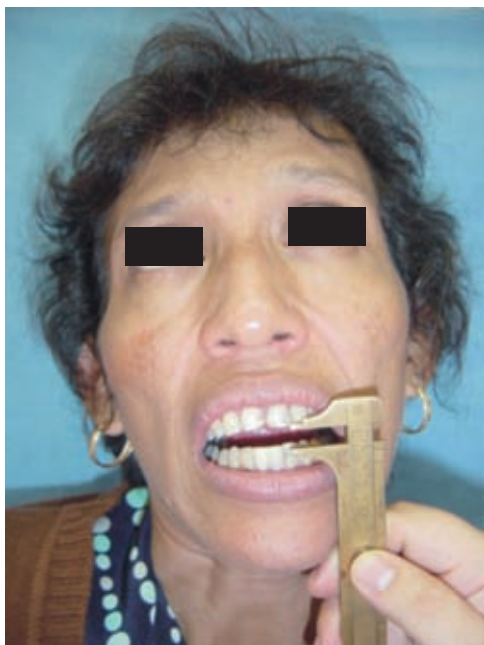The patient was treated with an arthroplasty surgical technique of condylar and glenoid fossa remodelling performed at the Maxillofacial Surgical Service of Hospital Regional «General Ignacio Zaragoza» ISSSTE.

39 years old female patient diagnosed with ankylosis of the Temporo Mandibular Joint as a consequence of Rheumatoid arthritis that had started 14 years before (when patient was 25 years old).

During the questionnaire the patient referred mouth opening limitation, anorexia, malnutrition, gastric ulcer caused by the difficulty to feed properly, constant stress provoked by the inability to vomit, repetitive nausea and drugs intake, constant articular pain, generalized asthenia and bouts of fever.

Among the clinical findings there is a poli-articular and symmetrical pattern where the affected articulations are distal and proximal inter-phalangeal, metacarpus-phalangeal, hip, shoulders, elbows, spine, cervical vertebrae (inability for rotation movements and neck flexion), knees and ankles, with morning stiffness lasting one hour or stiffness after an inactivity period.

The RA of this patient is class III because of pronounced restriction in daily and working activities and due to the need of assistance for ambulation purposes.



**Figure 1.** Initial evaluation. 4 mm mouth opening.

## TMJ CLINICAL FEATURES

Both TMJs were affected with severe articular pain with exacerbation and remission periods that prevented normal articular function, after a certain time the mandibular mobility diminished as well as the chewing strength.

The patient also referred bilateral clicking and crackling, that disappeared with time but the mouth opening limitation was greater (4 mm) (*Figure 1*). Upon arriving at the clinic the patient presented retrognathia and anterior open bite caused by the progressive loss of the bone height of the condylar head, and the activity of the osteoclast and lytic enzymes.<sup>15</sup> This latter situation produces a mandibular ankylosis type II according Sawhney.<sup>6</sup> The lesion can be corroborated with tomography scan images where the destruction of the articular disc, erosion of the bony surface of the condyle and the glenoid cavity have diminished the inter-articular space<sup>16</sup> (*Figure 2*).

At that moment the patient referred generalized morning stiffness that improved during the day or with function.<sup>2</sup>

## EXTRA-ARTICULAR CLINICAL FEATURES

Feverishness, general malaise, asthenia, lymphadenopathy, malnutrition, anemia, skin with nodules around the articular surfaces (pannus), palmar erythema.<sup>17</sup>

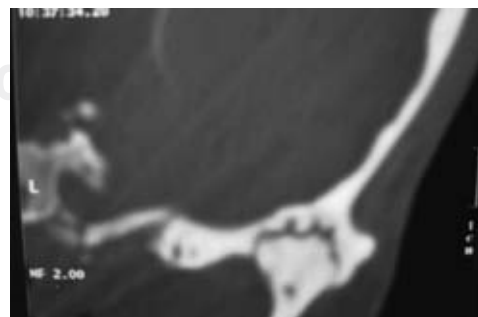The thorax x-ray and the electrocardiogram of the patient did not show any abnormalities.

The patient presented Sjögren syndrome, which is corroborated by an excisional biopsy of the minor salivary gland of the lower lip. The patient presented xerophthalmia, xerostomia that caused caries and generalized periodontal disease.<sup>18,19</sup>

## LABORATORY FINDINGS

Hematology:

Leucocytes: 5800 u/L; Neutrophils: 70.1%; Lymphocytes 13.6%; Monocytes: 14.5%, Eritrocytes  $4.6 \times 10^6$



**Figure 2.** Computerized scan (coronal section). Left temporomandibular joint.

u/L; Hemoglobin: 14.5 g/dL; Hematocrit: 42.6%, Platelets: 178,000 u/L; globular sedimentation rate (VSG) 31 mm/h. TP: 11.2 seg; TPT: 28.3 seg; INR: 1.1

#### Immunology:

Reumathoid Factor: 60.10 UI/mL; C-Reactive protein: 13.50 mg/L.

#### Blood Chemistry:

Glucose: 79 mg/dL; Urea: 16 mg/dL; Creatinine: 0.77mg/dL; Cholesterol: 139 mg/dL; Aspartate aminotransferase (TGO/AST) 32 U/L; Alanine aminotransferase (TGP/ALT) 46 U/L; Phosphatase alcaline 101 U/L.

### PHARMACOLOGICAL TREATMENT

Methotrexate 10 mg weeekly during 3 years, Leflunomide (Arava) 20 mg every 24 hours during 3 months, Chloroquine (Aralen) 250 mg every 24 hours during two years, NSAIDs diclofenac 100 mg or paracetamol 500 mg type occasionally.

The Rheumatology Specialists evaluated the treatment and considered that there was no clinical activity or RA and recommended 100 mg hydrocortisone, previous to, during and after the surgery to prevent reactivation of RA due to surgery. The base treatment with methotrexate, Arava and Aralen was interrupted during a month after the surgery, only the treatment with prednisone and diclofenac was maintained (7.5 mg every 24 hours and 75 mg every hours, respectively).

### SURGICAL TREATMENT

General anesthesia was administered with nasotracheal intubation. An infiltration 1.8 lidocaine with epi-

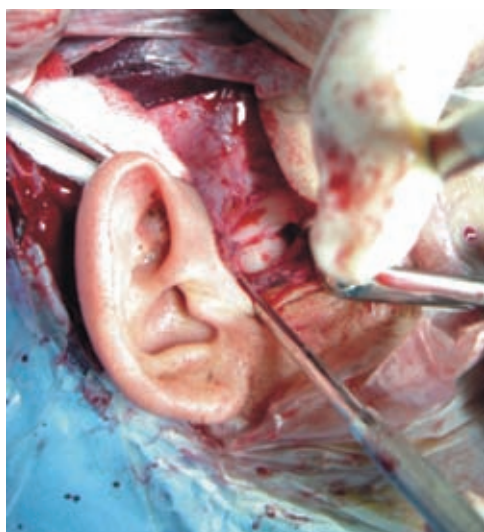
nephrine 2% was carried out in the surgical field, then the surgical incision was drawn having previously performed trichotomy, asepsis and antisepsis of the surgical field and placement of sterile drape. A retroauricular approach «E» modified was performed (*Figure 3*), taking in to account the measurements of Al-Kayat and Bramley to prevent facial nerve damage.<sup>20</sup>

A dissection was made to access the articular capsule with a «T» incision; a condylar retractor was placed behind the neck of the condyle to protect the maxillary artery during arthroplasty (ATM remodeling). With the stryker system arthroplasty was performed (*Figure 4*). With a 702 L surgical bur and then a larger round bur the mouth opening was corroborated.

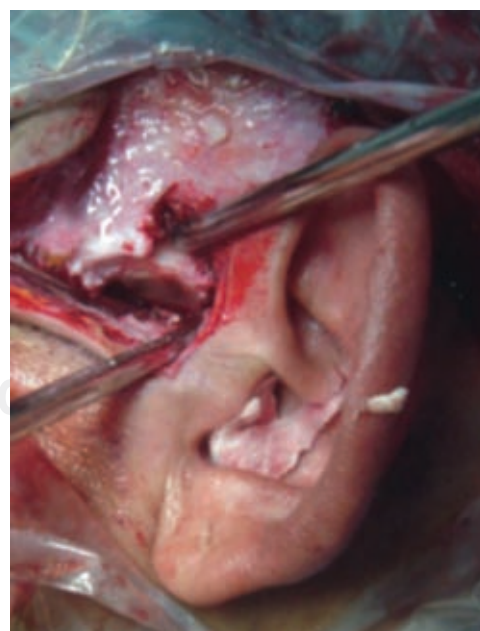
A manual guided mouth opening was done to observe condylar movements with direct vision of protrusive, lateral and retrusive movements observing the persistence of ankylosis, the left coronoid apophysis and temporal muscle detachment were located and a unilateral coronoidectomy was carried out (*Figure 5*).

The condylar movements and mouth opening were rectified with a relaxed patient still under the effects of general anesthesia, the articular surfaces were remodeled with a bone file, a Penrose drain under negative pressure was placed for hemostasis then it was sutured by planes with 3-0 vicryl for muscle and subcutaneous cellular tissue and nylon 4-0 for the skin.

During the immediate 24 after procedure, ice should be applied over the surgical region and then it should



**Figure 3.** Retro auricular approach «E» modified. Right TMJ with ankylosis type II.



**Figure 4.** Inter articular space created by arthroplasty. Left TMJ ankylosed.



be substituted for humid-hot compresses, antibiotic was prescribed (P.G.S.C 4,000,000 UI every 4 hours 7 days), 75 mg Intravenous diclofenac every 12 hours, oral prednisone 7.5 mg every 24 hours. The Penrose drain was removed 72 hours after the surgery and physiotherapy started 8 days after the surgical procedure.

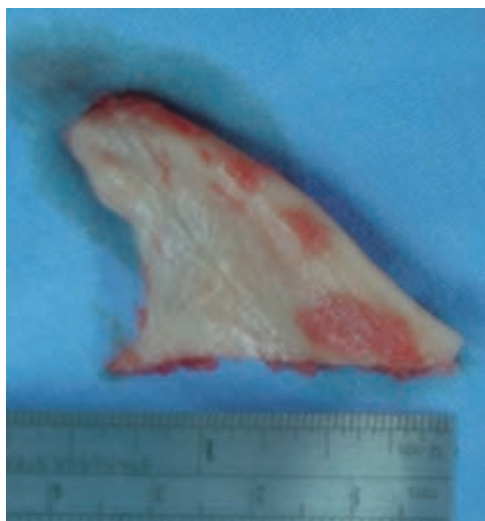
### RESULTS

Arthroplasty as a treatment for TMJ ankylosis in patients with RA resulted effective. This patient presented a decrease of the inflammatory process with reduction of the pain. The initial mouth opening was 4 mm and after the surgical procedure was 31 mm (*Figure 6*). The increased mouth opening allowed restoration of the functionality, a better feeding and as a result a better quality of life. With post surgical physiotherapy and monthly monitoring during 18 months the recurrence has been avoided.

This surgical procedure achieved excellent results with minimal and less aggressive procedures and reduced the cost.

### DISCUSSION

The most frequent cause of TMJ ankylosis is traumatism, followed by sepsis<sup>21</sup> and systemic inflammatory diseases. 0.3 to 1.5% of world population suffer Reumathoid Arthritis,<sup>1,2</sup> of this percentage 50 to 60% have temporomandibular joint problems. The challenge for the Maxillofacial Surgeon is to re-establish function and eliminate pain.<sup>3,4</sup>



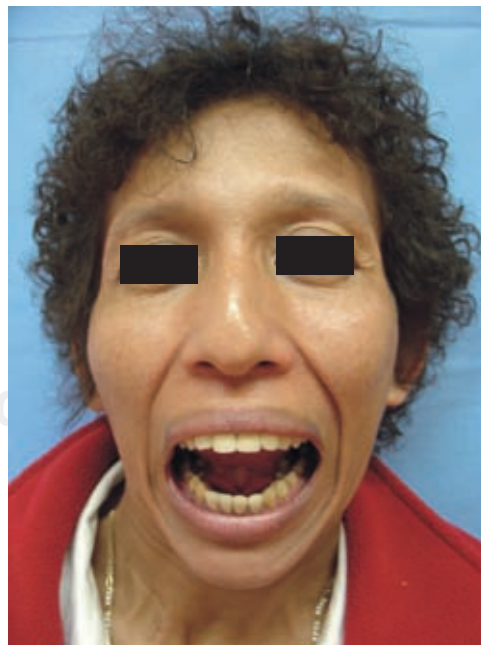**Figure 5.** Carried out left side coronoidectomy.

The main objectives of the ankylosis treatment are: to get a maximum mouth opening, to achieve optimal joint mobility, to avoid inflammation and pain and to restore the initial occlusion in order to obtain facial symmetry.

Several techniques have been described in the literature with different degrees of success. The surgical technique proposed in this article is the resection of the ankylosed segment and remodeling of the remaining bone structures that formed the joint without alloplastic or autologous grafts between the glenoid cavity and the mandibular condyle. The experience obtained utilizing arthroplasty as treatment for ankylosis gave excellent results for the recovery of the patient, who was able to recover the physiological movements of the joint and the facial symmetry. To obtain these results, a strict and close follow up during the postsurgical period was necessary.

### CONCLUSIONS

The obtained results in this case of bilateral ankylosis of TMJ in a patient with Reumathoid Arthritis history treated by the Maxillofacial Surgery Specialists of Hospital Regional «General Ignacio Zaragoza» was a success achieving an adequate mouth opening, an important decrease of the symptomatology and a closure of the anterior mouth bite.



**Figure 6.** 31 mm mouth opening, twelve months after the surgical procedure.

TMJ ankylosis treatment of patients with RA should be multidisciplinary because it requires previous control of the underlying systemic disease so that when rheumatoid arthritis is not in an active phase it can be surgically treated.

Arthroplasty is an effective surgical technique for the treatment of TMJ ankylosis that allows an adequate remodeling of articular bone structures. The results are sustained by Moss growth theory where muscle movement function favors the development of the articular spaces, achieving an optimal function of the masticatory system.<sup>22</sup>

According to this theory, it is necessary that after the surgical treatment, the patient must follow up a rehabilitation therapy. If this is not the case, the patient will not maintain the results for a prolonged time or will suffer reankylosis.

## REFERENCES

1. Arnett FC, Rheumatoid arthritis. In: Wyngaarden Jb, Smith LH, Bennett JC. *Cecil Textbook of Medicine*, ed. 19. Philadelphia. WB Saunders, 1988: 1508.
2. Fonseca JR, Bays R, Quinn P. *Temporal disorders*. Ed. Saunders Company. 2000; 4: 79.
3. Larheim TA. Rheumatoid arthritis and related joint diseases. In: Katzberg RW, Westesson PJ, eds. *Diagnosis of the temporomandibular joint*. Philadelphia: WB Saunders Co., 1993: 303-26.
4. Tegelberg A. *Temporomandibular joint involvement in rheumatoid arthritis: A clinical study*. Dissertation, University of Lund, Malmö, Sweden, 1987.
5. García-Aparicio L, Parri FJ, Sancho R. Anquilosis de la articulación temporomandibular (ATM) en la edad pediátrica. *Rev Cirugía Pediátrica* 2000; 13: 62-63.
6. Dorrit WN, Bar-Ziv J. Surgical management of temporomandibular joint ankylosis type III by retaining the displaced condyle and disc. *J Oral Maxillofacial Surgery* 1998; 56: 1133-1138.
7. Lipski EP. Rheumatoid arthritis. In: *Textbook of medicine Harrison*. Ed. Mc Graw Hill, Vol. II, edic. 13. p.1895.
8. Takatsuka S, Narinobou M, Nakagawa K, et al. Histologic evaluation of auricular cartilage grafts after discectomy in rabbit cranio-mandibular joint. *Journal Oral Maxillofacial Surgery* 1996; 54: 1216.
9. Tierney LM, McPhee S. *Diagnóstico clínico y tratamiento*. Edit. MM, 37va edic. 2002.
10. Dolwik MF, Aufdemorte TB. Sillione-induce foreign body reaction and lymphadenopathy after temporomandibular joint arthroplasty. *Oral Surg* 1983; 59: 449.
11. Zhou L. Auricular cartilage graft interposition after temporomandibular joint ankylosis surgery in children. *Journal Oral and Maxillofacial Surgery* 2002; 60: 985-987.
12. Raveh J, Vuillemin T, Ladrach K et al. Temporomandibular joint ankylosis: surgical treatment and long term results. *Journal Oral Maxillofacial Surgery* 1989; 47: 900.
13. Quinn DP. *Color Atlas of temporomandibular joint surgery*. Mosby, Chicago, 1998: 170-212.
14. Topazian RG. Comparison of gap and interposition arthroplasty in the treatment of temporomandibular joint ankylosis. *Journal Oral Surgery* 1996; 24: 405.
15. Politis C, Fossion E, Bossuyt M. The use of costochondral graft in arthroplasty of the temporomandibular joint. *J Craniomaxillofacial Surgery*. 1987; 15: 345-354.
15. Isberg A. *Disfunción de la articulación temporomandibular*. Edit. Artes Médicas. 2003: 121, 131.
16. Akerman S, Kopp S, Nilner M et al. Relationship between clinical and radiographic findings of the temporomandibular joint in rheumatoid arthritis. *Oral Sur Oral Med Oral Pathol* 1988; 66: 639.
17. Brad N, Douglas D. *Oral and maxillofacial pathology*. Edit. WB Saunders, 2nd Edition, 2002: 757.
18. Burgh NJ, Bramley P. *Libro de texto y Atlas en color de la articulación temporomandibular*. Edit. Mosby, 1993: 69-83.
19. Daniela TE, Fox PC. Salivary and oral components of Sjögren's syndrome. *Rheumatology Disease Clinics of North America* 1992; 18: 571-589.
20. Al Kayat A, Bramley P. A modified pre-auricular approach to temporomandibular joint and malar arch. *British Journal Oral Surgery* 1979; 17: 91-103.
21. Franc C, Breton P, Freidel M. Résultats tardifs du traitement chirurgical de l'ankylosis temporo-mandibulaire de L'Enfant. *Rev Stomatol Chir Maxillofac* 1997; 98: 263-265.
22. Moss ML, Rankow RM. The role of the functional matrix in mandibular growth. *Angle Orthod* 1968; 28: 95.

Mailing Address:

**Blanca Miranda MD**

La Rioja Núm. 45 Col. Zacatenco

Delegación: Gustavo A. Madero

07360 Distrito Federal

E-mail: blamir77@hotmail.com