



Endodontic procedure accidents. Case report

Accidentes de procedimiento endodóntico. Presentación de un caso

Tania Abigail Terrazas Ríos,* Germán González Pérez,* Maribel Liñan Fernández,* Mónica Ortiz Villagómez*

ABSTRACT

While undertaking endodontic procedures, setback can occur. These accidents are defined as unfortunate events taking place while performing endodontic therapy. Some of these events are a result of poor attention to detail, others are totally unpredictable. Some of these unfortunate events are perforation in the chamber of the floor of the mouth, or poor obturation of the canal system, which will lead to failure of the treatment. In drilling procedures, time is of the essence. The best time to repair root perforations is immediately after the accident occurs, minimizing thus the potential of infection at the perforation site. Use of restorative materials such as Mineral Trioxide Aggregate (MTA) offer better prognosis in perforations treatments.

Key words: Root canal, drilling, mineral trioxide aggregate.

Palabras clave: Tratamiento de conductos, perforación, mineral trióxido agregado [MTA].

RESUMEN

En el tratamiento endodóntico pueden ocurrir percances, estos accidentes se definen como aquellos sucesos infortunados que ocurren al realizar la terapia endodóntica, algunos de ellos por una falta de una atención, y otros, por ser totalmente imprevisibles, entre estos últimos, están la perforación en el piso cameral, así como una deficiente obturación del sistema de conductos, lo que condiciona aún más el fracaso del tratamiento. En las perforaciones el tiempo es un factor crucial. El mejor momento para reparar la perforación de la raíz es inmediatamente después de que esta ocurre para reducir al mínimo el potencial de aparición de la infección en el sitio de la perforación. El uso de materiales de restauración como el mineral trióxido agregado (MTA), proveen un mejor pronóstico en el tratamiento de las perforaciones.

INTRODUCTION

Root canal treatment is associated with unforeseen and unwanted random circumstances, these are generally defined as procedure accidents.¹ Accidents which occur during endodontic therapy can be defined as unfortunate events occurring during treatment, some due to lack of attention while others are totally unforeseeable. The endodontic misadventures classification proposed by Ingle describes instrument related accidents. Part of these are perforations in the cervical section of the canal, and misadventures related to obturation, among which we find overextended or underextended obturation of root canals.² A perforation, or false connection is the artificial communication between chamber or root canal system with support tissues of the tooth or to the oral cavity. Pathological causes like root resorption and caries can lead to a perforation. Nevertheless, the source is very often iatrogenic, as a result of an excessive use of the dental burr in the pulp chamber.³

In general terms, direct perforation occurs during the canal exploration. It is rather a «puncture» in the bifurcation carried out with the burr. Among the causes leading to this type of perforation are the lack of dental and pulpar anatomy, and, of utmost importance for endodontists, lack of radiographic information.⁴ When a perforation occurs, time is of the essence. The best moment to repair root perforations is immediately upon occurrence, so as to reduce as much as possible infection at the perforation site. It is not always possible

* This research was conducted at the endodontics Graduate clinic of the University of Querétaro, México (Autonomous University of Querétaro).

Received: 12 march 2010.

Accepted: 26 march 2010.

Este artículo puede ser consultado en versión completa en <http://www.medigraphic.com/facultadodontologiauam>

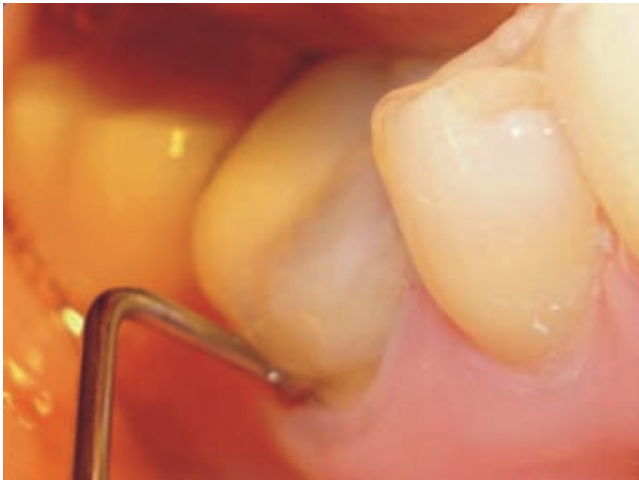

Figure 1. 9 mm probing of the vestibular third shows presence of pocket in furcation.

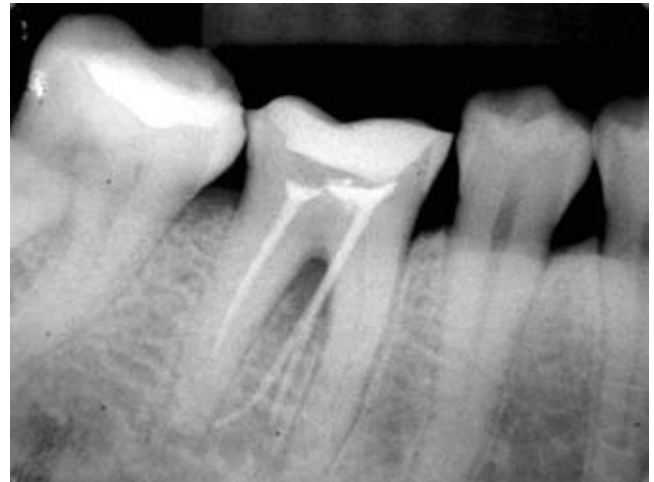


Figure 2. Initial X ray shows underobtured distal canal, mesial canals lacking filling and guttapercha cones in furcation zone. A radiolucent lesion in the furcation can also be observed.

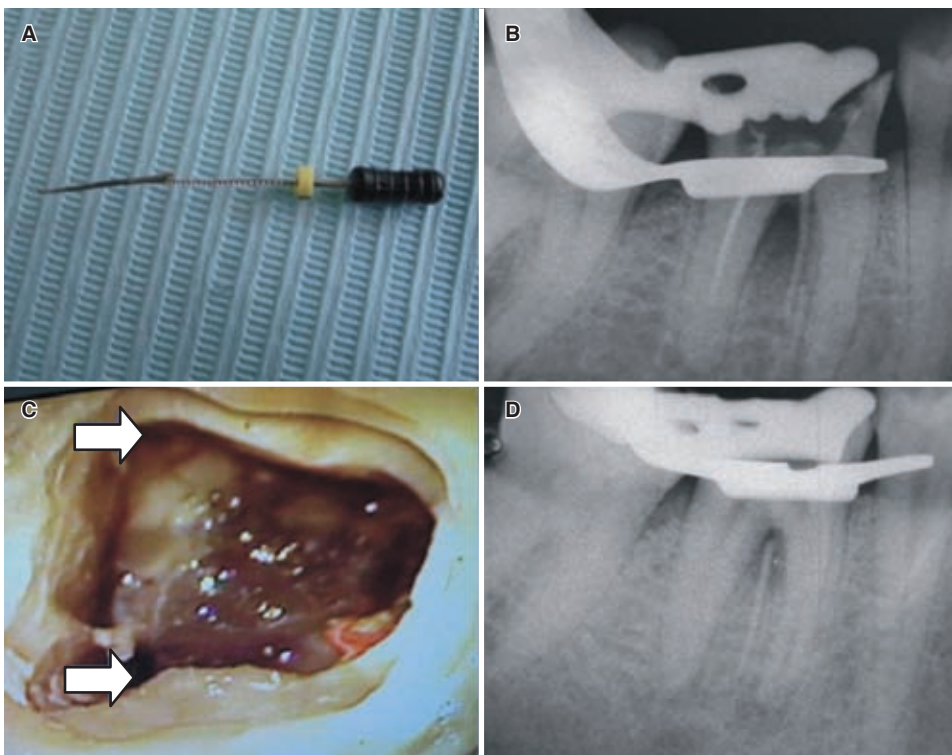


Figure 3. (A) Mesiolingual guttapercha cone through perforation and no. 40 K file. (B) X ray only shows one guttapercha cone. (C) Perforation areas in the mesial canals assumptions (arrows); (D) Distal duct not obtured and guttapercha point.

to properly handle the perforation because of the operator's lack of experience, or lack of proper equipment for its treatment. In these cases a proper temporal seal should be established to avoid bacterial passage.⁵

The size of the defect also plays an important role since large perforations do not respond as well as the

smaller ones.⁶ Large perforations can cause problems of incomplete sealing of the defect, thus allowing continual bacterial irritation at the perforation site.⁷ Smaller perforations are usually associated to lesser tissue damage and inflammation, and are easier to repair. Healing is more predictable and has a better

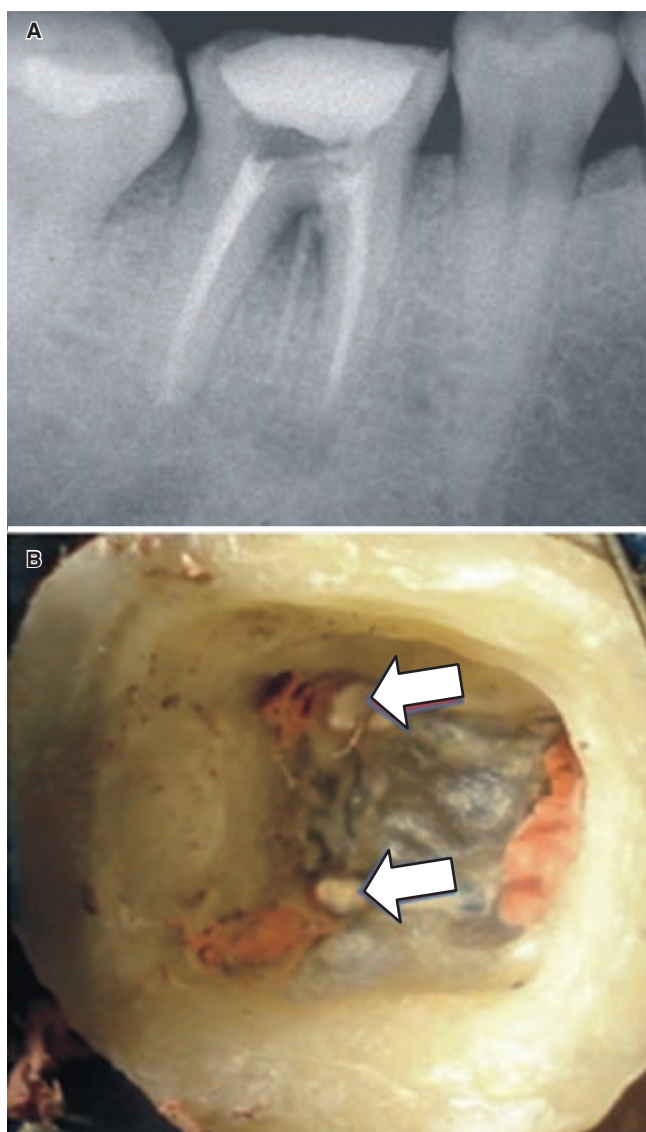


Figure 4. (A) Final X ray of mesial and distal canal fillings; the cone can be observed at the furcation. (B) Cavit is applied to perforations to avoid contamination.

prognosis. Small perforations are those caused with endodontic instruments size 15 or 20.⁸

The four circumstances to consider when treating endodontic accidents mishaps are: detection, correction, prognosis and prevention. Detection of a root perforation requires a combination of symptomatic findings, clinical observation and diagnostic means. Torabinejad informs that an immediate and typical sign is an abundant hemorrhaging emanating from the perforation site. A perforation can be detected through indirect means such as paper points or the radiographic image of a file in the bone or

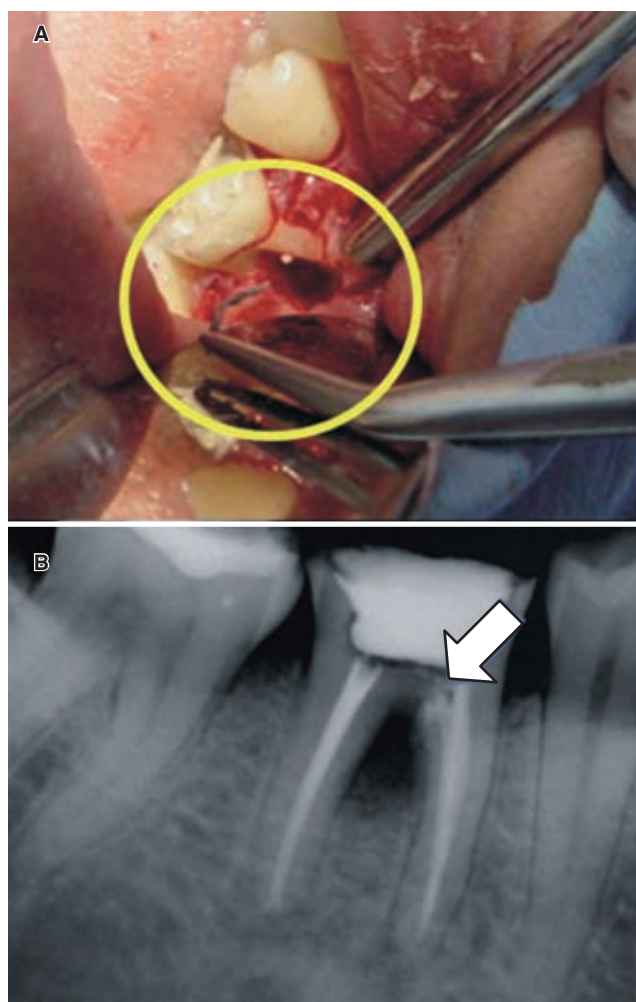


Figure 5. (A) Shows withdrawal of mesiovestibular cone located at the furcation. (B) Shows postoperative X ray where MTA application in perforations can be observed.

periodontal ligament. In cases when the patient is not under anesthesia he experiences a strong periodontal pain.⁹

Another aide for perforation diagnosis is the electronic apex localizer. Kaufmann considers it a reliable instrument and essential factor for treatment success. Readings show a working time shorter than the original work time length; this indicates a perforation.¹⁰ Authors like Gutman recommend to carry out a preoperative evaluation with two X rays for diagnosis, one in orthoradial direction, and the other with a 15 degree mesio or distoradial angulation.¹¹ Lasala points out certain criteria to avoid perforations:

1. Be cognizant with the pulpal anatomy of the tooth to be treated, proper access to be gained the chamber and guidelines for instrument use.

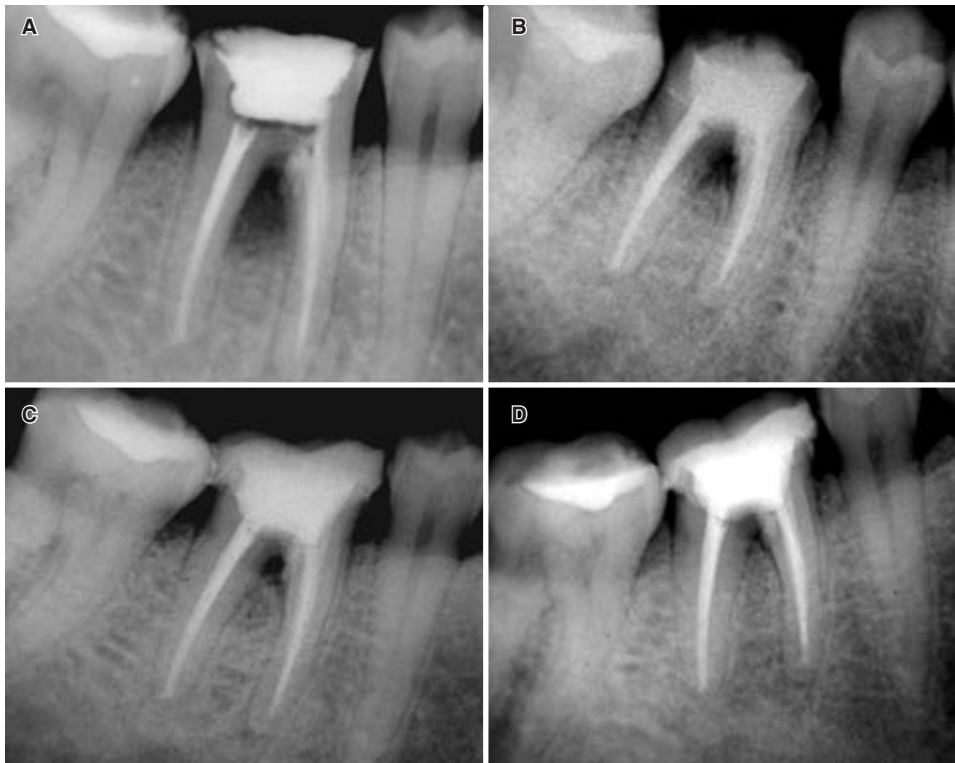

Figure 6. Control X rays: (A) after three months with provisional tooth. (B) after six months regeneration at furcation zone can be observed. The patient has not had a tooth restoration, it continues with double sealing CIV and ZOE. (C) after fine months the lesion has decreased in size. (D) after 15 months repair is considerable, tooth is asymptomatic.

2. To have tridimensional, positional criterion and perfect visibility.
3. In narrow canals be careful with the passage of instruments from 25 to 30, which could foster a perforation.
4. Avoid use of rotary instruments. There are to be used only when the case warrants it and the canals are sufficiently wide.

Prognosis of a perforated tooth is unfavorable.¹² Of all variables affecting long term prognosis, the most important parameter is the location of the perforation in relation to the crest, and the sealing potential of the restoration material.¹³ Another type of accident that can occur during endodontic therapy is underobturation. Rodriguez Ponce defines it as the obturation of the root canal away from the work length determined by a previous conductometry radiograph, this will lead to an endodontic failure.

If organic residues remain in the canal the most frequent underobturation causes are the creation of too short a stop, the lack of exact fit of the master cone, and lack of penetration of the filling material up to the predetermined work length. Correction is achieved through securing of a new determination of work length and proper obturation.¹⁴

CLINICAL CASE REPORT

A 30 year old woman lacking family or personal history of pathological data, arrives to the Graduate Endodontic Clinic of the Autonomous University of Queretaro, complaining of pain in the D.O. 46 area. She informs of root treatments carried out 3 months ago, she complains of nocturnal, spontaneous and localized pain when chewing. Upon inspection, a metal free restoration and an apparently healthy gingival are observed. As a response to periapical sensitivity tests, to palpation, to vertical and horizontal percussion, a positive response is elicited, with grade 1 mobility. When probing, a 9 mm periodontal pocket is detected in the vestibular middle third. Negative response was obtained to hot and cold pulpal sensitivity tests (*Figure 1*). Radiographic findings show non obturated mesial canals and a circumscribed periapical rarefaction. In the distal canal underobturation was found as well as guttapercha points in the furcation zone. A radiolucent area was also observed in that area. Presumptive and definitive pulpal diagnosis indicate pulpal necrosis and periapical presumptive and definitive diagnosis correspond to symptomatic chronic apical periodontitis (*Figure 2*). Treatment plan consisted in coronary or orthographic removal of the

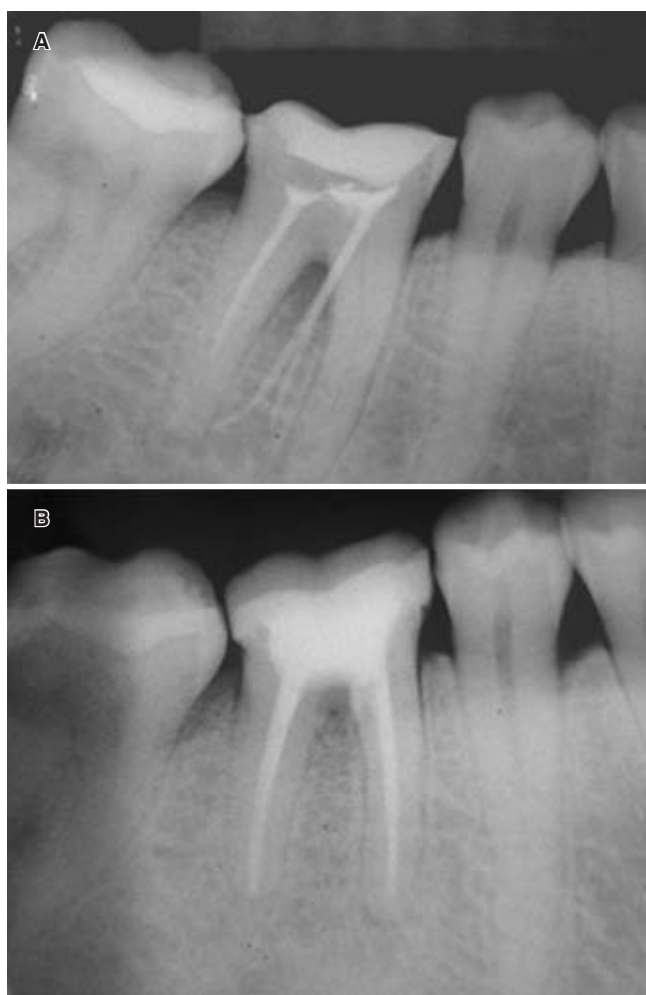


Figure 7. X rays: (A) diagnostic X ray with lesion in furcation in apical zone of mesial root, and guttapercha cones in furcation area. (B) 21 months after initiating treatment we can compare bone regeneration at the furcation and in the mesial root with the initial X ray, tooth continues to be asymptomatic.

guttapercha present in the furcation after that, canals were retreated, the perforation was sealed with Mineral Trioxide Aggregate (MTA). Surgery can also be contemplated in cases where coronary guttapercha removal from the furcation is not possible. Prognosis is guarded. The patient is anesthetized, the restoration is isolated, then removed. Obturations are identified. Mesiolingual guttapercha (ML) is extracted exclusively through a coronary approach, with a K type file, mesial canals are located with the help of an endodontic microscope, and perforations are temporary sealed with cavite. With the help of Hedstrom files the distal canal where underobturation is present is cleared. Neces-

sary working length for mesial canals is obtained at 17.5 mm and distal length at 18 mm (Figure 3). Use of instruments was performed manually, with coronary-apical technique and irrigation with 2.5% sodium hypochlorite. The master apical file for mesial canals is # 40. For the distal canal a file # 50 was used. Retraction was undertaken and final irrigation was carried out with 2.5% sodium hypochlorite, then 17% etilendi-aminotetraacetic (EDTA) acid was applied, after that, once more, 2.5% sodium hypochlorite was applied to finally neutralize with physiological serum. An chromometric X ray of the three canals is obtained, after that they are filled following cold lateral condensation technique and with epoxy resin based AHplus cement. An X ray is taken of the cone excess. A final X ray is taken to examine the mesiolingual (mL) guttapercha and the temporary seal of the perforations carried out with cavite (Figure 4). When carrying out surgery for guttapercha cone extraction and perforations sealing, the steps are as follows: first, asepsis of the operating field, to be followed by the raising of a modified Newman flap; osteotomy follows to identify the guttapercha point and then proceed to its removal. After this, cutting is carried out on the furcation zone to remove granular tissue. The site is cleansed with physiological solution. Perforations are sealed with MTA and finally, radiographic evidence identifies the perforations' sealing (Figure 5).

After three months, a control X-ray is taken. After six months the reconstruction of the stump for the crown can be observed. After nine months the tooth is restored, with proper bone regeneration in the furcation zone. After 12 months, radiographically, the repair of the defect is almost complete. Clinically, we can observe the restored tooth with a full crown free of metal, healthy gums, and when probing the middlevestibular third, we find 4 mm. We observe a clear improvement from the moment of initial treatment, and, 15 months after surgery we encounter good regeneration of the bone defect as well as sealing of both perforations (Figure 6). Finally a comparative follow up is carried out 21 months after finishing treatment and initial radiographic study (Figure 7).

DISCUSSION

Prognosis for a perforated tooth depends on the location of the perforation, the time in which the perforation allows entry of contamination, the possibility of sealing it and the accessibility of the main canal.¹⁵

In recent studies, a research group in Toronto found that in re-treatment cases only two factors significantly affected success in treatment: presence of a preop-

erative radiolucency and presence of a preoperative perforation.¹⁶

Among accidents with worse prognosis are perforations at bone crest level, specifically in the furcation since its proximity to the gingival sulcus favors bacterial contamination.¹⁷⁻¹⁹ Global index of success in the repair of these accidents, based in 55 cases, was 92%.²⁰ MTA is the most popular material to repair perforations. This material induces osteogenesis and cementogenesis. Different studies report on cement deposition on MTA.²¹

CONCLUSIONS

From this case we can conclude that the sooner the repair is carried out, the greater will be the possibility of success. In cases which prove to be most resistant, surgical correction will be required. In this case due to its inherent complication, endodontic surgery was performed, and through it, adequate repair was achieved. Prevention is the most important factor to avoid accidents during endodontic therapy. Benefits are always for the patient, who must receive the best possible treatment.

REFERENCES

- Walton RE, Torabinejad M. *Endodoncia, principios y práctica; Accidentes de procedimiento*. Ed. McGraw-Hill Interamericana, México. 2a edición, 1997: 329-336.
- Ingle J, Bakland L. *Endodoncia; Percances endodónticos: su detección, corrección y prevención*. 5ª edición, Editorial: McGraw-Hill Interamericana. México, D.F. 2004: 856-868.
- Lasala A. *Endodoncia; complicaciones y accidentes en el tratamiento y la obturación de conductos*. Editorial Salvat. 1992: 407-411.
- Walton 1997, *op cit*.
- Tsesis I, Fuss Z. Diagnosis and treatment of accidental root perforations. *Endod Topics* 2006; 13: 95-107.
- Lemon RR. Nonsurgical repair of perforation defects. Internal matrix concept. *Dent Clin North Am* 1992; 36: 439-457.
- Balla R, LoMonaco CJ, Skribner J, Lin LM. Histological study of furcation perforations treated with tricalcium phosphate, hydroxylapatite, amalgam, and life. *J Endod* 1991; 17: 234-238.
- Fuss Z, Trope M. Root perforations: Classification and treatment choices based on prognosis factors. *Endod Dent Traumatol* 1996; 12: 255-64.
- Walton 1997, *op cit*.
- Kaufman AY, Fuss Z, Keila S, Waxenberg S. Reliability of different electronic apex locator to detect root perforations *in vitro*. *Int Endod J* 1997; 30: 403-407.
- Gutmann JL, Lovdahl PE. Problems encountered in tooth isolation and access to the pulp chamber space. In: Gutmann JL, Dumsha TC, Lovdahl PE, Hovland EJ et al. *Problem solving in endodontics*. Missouri. Mosby, 1997: 47-67.
- Walton 1997, *op cit*.
- Kvinnslund I, Oswald RJ, Halse A, Gronningsaeter AG. A clinical and roentgenological study of 55 cases of root perforation. *Int Endod J* 1989; 22: 75-84.
- Rodríguez PA. *Endodoncia, consideraciones actuales; accidentes y complicaciones en endodoncia*. Ed. Amolca. 1ª edición, 2003; IX: 254-255.
- Sinai IH. Endodontic perforations: their prognosis and treatment. *J Am Dent Assoc* 1977; 95: 90-95.
- Farzaneh M, Abitbol S, Friedman S. Treatment outcome in endodontics: the Toronto study. Phases I and II: Orthograde retreatment. *J Endod* 2004; 30: 627-633.
- Lasala 1992, *op cit*.
- Seltzer S, Sinai I, August D. Periodontal effects of root perforations before and during endodontic procedures. *J Dent Res* 1970; 49: 332-339.
- Fuss 1996, *op cit*.
- Kvinnslund 1989, *op cit*.
- Pitt FTR, Torabinejad M. Use of MTA for repair of furcal perforations. *Oral Surg* 1995; 79: 756-62.

Mailing Address:

CD Tania Abigail Terrazas Ríos

15 de Mayo 114-5, Centro, Querétaro, Qro. 76000

E-mail: abiterrazas@hotmail.com