



Ridge augmentation with titanium mesh for implant rehabilitation using a stereolithographic model

Aumento de reborde con mallas de titanio para la rehabilitación con implantes utilizando un modelo estereolitográfico

Diana Angelica Soria Perez,* Carolina Higashida Guerrero[§]

ABSTRACT

Adequate amount of alveolar bone is critical for achieving functional prosthetic rehabilitation with adequate aesthetics and biomechanical support. Several techniques have been developed for osseous reconstruction in atrophic upper and lower jaws. Ridge augmentation is an accepted successful method used in dental practice to increase bone volume in sites chosen for dental implant placement. Titanium mesh have been used for reconstruction of small and large defects as a method of containing graft particles. **Case report:** A case of a patient with severe bilateral resorption in the posterior area of the mandible is presented. Based on the CT scan, a stereolithographic model was obtained; Ridge augmentation procedure was performed with placement of two pre-shaped titanium mesh and a combination of xenograft, allograft, autograft as well factors rich in plasma. After 3 and a half months, both mesh were removed. An approximately 3 mm gain in ridge width was obtained making it possible to place and rehabilitate implants. **Conclusion:** The use of titanium mesh is an excellent alternative to increase bone width in atrophic jaws, thus enabling the patient to receive dental implant treatment.

RESUMEN

Un adecuado hueso alveolar es crítico tanto para la estética, como para el soporte biomecánico de la prótesis dental. Se han desarrollado varias técnicas para la reconstrucción de defectos en mandíbula y maxilar atróficos. El aumento de reborde óseo es un método exitoso aceptado y empleado en la práctica dental para incrementar el volumen óseo en sitios elegidos para la colocación de implantes dentales. Las mallas de titanio han sido utilizadas para la reconstrucción de defectos óseos, como un sistema de contención de injertos particulados. Reporte de un caso: Se presenta un paciente con severa reabsorción en zona posterior bilateral mandibular. Basados en el estudio tomográfico se obtuvo un modelo estereolitográfico sobre el cual se preformaron las mallas de titanio para realizar el aumento de reborde combinando xenoinjerto, aloinjerto, autoinjerto y plasma rico en factores de crecimiento. Se retiran 3 meses y medio después obteniendo aproximadamente 3 mm de ganancia para la posterior colocación de implantes en la zona y rehabilitación de los mismos. Conclusión: Las mallas de titanio son una excelente alternativa para el aumento de reborde en mandíbulas o maxilares atróficos, brindando al paciente la posibilidad de colocación de implantes dentales.

Key words: Stereolithographic, titanium mesh, ridge augmentation, computerized tomography.

Palabras clave: Estereolitográfico, malla de titanio, aumento de reborde, tomografía computarizada.

INTRODUCTION

Tooth loss and removable prostheses use brings as a consequence bone resorption and remodeling which eventually produces atrophic alveolar ridges. This is due to lack of residual bone stimulation and transference of masticatory load to underlying bone surfaces. It brings as a result a reduction of vascular supply with consequent bone loss. This in turn elicits decrease of trabecular bone and bone density. There is a resulting thickness loss of approximately 25%, and a 4 mm height loss in bone volume in the first year.

Bone loss is also influenced by several additional events such as gender of patient, hormone count, bone metabolism as well as parafunctions. It might

also be mentioned that height loss in the lower jaw is twice as much as in the upper jaw.¹

Use of bone-integrated implants is a treatment alternative for tooth replacement in totally or partially edentulous patients.² In cases where bone mass is insufficient or of poor quality, predictability of treatment can be compromised. It is important to carefully

* Periodontics Professor, Graduate School, National School of Dentistry, National University of Mexico (UNAM).

§ Implantology and Periodontics professor, Graduate School, National School of Dentistry, National University of Mexico (UNAM).

select implant location. Locations must have sufficient spongy and cortical bone to ensure adequate primary stability. Deficient stability can elicit micro-movements during implant healing and therefore give rise to implant fibrous encapsulation.³

Preoperative analysis frequently shows presence of bone defects in the alveolar process. These defects can be the result of a variety of factors such as extraction trauma, teeth with advanced periodontal disease, root fractures or periapical lesions, to mention but a few.²

Radiological examination provides information on height and bone mass in areas where treatment is envisaged. This is a worthy adjuvant when selecting implants, since it provides an idea of dimensions, location orientation as well as amount of implants to be placed.³

Patients afflicted with medical and dental compromise will benefit from usage of sophisticated imaging technology which provides detailed information. Patients who present deficient bone amount or quality, or patients with high aesthetic expectations will benefit from more elaborate planning techniques. In these cases computerized axial tomography is the method of choice, since it allows for a 3 D visualization of upper and lower jaw bone morphology.^{4,5}

There is currently software which enables planning, helping to visualize and evaluate bone density.⁶ This allows to previously be acquainted with the anatomical areas requiring treatment, augmenting thus the possibility of increasing surgical field reliability, which in turn enables the clinician when dealing with complicated cases, to place parallel implants in specific locations.³

Use of appropriate software bone density visualization and evaluation. They also allow for virtual implant placement as well as 3D model manufacture corresponding to the processed surface. Using a computer and appropriate software, tomography transfers data to a device which directs an argon laser emission. This emission polymerizes photosensitive acrylic fluid, on a 2 mm series of layers, until a 3D resin model is obtained. This model is a replica of the patient and is called stereolithograph.^{6,7}

If after painstaking evaluation, bone characteristics are deemed inadequate, it will be necessary to resort to surgical methods. Surgical treatment is used to regenerate reabsorbed alveolar crests and to treat located ridge deformities. Thereby, sufficient bone mass is obtained enabling implant placement of the implant. This in turn will forecast long term success.^{3,8}

Bone ridge augmentation is a successful and predictable therapeutic option. It implies usage of differ-

ent materials and techniques to increase bone volume and morphology in places selected for dental implant placement.⁹ Donor sites can be extra-oral or intra-oral, as well as xenografts, allografts, and alloplastic bone grafts. Several techniques have been used to fixate the graft material to the receptor site. Among these we can count non resorbable membranes, fixation screws, dental implants or titanium mesh.¹⁰

Titanium mesh has been used for bone defect reconstruction as a particulate graft contention system in upper and lower jaws. Presence of pores in the jaws enables nutrition and metabolic exchange as well as bone graft stabilization. They preserve appropriate contour for the desired bone regeneration and provide mucosa support. This enables the patient to receive long term dental implants.¹¹⁻¹⁴

CASE PRESENTATION

46 year old female nurse, born in the state of Michoacan, Mexico. The patient reported irrelevant, non-pathological history. As personal pathological history, the patient informed backbone problems due to congenitally narrow canal (congenital spinal stenosis). The patient informed of having suffered rheumatic fever, treated during childhood. At 22 years of age, the patient presented duodenal ulcer, which was treated with omeprazole and antibiotics. The patient's family history revealed colon cancer and high blood pressure in her maternal grandmother, cardiac valve problems and cardiac arrhythmias in her mother. Surgical history disclosed the following: hysterectomy at 35 years of age, tonsillectomy and orthognathic surgery to correct prognathism. The patient informed she had received PRBC transfusion 11 years before. The patient was allergic to epinephrine, pseudoephedrine and dipyrone.

Motivation for present consultation was the patient's desire to attain acceptable aesthetics and to be able to eat properly.

The following diagnosis adjutants were obtained: clinical photographs (*Figures 1, 2, 3*), study models, orthopantomography (*Figure 4*) as well as computerized axial tomography (*Figures 5, 6*) and lower jaw stereolithograph (*Figure 7*).

PERIODONTAL DIAGNOSIS

Presence of gingivitis. Absence of teeth number 22, 36, 46 and 47. Before implant placement, the case required guided bone regeneration in lower molar areas of both sides. This must be conducted based on calibration (*Table I*).

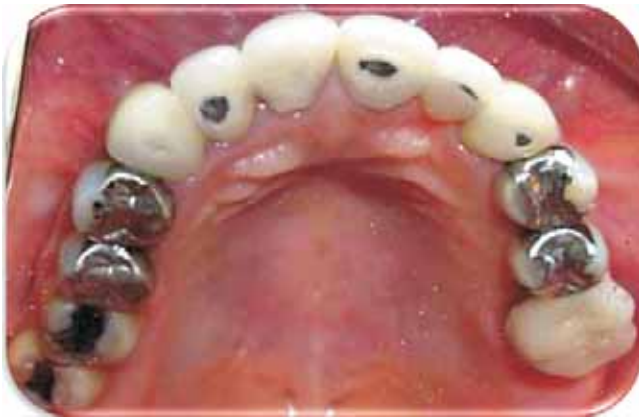

Figure 1. Upper occlusal intraoral view.

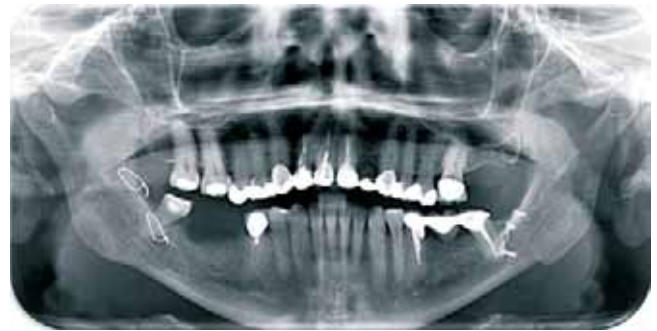

Figure 4. Initial orthopantomography.

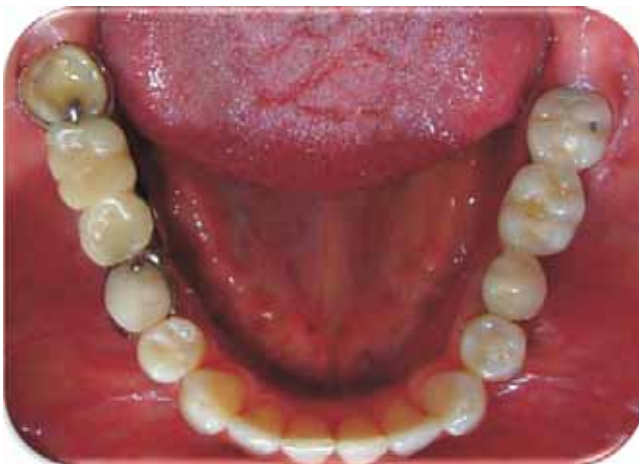

Figure 2. Lower occlusal intraoral view.

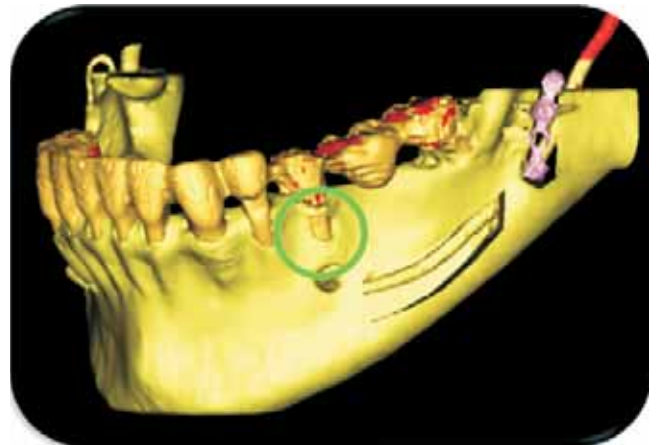


Figure 5. Computerized axial tomography of the lower jaw. Left lateral view.

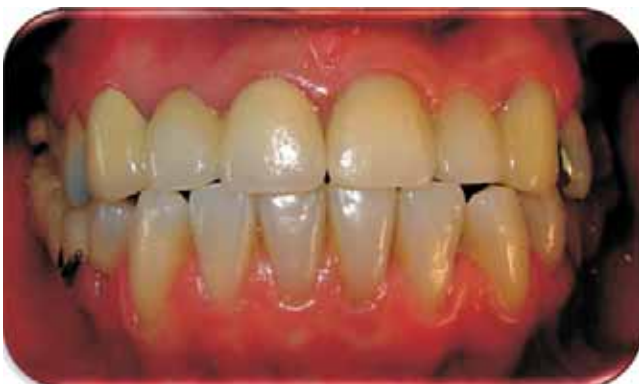

Figure 3. Front intraoral view.

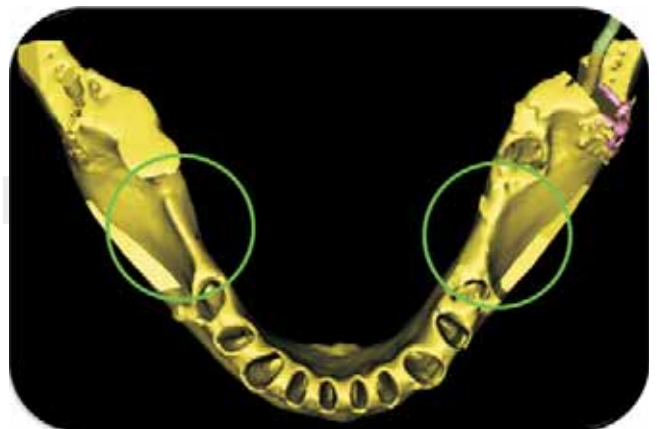


Figure 6. Computerized axial tomography of the lower jaw. Occlusal view.

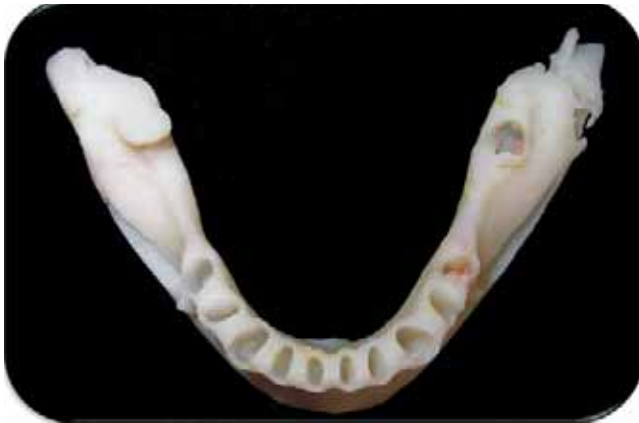

Figure 7. Lower jaw stereolithograph.

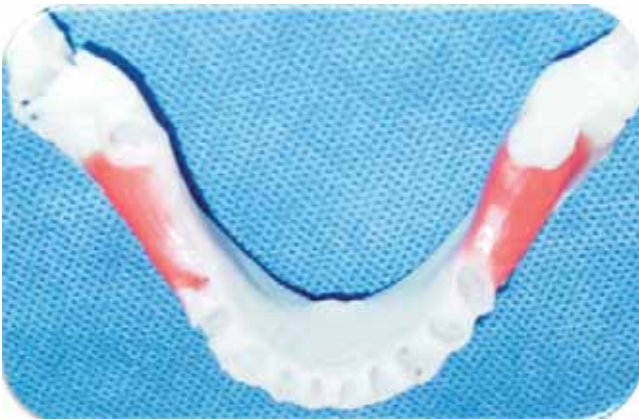

Figure 8. Waxing on stereolithograph model.

TREATMENT PLAN

1. Periodontal phase
2. Extraction of tooth # 35. Increase of alveolar ridge with titanium mesh. Combination of autograft, allograft, xenograft and plasma rich in growth factors in area of teeth # 35, 36, 37, 46 and 47.
3. Ridge increase in area of tooth 22, with block of xenograft, autograft, particulate allograft and plasma rich in growth factors.
4. Titanium mesh withdrawal four months after placement.
5. Implant placement in zones of teeth number 35, 36, 37, 46 and 47. Six months after ridge augmentation, placement of implant in area of tooth number 12 after extraction.

PROCEDURES

In December 2007, for ridge augmentation, surgery was performed with the use of titanium mesh. Upon

Table I. Lower jaw calibration.

Tooth	Superficial	Moderate	Deep
35	5	5	6
36	2	3	5
46	1	3	5
47	1	3	7

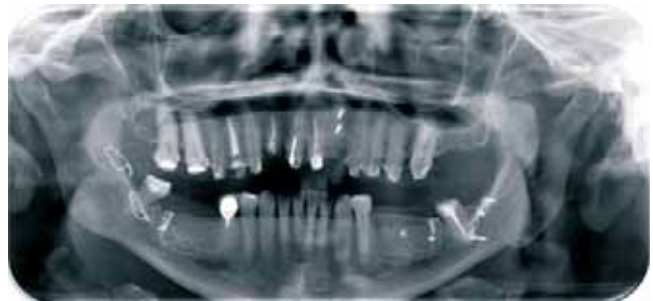

Figure 9. Orthopantomography taken after placement of titanium mesh and xenograft surgery.

the lower jaw, stereolithographic model ridge augmentation was simulated with wax (Figure 8). Following methodology described by Boyne¹⁴ titanium mesh was previously shaped to simplify surgical time. At the site of tooth 22, a pre-formed xenograft block was placed. (Nuk Bone, Biocriss) (Figure 9).

In April 2008, titanium mesh was removed from posterior mandibular positions. A gummy-like tissue was observed. The left, upper, lateral side was exposed, became contaminated, and presented suppuration at the site of the xenograft block; which in consequence had to be removed.

In May 2008 Biolok® brand implants were placed in areas of teeth 35, 36, 37, 46, 47. In all instances, implant diameter was 4 mm. A post extraction implant was placed in tooth number 12 area (Figure 10), where an atraumatic extraction was performed with periosteum, after which a xenograft was applied. In the area of tooth # 12, a connective tissue graft was placed in order to over-correct the defect and gain additional soft tissue. A sample of the regenerated bone was taken with the help of a trephine, in order to achieve histological study in the area of right lower molars (Figure 11).

In August 2008, a second-phase surgery was performed, using Alloderm® acellular dermal matrix to increase amounts of keratinized tissue in lower implant areas on both sides. In the area of tooth # 22, a ridge augmentation was performed with Alloderm® acellular dermal matrix, to prepare for an ovoid pontic.

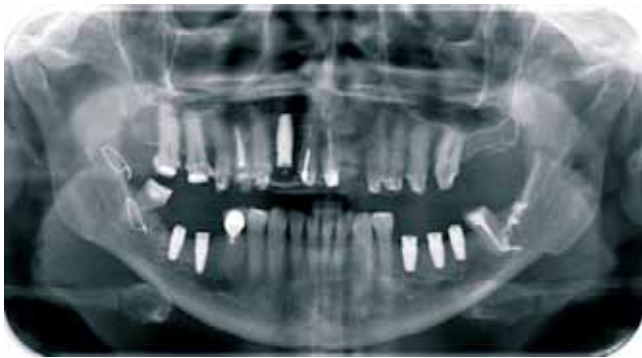

Figure 10. Orthopantomography taken after implant placement surgery.

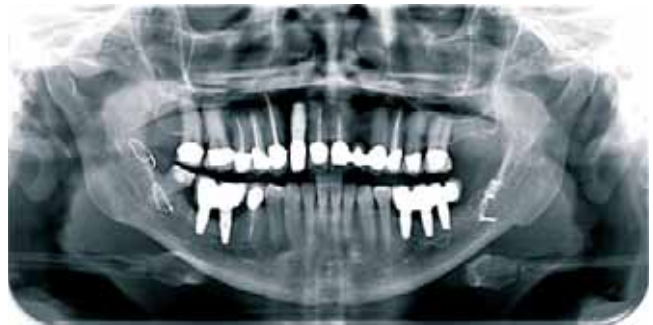

Figure 13. Postsurgical orthopantomography.



Figure 11. Sample harvested at the stage of implant placement.

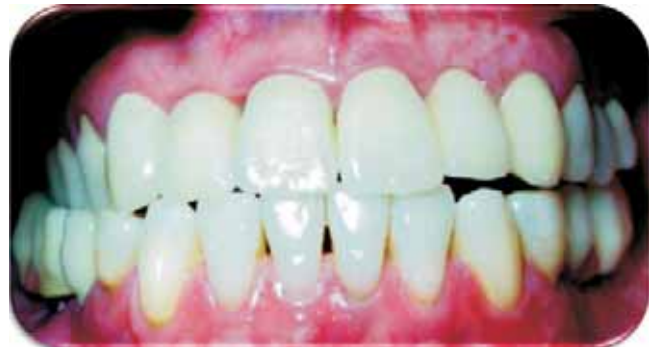

Figure 14. Rehabilitation prosthesis photograph: frontal view.

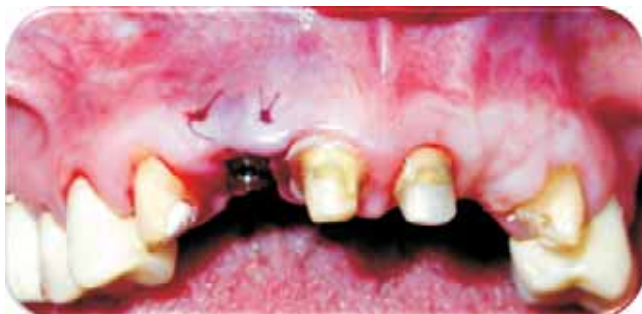

Figure 12. Clinical photograph taken at the stage of implant uncovering I tooth #12 area.

In December 2008 the implant placed in the area of tooth # 22 was uncovered (*Figure 12*).

RESULTS

A total of six implants were placed: 5 in the lower jaw, and 1 in the upper jaw (*Figure 13*). In this fashion, a prosthetic rehabilitation was completed

with partial fixed prosthesis on teeth as well as on implants (*Figure 14*). In all cases, implant rehabilitation was screwed into place: implant placed in #12 tooth area was performed in a unified fashion (*Figure 15*), whereas implants placed in the lower jaw, considering their length, were rehabilitated with a splint (*Figure 16*). At treatment completion, a pleasing extra oral view of the patient was achieved (*Figure 17*). The histological study of the sample taken at the moment of implant placement showed presence of vital laminar bone, basophilic areas of necrotic bone structures, dense and well vascularized fibrous connective tissue, adipose tissue and recent hemorrhage (*Figure 18*).

DISCUSSION

Based on the tomographic study, a stereolithographic model was obtained. On this model, titanium mesh was pre-formed following Boyne's technique, to achieve ridge augmentation. A combination of xenograft, allograft, autograft and plasma rich in growth

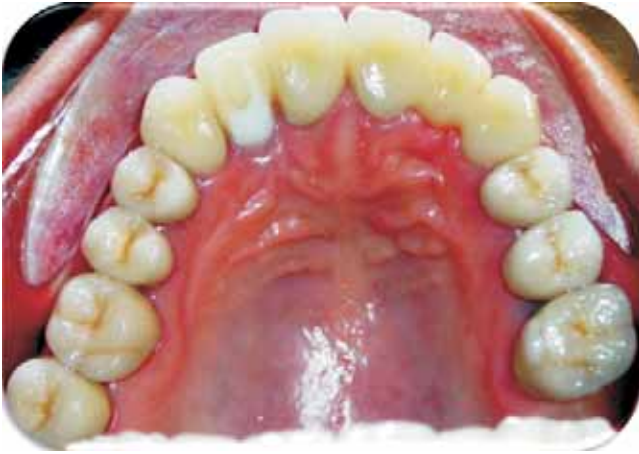

Figure 15. Upper occlusal clinical picture of rehabilitating prosthesis.

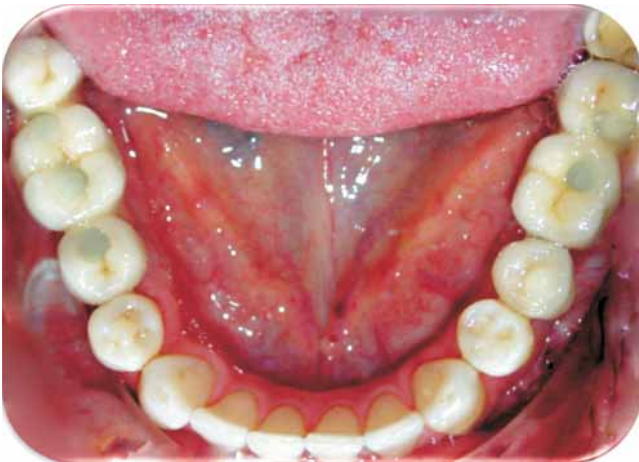

Figure 16. Lower occlusal clinical photograph of rehabilitating prosthesis.

factors was used.¹⁴ Due to the xenograft and allograft osteoconduction properties, a physical matrix was provided for new bone apposition. In this manner, bone volume was preserved during the remodeling process.¹⁶⁻¹⁸ Autografts stimulate osteogenesis around xenograft and allograft particles.^{9,18} Pieri mentions the existence of an osteoconductor scaffolding (xenograft) with intraoral autograft.¹⁵ Combination of the aforementioned grafts allows for the reduction of the autograft amount. It thus improves preservation of the graft for a longer time and decreased bone morbidity.^{12,19}

Six months later, implants were put into place; an excellent primary fixation was achieved. At this point, a bone sample was harvested to perform histological studies. In this sample the following could be ob-

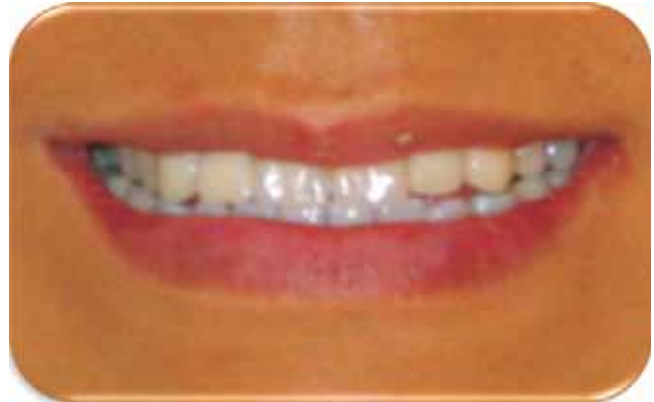

Figure 17. Extra-oral view.

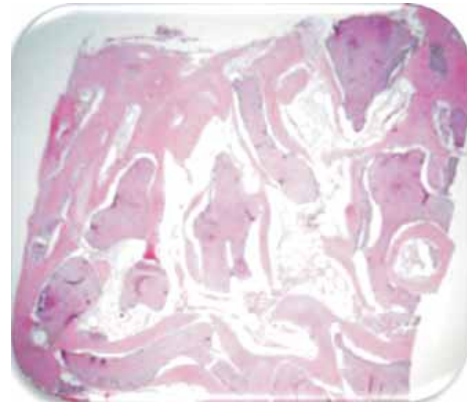

Fig 18. Histological slide of bone sample.

served: basophilic areas of necrotic bone structures, dense and fibrous well vascularized connective tissue. This could be compared with results reported by Artzi, who observed the following in all histological samples taken in cases of titanium mesh ridge augmentation cases: new bone formation, at different maturation and remodeling stages as well as grafted bone particles in direct contact with new bone and connective tissue.¹³

CONCLUSIONS

In our days, implant techniques offer many treatment options, with predictable results. These techniques solve retention, support and stability problems in partially edentulous patients showing great amounts of ridge resorption. This has contributed to the development of prosthetic rehabilitation field, since it provides high degrees of precision, function, comfort and aesthetics.

To attain successful results, it is of paramount importance to initially assess the patient to later meet with all the treatment plan goals.

Paramount for the planning of this case were the usage of computerized axial tomography, along with the mandibular stereolithographic model. These treatment adjuncts helped to determine critical anatomical characteristics as well as to simplify surgical time.

The use of titanium mesh allowed for the increase of atrophic ridges, and permitted the placement of 5 implants in the lower jaw, and one implant in the upper jaw. To culminate in a fixed prostheses (rehabilitation) supported by implants, thus recuperating the patients aesthetics and masticatory function.

Accurate diagnosis and comprehensive patient assessment performed by the whole team of specialists, allow implantology to increase oral health and aesthetics improvement. This in turn will enhance the patients quality of life due to the use of new, predictable and high quality techniques.

REFERENCES

- Misch CE. *Contemporary Implant Dentistry*. El Servier Mosby Third Edition 2008.
- Buser, Dula, Hess, Peter & Belser. Localized ridge augmentation with autografts and barrier membranes. *Periodontology* 2000; Vol. 19, 1999, 151-63.
- Jacobs R. Preoperative radiologic planning of implant surgery in compromised patients. *Periodontology* 2000, Vol. 33, 2003, 12-25.
- Almog, Heisler. Computer Intuition: Guiding Scientific Research in Imaging and Oral Implantology. *J Dent Res* 1997; 76 (10): 1684-1689.
- Di Giacomo, Cury, Soares de Araujo, Sendyk, Sendyk. Clinical Application of Stereolithographic Surgical Guides for Implant Placement: Preliminary Results. *J Periodontol* 2005; 76: 503-507.
- Sarment David P, Sukovic Pedrag, Clinthorne Neal. Accuracy of implant placement with a stereolithographic surgical guide. *Int J Oral Maxillofac Implants* 2003; 18: 571-577.
- Komori Takahide, Takato Tsuyoshi, Akawa Tetsuya. Use of a Laser – Harded Three – Dimensional Replica for Simulated Surgery. *J Oral Maxillofac Surg* 1994; 52: 516-521.
- Assenza Bartolomeo, Piattelli Maurizio, Scarano Antonio, Lezzi Giovanna, Petrone Giovanna, Piattelli Adriano. Localized Ridge Augmentation Using Titanium Micromesh. *Journal Of Oral Implantology* Vol. 2001; 27 (6): 287-292.
- Maestre-Ferrín, Boronat-López A, Peñarrocha-Diago M. Augmentation procedures for deficient edentulous ridges, using on-lay autologous grafts: An upate. *Med Oral Patol Cir Bucal* 2009; 14 (8): 402-7.
- Proussaefs Periklis, Lozada Jaime. Use of Titanium Mesh for Staged Localized Alveolar Ridge Augmentation: Clinical and Histologic - Histomorphometric Evaluation. *The Journal Of Oral Implantology* 2006; 32 (5): 237-247.
- Sumi Yasunori, Miyaishi Osamu, Tohnai Iwai, and Ueda Minoru. Alveolar ridge augmentation with titanium mesh and autogenous bone. *Oral Surg Oral Med Oral Pathol Oral Radiol Endod* 2000; 89: 268-70.
- Patrick Louis, Radjesh Gutta, Nasser Said - Naief, and Bartolucci. Reconstruction of the Maxilla and Mandible With Particulate Bone Graft and Titanium Mesh for Implant Placement. *J Oral Maxillofac Surg* 2008; 66: 235-245.
- Artzi Zvi, Dayan Dan, Alpern Yechiel, Nemcovsky Carlos E. Vertical Ridge Augmentation Using Xenogenic Material Supported by a Configured Titanium Mesh: Clinico histopathologic and Histometrical Study. *Int J Oral Maxillofac Implants* 2003; 18: 440-446.
- Boyne Philip. *Osseous Reconstruction of the Maxilla and Mandible, Surgical Techniques Using Titanium Mesh and Bone Mineral*. Quintessence Books; Chicago 1997.
- Pieri Francesco, Corinaldesi Giuseppe, Fini Milena, Nicoli Nicolo, Giardino Roberto and Marchetti Claudio. Alveolar Ridge Augmentation With Titanium Mesh and a Combination of Autogenous Bone and Anorganic Bovine Bone: a 2 Year Prospective Study. *J Periodontol* 2008; 79: 2093-2103.
- Corinaldesi Giuseppe, Pieri Francesco, Marchetti Claudio, Fini Mailena, Nicoli Aldini Nicolo, and Giardino Roberto. Histologic and histometric evaluation of alveolar ridge augmentation using bone grafts and titanium micromesh in humans. *J Periodontol* 2007; 78: 1477-1484.
- Maiorana Carlo, Santoro Franco, Rabagliati Marco, Salina Sergio. Evaluation Of the Use of Iliac Cancellous Bone and Anorganic Bovine Bone in the Reconstruction of the Atrophic Maxilla with Titanium Mesh: A Clinical and Histologic Investigation. *Int J Oral Maxillofac Implants* 2001; 16: 427-432.
- Garg Arun. *Bone Biology, Harvesting, and Grafting for Dental Implants, Rationale and Clinical Applications*. Quintessence Publishing Co. Chicago 2004, capítulos 1 y 2; p 3-56.
- Fouad Houry, Had Antoun, Patrick Missika. *Bone Augmentation in Oral Implantology*. Quintessence Publishing Co, London 2007: 268-70.

Mailing Address:
Carolina Higashida Guerrero
 E-mail: carohigashida@gmail.com