

# The Microabrasion Technique with Acrylic Bur. Case Report

## Técnica de microabrasión con fresa de acrílico. Caso clínico

Lourdes Feregrino-Vejar DDS<sup>1</sup>; Jaime Fabián Gutiérrez-Rojo DDS<sup>2</sup>; Rafael Rivas-Gutiérrez DDS<sup>2</sup>

1. Student of Orthodontics Specialty at Universidad Autónoma de Nayarit, México.
2. Professor of Orthodontics Specialty at Universidad Autónoma de Nayarit, México.

Correspondence to: Dra. Lourdes Feregrino-Vejar - lalur\_5@hotmail.com

Received: 9-VI-2016

Accepted: 26-X-2016

Published Online First: 1-XI-2016

DOI: <http://dx.doi.org/10.15517/ijds.v0i0.26805>

### ABSTRACT

**Introduction:** Some important factors for establishing social interactions seem to be the physical attractiveness and facial appearance, and dental color is one of the most important characteristics correlated with the aesthetics. The microabrasion is a conservative, atraumatic and non restorative technique that removes a superficial layer of enamel that has some defects of texture or color such as brown or white opacities. **Case description:** Case 1. A 35 year old female showed generalized TF grade 4 and 5 fluorosis. The enamel microabrasion consisted of 3 applications in the upper teeth and 2 more applications on the central incisors and on the right lateral teeth. Case 2. A 42 year old male presented TF grade 3 and 4 fluorosis. The enamel microabrasion consisted of four applications in the lower teeth and 2 applications on the upper teeth. **Discussion:** The success of enamel microabrasion depends on the location and depth of the enamel defect. Before treatment, patients should be informed that they may required a bonded composite restoration or a bleaching treatment, because the depth of the enamel discoloration is uncertain.

### KEYWORDS

Microabrasion; Fluorosis; Hydrochloric acid; Enamel; Esthetic; Acrylic bur.

## RESUMEN

Introducción: Algunos factores importantes para establecer la interacción social parece ser el atractivo físico y la apariencia, el color de los dientes es una de las características más importantes relacionadas con la estética. La microabrasión es una técnica conservadora, atraumática y no restauradora que remueve una capa superficial del esmalte que tiene algún defecto de textura o color como las opacidades blancas y cafés o marrón. Descripción del caso: Caso 1. Paciente femenina de 35 años de edad mostro grado 4 y 5 TF de fluorosis. La microabrasión del esmalte consistió en 3 aplicaciones en los dientes superiores y 2 aplicaciones más en los incisivos centrales y en el lateral derecho. Caso 2. Masculino de 42 años de edad presento grado 3 y 4 TF de fluorosis. La microabrasión del esmalte consistió en 4 aplicaciones de los dientes inferiores y 2 aplicaciones en los superiores. Discusión: El éxito de la microabrasión depende de la localización y profundidad del defecto en el esmalte. Antes del tratamiento, se debe informar a los pacientes que podrían requerir una restauración de composite o un blanqueamiento, ya que la profundidad del defecto del esmalte es incierto.

## PALABRAS CLAVE

Microabrasión; Fluorosis; Ácido clorhídrico; Esmalte; Estética; Fresa de acrílico.

## INTRODUCTION

Some important factors for establishing social interactions seem to be the physical attractiveness and facial appearance, for which the oral region is primary consideration, and dental color is one of the most important characteristics correlated with the aesthetics of dental arch (1-3).

Enamel defects are related to disturbances during enamel formation or may be the result from environmental factors or genetic abnormality. The treatment is going to depend on the severity, location, type and depth of the lesion, and this could be bleaching techniques, selective polish, microabrasion, composite resin, laminate veneer, porcelain crown or a combination of treatments (4-7).

The microabrasion is a conservative, atraumatic and non restorative technique that removes a superficial layer of enamel that has some defects of texture or color such as brown or white opacities. This technique which involves acid and abrasive products was first described by Dr.

Walter Kane in 1916, but it was Croll who named "microabrasion" in 1986 (8-10).

The defect on the enamel is removed for the abrasive and erosive effects of the acid and the abrasive agent in the mixture. There have been numerous reports describing different methods for the technique, Kane used hydrochloric acid at 36%, Raper 18% hydrochloric acid for 10 minutes, in 1970s was indicated the mechanical application with a low-rotation micromotor, using a mixture of 18% hydrochloric acid, hydrogen peroxide and ether. Murrin added pumice as an abrasive agent, and Kamp in 1989 proposed the use of 35% phosphoric acid. Espinoza used 18% hydrochloric acid with pumice, associated with a slow rotation system with an acrylic bur and named this technique as modified microabrasion (11-13).

The most common indication for microabrasion is dental fluorosis, which is caused by excessive fluoride exposures during tooth development, resulting in demineralization of enamel and produces opaque white areas or

discoloration that may range from yellow to dark brown, the porosity and depth of involvement are increased with severity (14,15).

Microabrasion is also indicated in alteration due to enamel hypoplasia, amelogenesis imperfecta, superficial non carious enamel defects, and white defects acquired after removal of orthodontic appliance, nevertheless white spot lesions can disappear in weeks for the mineral content of saliva, it is recommended to treat white spots with a topical fluoride regimen for 15 to 30 days for decreasing the size of the lesions, the white spots can improve after 3 months, for this reason microabrasion have to be delay until this time (10-11, 16-18).

Enamel microabrasion is contraindicated in dentinogenesis imperfecta or when the stains are located in the dentin such as tetracycline discoloration. This technique is not indicated on teeth that are not totally erupted, and on patients with deficient lip sealing, because the enamel surfaces are abnormally dry, those teeth are always exposed to air and dehydrate more easily (19, 20).

## MICROABRASION TECHNIQUE

First Patient and operator protection is placed with the respective protective barriers especially glasses. (Figure 1) Prior to treatment the mucosa is protected with vaseline or another gingival protector, while the affected teeth are isolated with rubber dam to avoid contact between the acidic material and other teeth as well as soft tissues of the mouth. Before applying the technique areas not covered by enamel such as exposed neck, carious lesions, coronary fractures, and others should be covered with glass ionomer (21,22).

Then the teeth need to be cleaned with pumice and water to remove extrinsic stain (Figure 2). 18% hydrochloric acid was mixed with pomex to form a slurry. The paste is applied to the buccal surface

of each teeth manually with a spatula (Figure 3), the acid is allowed to act for 1 minute to allow a small demineralization of the enamel layer, After that begins the lightly rubbed using a contra-angle handpiece in slow rotation with acrylic bur (Figure 4). Due to the tooth anatomy, different forms of the acrylic bur can be used, such as conical for interdental spaces. Then washed with sodium bicarbonate water to neutralize the acid for 30 seconds (Figure 5). The number of applications will depend of the severity of the enamel defect (22, 24,25).

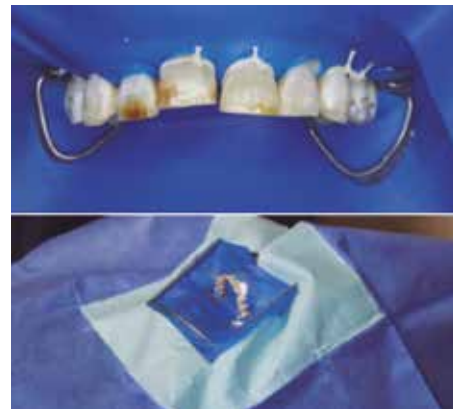

Figure 1.

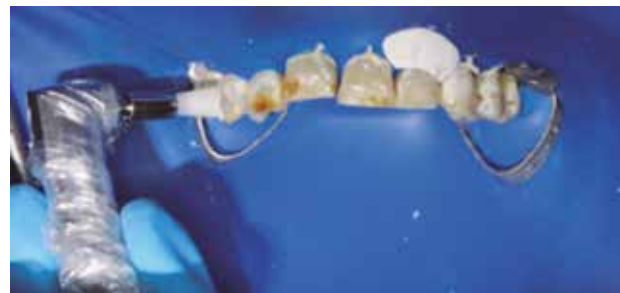

Figure 2.

At the end, the microabraded surface is polished with soflex discs from the roughest to the finest ones finishing with a rubber cup and polishing paste (Figure 6). Finally, neutral sodium fluoride gel is applied for 1 min to aid an immediate remineralization of the enamel. After this the isolation can be removed. The patients are instructed not to rinse for one hour, and they are not suppose to ingest any food-containing

coloring. Investigations comparing different acids used in microabrasion have concluded that no significant differences are observed between them (16,26).

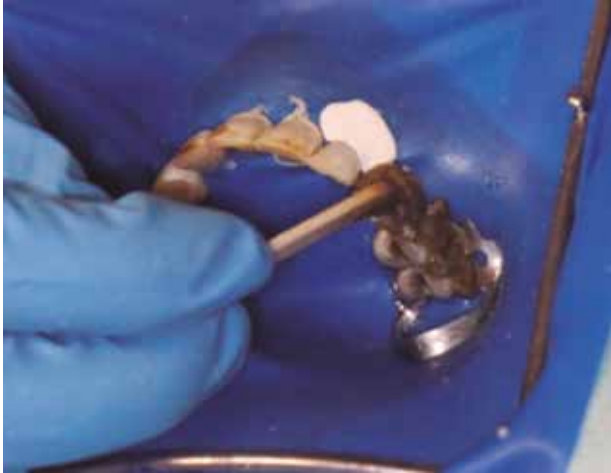


Figure 3.

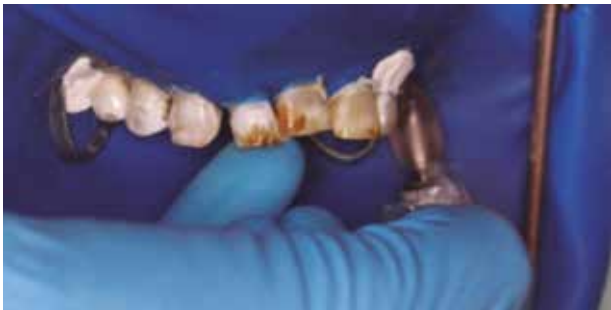

Figure 4.

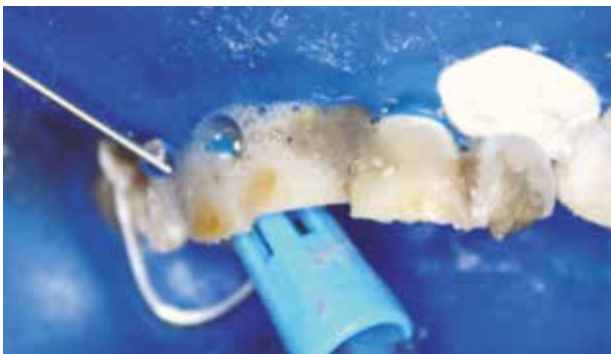

Figure 5.

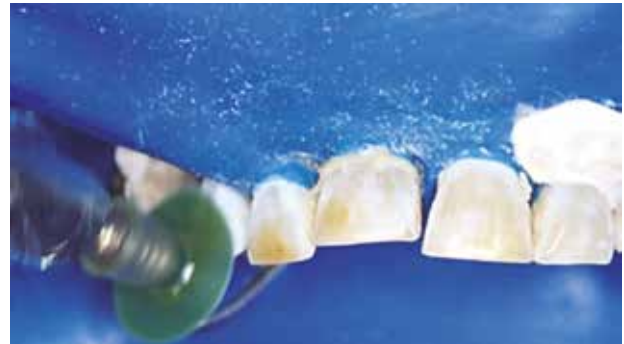

Figure 6.

## CASE DESCRIPTION

### CASE 1

A 35 year old female presented with a chief complaint of stained upper front teeth. An intraoral examination showed generalized TF grade 4 and 5 fluorosis. The enamel microabrasion consisted of 3 applications in the upper teeth and 2 more applications on the central incisors and on the right lateral teeth. Oral hygiene was good and no potting or cavitation was seen. The patient present sensitivity, but disappeared on the third day after treatment, and the patient went very satisfied. (Figure 7).

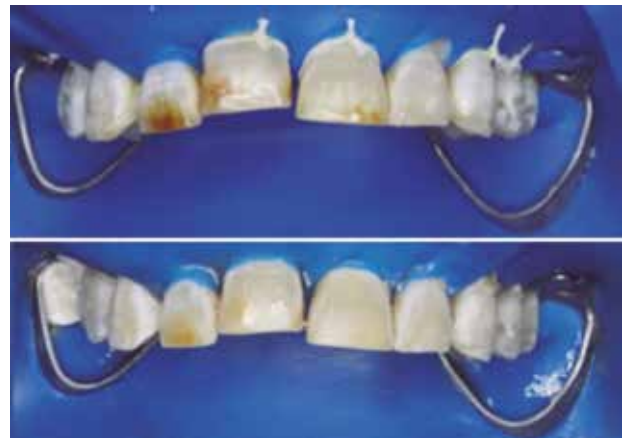
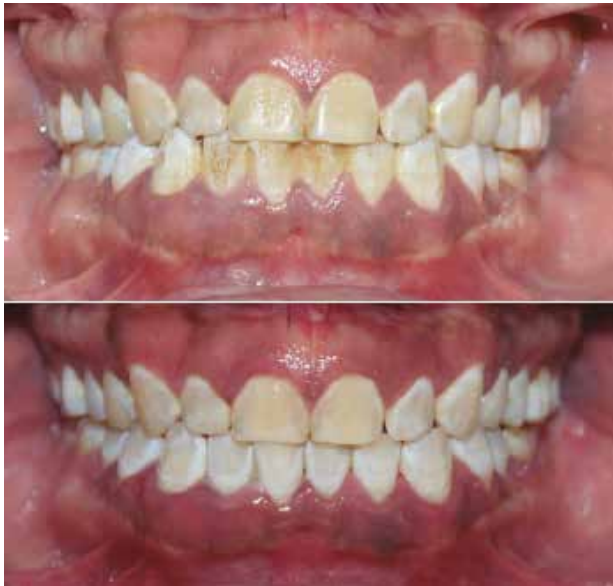
Figure 7.

## CASE 2

A 42 year old male presented with a chief complaint of stained upper and lower teeth. An intraoral examination showed generalized TF grade 3 and 4 fluorosis. The enamel microabrasion consisted of four applications in the lower teeth and 2 applications on the upper teeth. The patient did not present sensitivity and was satisfied with the result (Figure 8).



**Figure 7.**

## DISCUSSION

The success of enamel microabrasion depends on the location and depth of the enamel defect. Before treatment, patients should be informed that they may require a bonded composite restoration or a bleaching treatment, because the depth of the enamel discoloration is uncertain. A LED or halogen source on the palatal surface can be used to try to see how deep the white spot is in the enamel. If the spot shows its contour and darkness, it may be a deep white spot (11,19,20).

The loss of surface enamel depends on time, pressure and number of applications. The first application of hydrochloric acid pumice mixture removed 12  $\mu\text{m}$  and subsequent applications removed 26  $\mu\text{m}$ , this is associated with the fluoride rich enamel that is at the surface. A series of 10 applications will remove approximately 25% of the labial enamel (27-29).

Another laboratory study shown that the enamel loss is not clinically significant, varying from 45.5  $\mu\text{m}$  to more than 100  $\mu\text{m}$ , depending on the protocol used. Nevertheless removal more than 130  $\mu\text{m}$  may be clinically significant. Most studies in the literature used sound enamel to assess enamel wear during microabrasion. The abrasion combined with acid erosion of the enamel prisms results in the development of a densely compacted prism-free layer on the enamel surface (30,31).

Paschoal et al (32) suggested that if the distinct color improvement do not occur by the sixth application the microabrasion must be abandoned in order to avoid exposing more enamel.

Wong (33) mentioned that if the patient was unsatisfied with the appearance of the teeth, a second course of treatment was carried out, but after this, the remaining patients were treated with composite veneers.

It is possible that postoperative sensitivity may occur, due to an excessive enamel waste. However tooth sensitivity is transitory and stopped within a short period of time, that's because this treatment does not affect tooth vitality. Gingival irritation is another side effect that can be reported (34).

The microabrasion changes the optical characteristics of the enamel surface, and presents a lustrous, shiny and glass like surface, which may reflect and refract light differently. The mineralides

enamel layer created by microabrasive technique is less favorable for bacterial colonization, particularly by *Streptococcus mutans*, and also is more resistant to demineralization (11).

This technique produce enamel roughness, wich is reestablished by saliva over a period between 7 and 15 days. And there isn't any recurrence of the stains (8,35).

The fluorosed enamel surface challenges orthodontist even more tan bonding brackets to gold, amalgam and porcelain. Fluorosed enamel demonstrates an outer hypermineralized and acid-resistant layer that varies between 50-100 µm, resulting in a weaker adhesion of the resin and consequent poor retention of orthodontic brackets. The usual technique of etching (37% phosphoric acid for 15 seconds) is unable to penetrate the enamel surface with fluorosis (36,37).

## CONCLUSION

The enamel microabrasion is a conservative technique that can improve esthetics of stained teeth.

## REFERENCES

- Gavric A., Mirceta D., Jakobovic M., Pavlic A., Zrinski M. T., Spalj S. Craneodentofacial characteristics, dental esthetics-related quality of life, and self-esteem. *Am J. Orthod Dentofacial Orthop.* 2015; 147 (6): 711-18.
- Davis L. G., Ashworth P. D., Spriggs L. S. Psychological effects of aesthetic dental treatment. *Journal of Dentistry.* 1998; 26 (1998): 547-54.
- Dudea D., Lasserre J. F., Alb C., Culic B., Ciutrla I. S., Colosi H. Patients' perspective on dental aesthetics in a South-eastern European community. *Journal of Dentistry.* 2012; 40s (2012): e72-81.
- Vargas-Ferreira F., Salas M. M., Nascimento G. G., Tarquinio S. B., Faggion C. M., Peres M. A., et al. Association between developmental defects of enamel and dental caries: A systematic review and meta-analysis. *Journal of Dentistry.* 2015; 43 (2015): 619-28.
- Meenu M., Sharnpal S.. Clinical management of hypoplastic defects of enamel- a report of five cases. *JPFA.* 2009; 23; 155-59.
- Hanna L. M., Gomes R. J., Gomes L. C., Azevedo A. B., Nogueira A. J. Microabrasion of the enamel to soften the hypoplasia. *Ann Trop Med Public Health.* 2009; 2 (2): 53-56.
- Souza de Barros M. Q., Almeida K., Da Consolacao M., Almeidda T., Santos C., Bussadori S. K. Microabrasion: A treatment option for white spots. *The journal of Clinical Pediatric Dentistry.* 2014; 39 (1): 27-29.
- Pini N. I., Costa R., Bertoldo C. E., Aguiar F. H., Lovadino J. R., Lima D. N. Enamel morphology after microabrasion with experimental compounds. *Contemp Clin Dent* 2015; 6: 170-75.
- Pavesi N. I., Leite Débora, Sundfeld R., Bovi G. M., Baggio F. H., Lovadino J. R. In situ assessment of the saliva effect on enamel morphology after microabrasion technique. *Braz J. Oral Sci.* 2014; 13(3):187-192.
- Balan B., Uthaiyah C. M., Narayanan S., Monnappa P. M. Case Report Microabrasion: an effective method for improvement of esthetics in dentistry. *Hindawi publishing corporation [online].* 2013 [review on July/07/2015]; 2013: 1-4. Founded in: <http://dx.doi.org/10.1155/2013/951589>.
- Pavesi N. I., Sundfeld-Neto D., Baggio F. H., Sundfeld R. H., Marcondes L. R., Lovadino J. R., Leite D. Enamel microabrasion: An overview of clinical and scientific consideratios. *World J. Clin Cases.* 2015; 16 (3): 34-41.
- Noriega A. M., Muñoz R. Tratamiento estético conservador con microabrasión sobre hipoplasias del esmalte en dientes permanentes jóvenes. *Rev Tamé.* 2014; 3 (8): 271-74.

13. Velázquez J. E., Rivas R., Coyac R., Gutiérrez J. F. Microabrasión: alternativa para el tratamiento de fluorosis dental en ortodoncia. *Oral*. 2011; 12 (38): 739-41.
14. Abanto J. A., Rezende K. M. P. C., Marocho S. M. S., Alves F. B. T., Celiberti P., Ciamponi AL. Dental fluorosis: Exposure, prevention and management. *Med Oral Patol Oral Cir Bucal*. 2009 Feb 1;14 (2):E103-07.
15. Train T. E., McWhorter A. G., Seale N. S., Wilson C. F., Guo I. Y. Examination of esthetic improvement and surface alteration following microabrasion in fluorotic human incisors in vivo. *Pediatric Dentistry*. 1996; 18 (5): 353-56.
16. Murphy T. C., Willmot D. R. Rood H. D. Management of postorthodontic demineralized white lesions with microabrasion: A quantitative assessment. *Am J Orthod Dentofacia Orthop* 2007;131:27-33.
17. Willmot D. White spot lesions after orthodontic treatment. *Semin Orthod*. 2008; 14 (3): 209-19.
18. Donly K. J., Sasa I. S. Potencial remineralization of postorthodontic demineralized enamel and the use of enamel microabrasion and bleaching for esthetics. *Semin Orthod*. 2008; 14 (3): 220-25.
19. Sunfeld R. H., Sunfeld-Neto D., Machado L. S., Franco L. M., Fagundes T. C., Briso A. L. Microabrasion in tooth enamel discoloration defects: three cases with long-term follow-ups. *J Appl Oral Sci*. 2014; 22 (4): 347-54.
20. Sundfeld R. H., Croll T. P., Fraga A. L., Sversut R., Sunfeld D. Considerations about enamel microabrasion after 18 years. *Am J Dent*. 2007; 20 (2):67-72.
21. Silva K., Araújo C., Marques R., Correia D., Saeger S. Acceptability, efficacy and safety of two treatment protocols for dental fluorosis: A randomized clinical trial. *Journal of Dentistry*. 2014; 42 (2014): 938-44.
22. Croll T. P., Helpin M. Enamel Microabrasion: A new approach. *J. Esthet Dent*. 2000; 12: 64-71.
23. Rodríguez M. C., Mondelli R. F., Oliveira G. U., Franco E. B., Baseggio W., Wang L. Minimal alterations on the enamel surface by micro-abrasion: in vitro roughness and wear assessments. *J. Appl Oral Sci*. 2013; 21 (2):112-17.
24. Noriega A. M., Muñoz R. Tratamiento estético conservador con microabrasión sobre hipoplasias del esmalte en dientes permanentes jóvenes. *Rev Tamé*. 2014; 3 (8): 271-74.
25. Loguercio A. D., Correia L. D., Zago C., Tagliari D., Neumann E., Gomes O. M., et al. Clinical effectiveness of two microabrasion materials for the removal of enamel fluorosis stains. *Operative Dentistry*. 2007; 32 (6): 531-38.
26. Pavesi N. I., Leite D. A., Bovi G. M., Da Silva W. J., Baggio F. H., Lovadino J. R. Effects of acids in the microabrasion technique: microhardness and confocal microscopy analysis. *J. Clin Exp Dent*. 2015; 7 (4): e506-12.
27. Dalzell D. P., Howes R. I., Hubler P. M. Microabrasion: effect of time, number of applications, and pressure on enamel loss. *Pediatr Dent*. 1995; 17 (3): 207-11.
28. Paic M., Sener B., Schug J., Schmidlin P. R. Effects of microabrasion on substance loss, surface roughness, and colorimetric changes on enamel in vitro. *Quintessence International*. 2008; 39 (6): 517-22.
29. Waggoner W. F., Johnston W. M., Schumann S., Schikowski E. Microabrasion of human enamel in vitro using hydrochloric acid and pumice. *Pediatric Dentistry*. 1989; 11 (4): 319-23.
30. Lynch C. D., McConnell R. J. The use of microabrasion to remove discolored enamel: A clinical report. *J Prosthet Dent*. 2003; 90 (5): 417-19.

31. Müller K., Correa A. C., De-Paula C., Garcia R., Bello-Silva M. S., Lampert F., Esteves-Oliveira. Quantitative analysis of dental enamel removal during a microabrasion technique. *Clin Lab Res Den.* 2014; 20 (3): 181-89.
32. Paschoal M. A., Zuanon A. C., Santos-Pinto L. Limitations of enamel microabrasion technique applied in a pediatric patient: case report. *Rev Odontol UNESP.* 2011; 40(2): 103-07.
33. Wong F. S., Winter G. B. Effectiveness of microabrasion technique for improvement of dental aesthetics. *British Dental Journal.* 2002; 193 (3): 155-58.
34. Noble J., Karaiskos N. E., Wiltshire W. A. In vivo bonding of orthodontic brackets to fluorosed enamel using an adhesion promotor. *Angle Orthodontist.* 2008; 78 (2): 357-60.
35. Saeger S., Almeida D., Leida F. L., Saldivar J., Demarco F. F. Surface roughness and enamel loss with two microabrasion techniques. *The Journal of Contemporary Dental Practice* [online]. 2009 [reviewed in 17/01/2016]; 10 (1). Founded in: [http://www.jaypeejournals.com/eJournals/ShowText.aspx?ID=1946&Type=FREE&TYP=TOP&IN=\\_eJournals/images/JPLOGO.gif&IID=164&isPDF=YES](http://www.jaypeejournals.com/eJournals/ShowText.aspx?ID=1946&Type=FREE&TYP=TOP&IN=_eJournals/images/JPLOGO.gif&IID=164&isPDF=YES)
36. Zarur J. S., Zamarrita D. E., Méndez M. R. Estudio comparativo de dos técnicas de grabado en dientes con fluorosis. *Oral.* 2010. 11 (34): 589-93.
37. Wiltshire W. A., Noble J. Clinical and laboratory perspectives of improved orthodontic bonding to normal, hypoplastic, and fluorosed enamel. *Semin Orthod.* 2010 (1); 16: 55-65.



Attribution (BY-NC) - (BY) You must give appropriate credit, provide a link to the license, and indicate if changes were made. You may do so in any reasonable manner, but not in any way that suggest the licensor endorses you or your use. (NC) You may not use the material for commercial purposes.