

## CASE REPORT

DOI: <https://doi.org/10.15517/ijds.v0i0.34942>

Received:  
12-VI-2018

Accepted:  
16-X-2018

Published Online:  
22-X-2018

A Fiberglass and Resin Post Technique Combined with Fragment Collage of an Upper Central Incisor: Multidisciplinary Treatment

Unión de fragmento de un incisivo central superior con una técnica combinada: Tratamiento multidisciplinario

Juan Carlos Ramírez Barrantes DDS, MSD, PhD<sup>1</sup>

1. Clínica de Integral, Departamento de Ciencias Restaurativas. Facultad de Odontología, Universidad de Costa Rica, Costa Rica.

Correspondence to: Dr. Juan Carlos Ramírez Barrantes - [juancaramirezbarrantes@hotmail.com](mailto:juancaramirezbarrantes@hotmail.com)

**ABSTRACT:** The clinical treatment of anterior tooth fractures requires specialized knowledge, technical skill, and a degree of artistic sense to ensure successful treatment. Herein, we describe the reattachment of an original tooth fragment with endodontic involvement via the utilization of a micro-hybrid composite resin and an aesthetic fiberglass post.

**KEYWORDS:** Tooth reattachment; Bonding; Fiberglass post.

**RESUMEN:** El tratamiento clínico de las fracturas coronarias en dientes anteriores superiores requiere de conocimientos especializados, habilidades técnicas y un grado de sentido artístico para garantizar un exitoso tratamiento. En este reporte de caso, se describe la unión de un fragmento de un incisivo superior, que requirió previamente un tratamiento endodóntico, mediante la utilización de una resina compuesta micro-híbrida y un poste de fibra de vidrio.

**PALABRAS CLAVE:** Unión de fragmento; Adhesion dental; Poste de fibra de vidrio.

## INTRODUCTION

Anterior tooth fractures are among the most common types of trauma encountered in the maxillofacial region (1,2). Due to their exposed position in the dental arch, upper incisors are the teeth most commonly involved in dental trauma, and in most cases the trauma mainly affects the dental crown (2). The adequate restoration of fractured anterior teeth has always been a challenge for clinicians and specialists (3). The advent of the enamel acid etching technique and dentin (4) together with the adhesive and composite systems available today has broadened the possibilities with regard to the restorative treatment of fractured upper incisors (3). According to Baratieri *et al.* (5), the techniques of adhesive bonding of the dental fragment represent a milestone in the science and art of restoring fractured anterior teeth, because they enable the use of the tooth fragment itself.

Due to advances in adhesive dentistry, in cases of coronary artery fracture with endodontic involvement, composite resins can be used in the restoration of fractured anterior teeth, in conjunction with due consideration of intraradicular aesthetics (6,7). The aim of this report is to present a methodological alternative for bonding of the fragment in a tooth with incomplete rizogenesis, using a fibro-resinous post and a self-curing Duralay® resin guide.

## CASE REPORT

The patient was a 7-year-old boy who presented to the Dental Clinic of the Federal University of Santa Catarina with his parents, who reported the recurrence of a fracture in the right upper central incisor. Clinical examination revealed a transverse enamel/dentin fracture with periodontal inflammation, and the presence of a fistula in the vestibular region of the anterior teeth. Occlusion was favorable, and there was an absence of parafunctional habits. Radiographic

examination including periapical radiographs revealed the presence of a fistula associated with tooth 1.1 (Figure 1).

After clinical examination and diagnosis of the fracture type, a restorative treatment plan was formulated. Initially, appropriate oral health promotion and plaque control measures were implemented. Plaque activity was controlled via the patient's motivation with regard to oral hygiene and dietary measures, in conjunction with fluoride therapy.

Initial endodontic treatment was performed to promote disinfection of the root canal. Subsequently, a mineral trioxide aggregate (MTA) apical plug of 5-mm was completed (Figure 2). In the first session, the prophylaxis of all teeth with pumice and a rubber cup was performed. The internal walls of the root canal were evaluated in accordance with the treatment planning, and it was determined that they were unduly thin. Thus, a decision was made to place a reinforced intraradicular post (Figure 3).

The Luminex System fiberglass aesthetic post (Luscent Anchors™, Dentatus, MN, USA) was used in the current patient. This post is made from longitudinal glass fibers combined with a strong matrix of epoxy resin, resulting in refractive properties and the capacity for transmission of light through the root canal. Moreover, their elasticity is close to that of dentin, and they exhibit a high degree of resinous adhesion (10, 11). The Luminex System product includes a standard non-adherent plastic post to be used in the calibration of the canal, which may initially conform to the appropriate circumference of the selected final post.

Prior to beginning the procedure, the isolation of the tooth was performed with a rubber dam. After the elimination of the coronal sealing, a number 2 glass fiber post was selected. The post was positioned and tested regarding adaptation, and a considerable space was observed

in the circumference of the root canal (Figure 4). Establishment of the root canal diameter required for the fiberglass post was initiated using the standard plastic light transmitter post, and the adhesive protocol supplied with the Adper™ Scotchbond™ Multi Use Plus adhesive system (3M ESPE, MN, USA) was followed. The dentin on the inner walls of the root canal was conditioned with 35% phosphoric acid for 15s without reaching the coronary remnants, and rinsed for 30 s with a Luer syringe and low aspiration. During these procedures, excess moisture was removed with cones of absorbent paper.

The bonding agent was applied throughout the conditioned area with the aid of microbrushes, starting with the application of primer (2) and drying with a light air jet for 5s, then a drop of adhesive (3) and a drop of catalyst (3.5) . Any excess was immediately removed using endodontic paper cones. The root canal was immediately filled with Light Core 12 (Bisco, ILL, USA) translucent resin and the plastic light transmitter was positioned with the light tip placed on the incisal end, and photopolymerization was thus performed for 10 s with an XL 2500 apparatus (3M ESPE) calibrated at 600 mW/cm<sup>2</sup>.

After photopolymerization, the standard post was removed with pliers, an exact conformation for glass fiber post # 2 Luminex System - Luscent Anchors™ (Dentatus) was observed. Subsequently, the glass fiber post was siliconized with RelyXMR silane agent (Scotchprimer silane; 3M ESPE), and then cemented with RelyX™ ARC (3M ESPE). The polymerization of the resin cement was performed by applying the LED light for 40 s. All materials were used in accordance with the recommendations and working times suggested by the manufacturers (Figure 5). A periapical radiograph was taken after the completion of cementation of the post, including checking the adaptation and length within the root canal (Figure 6).

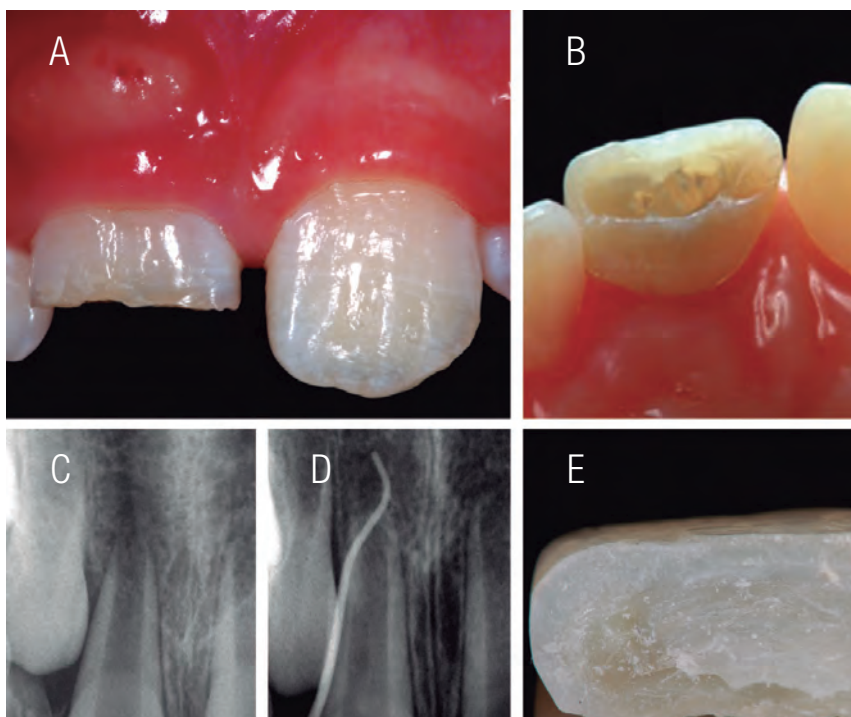
To check the fit, the dental fragment was positioned on the remaining tissue of the tooth with the aid of a sticky wax device. Without performing any adhesive procedure, an increment of composite resin was placed on the vestibular surface and photopolymerized, thus facilitating stabilization of the fragment in the exact position. Then, a splint was made using a Duralay acrylic resin, to simplify the fragment bonding procedure. The splint enabled the positioning of the fragment in the same place during the processes of insertion and photopolymerization of the micro-hybrid composite resin Filtek Supreme XT color A1 (3M ESPE). Acid conditioning of the dental remnant and the prepared fragment was performed with 35% phosphoric acid for 15s.

After removal of the acid with a water/air jet, the Adper™ Scotchbond™ Multi Purpose Plus adhesive system (3M ESPE) was utilized, using primer (2) and a drying time of 5s, then adhesive (3) followed by a light jet of air without photopolymerization. Notably, in the interior of the root canal the same adhesive system was applied to guarantee the same chemical polymerization. The treatment applied to the dental fragment after acid conditioning was similar to the protocol performed in the dental remnant. Cementation (bonding) of the fragment was performed with Filtek Supreme XT color A1 micro-hybrid composite resin (3M ESPE). With the purpose of filling the spaces in the cementation line between the dental remnant and the fragment after the elimination of excess, the Matrixx™ microparticle composite resin (Discus Dental, NV, USA) was used in increments of approximately 1 mm and photopolymerized for 40 s with the XL 2500 lamp (3M ESPE) calibrated at 600 mW/cm<sup>2</sup>. A masking agent or dye A1 was used to mask the fracture line (Figure 7).

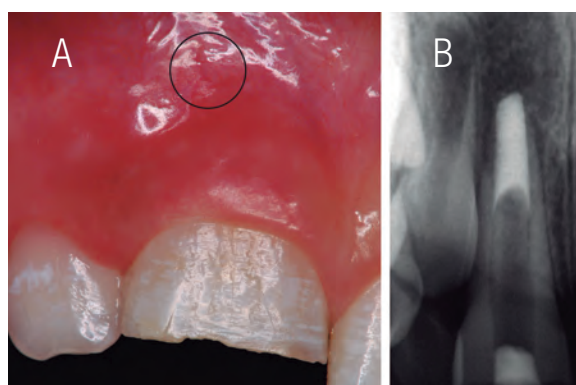
Occlusal adjustment was performed with Detecto carbon film. Final polishing of the composite resin was performed 48 hours after bonding the

fragment with silicone tips (Dentsply Sirona, Penn, USA) and Soft-Lex sandpaper disks (3M ESPE) mounted in low rotation. Final evaluation of the

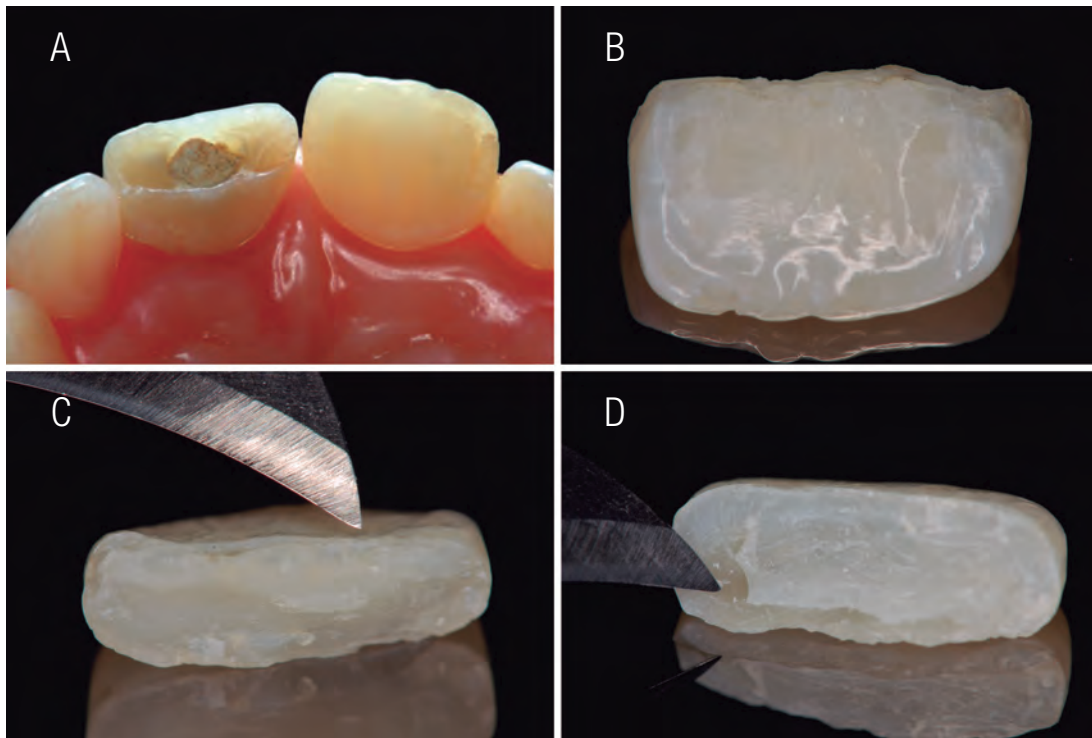
restoration was performed after 72 hours of treatment. The importance of confection and the use of the night splint was explained to the patient (Figure 8).



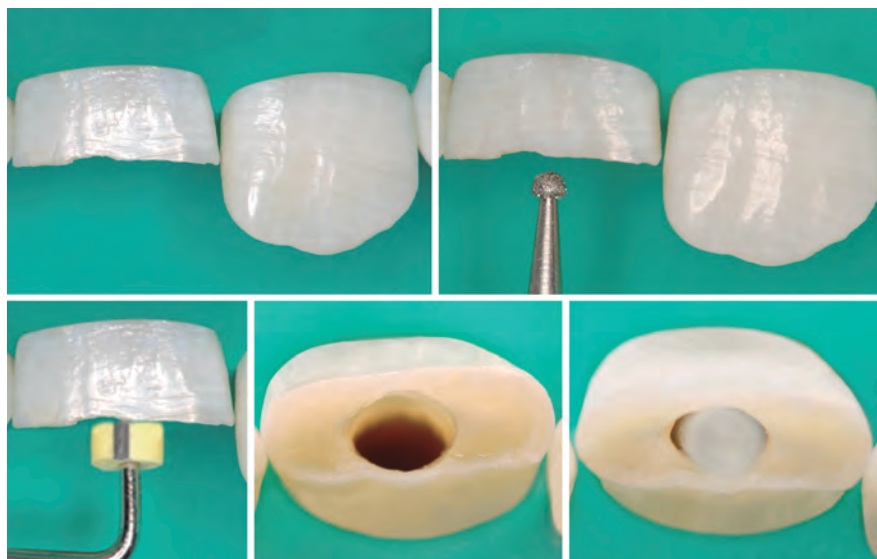
**Figure 1.** Clinical aspects of the right upper central incisor. Transverse fracture of enamel-dentin in the middle coronal third with the presence of a gingival fistula. The left upper central incisor exhibited enamel fracture at the disto-incisal angle, and gingival inflammation (A, B). After clinical and radiographic examination (C, D), fragment evaluation was performed. Note the excess of composite resin at the cavo-surface angle (E). At the time of the anamnesis the patient's mother reported that collage of the fragment had been performed countless times.



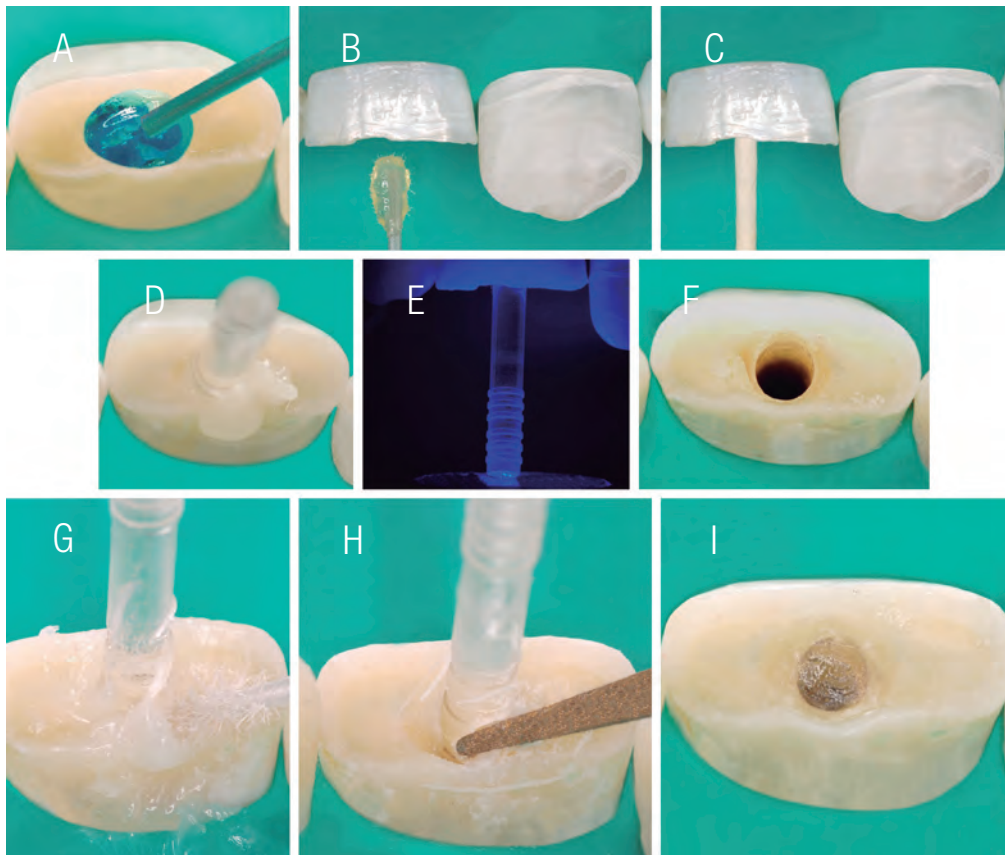
**Figure 2.** Endodontic treatment was performed and an apical plug was made with mineral trioxide aggregate. Note how the gingiva was repaired after the endodontic treatment (A). The patient was referred for placement of an intra-radicular post in order to strengthen the intra-radicular tooth structure. Note the endodontic treatment in the periapical radiograph of the central incisor, and the amplitude in the region of the root canal with fragility of the intra-radicular walls (B).



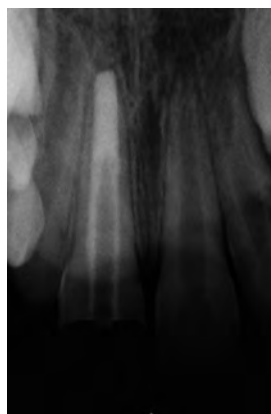**Figure 3.** Palatal view of the tooth revealing the prominence of the canal gauge with respect to the buccal and palatal surface (A). The dental fragment was hydrated. It was kept in water during and after endodontic treatment. Note the rich surface texture per palatal. The coarse excesses of composite resin in the inner part and in the bond line were removed with a scalpel blade to aid the exact adaptation of the fragment at the time of bonding (B, C, D).



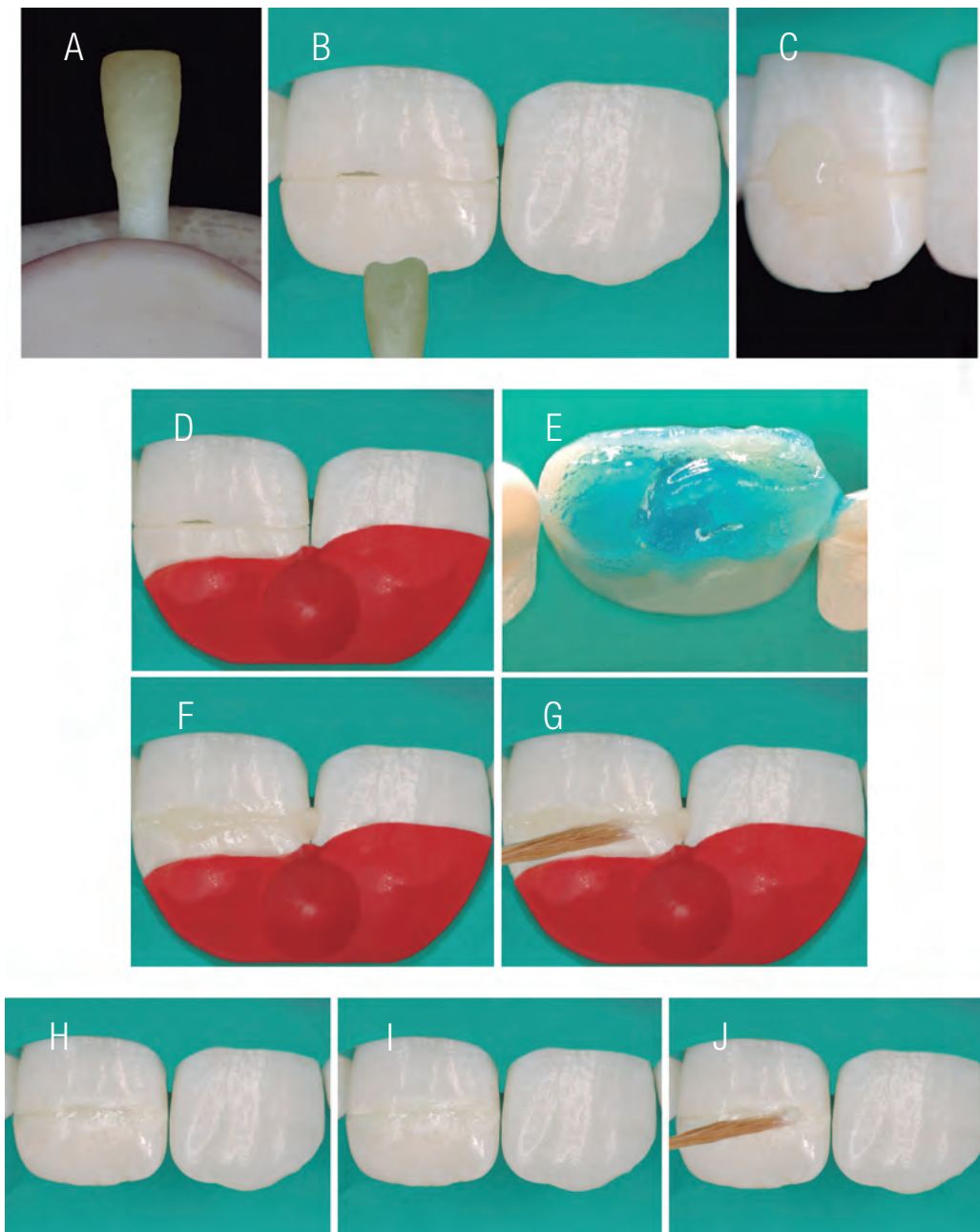
**Figure 4.** The sequence to stabilize the pin with regard to length and diameter.



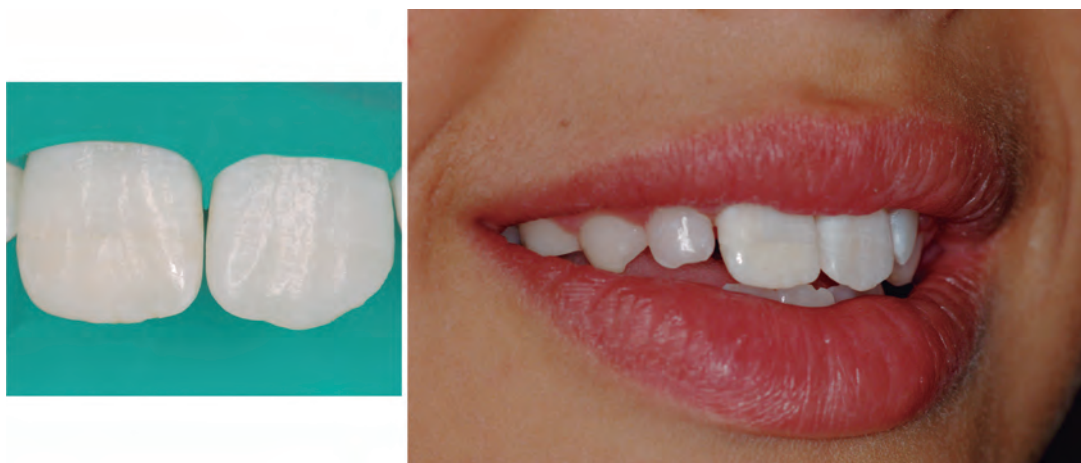**Figure 5.** Adhesive protocol procedures performed during the treatment (A, B, C). The standard post (Luminex System, Luscent Anchors™ Dentatus) was inserted together with the translucent Light Cor resin (D). The light tip positioned at the incisal end of the standard post, it transmits light by aiding the polymerization of the composite resin within the root canal (E). Note the conformation of the periphery of the root canal. After filling the root canal with double polymerized resin cement, the fiberglass post was inserted and cemented (G). After cementation, while being careful not to wear away any remaining tissue, the post was cut transversely at the canal entrance (H, I).



**Figure 6.** The radiograph shows the post in position and the adaptation of the composite resin to the dentinal walls.



**Figure 7.** Frontal and lateral views depicting fragment adaptation. To ensure adaptation of the fragment a composite resin of the same tooth color was used, which was polymerized without applying the adhesive system (A, B, C). Note that there was loss of tooth structure and there is a “window” in the region of the fracture line (D). Bonding was accomplished with the application of a three-step adhesive system (E) and the insertion of a small quantity of the composite resin (F). Use of the Duralay splint at the time of fragment bonding (F). Elimination of excess composite resin (G). The “window” and the fracture line were filled with micro-hybrid composite resin of the appropriate color (A1) with the help of microbrushes (H, I, J).



**Figure 8:** Final evaluation to check the fragment aesthetics. The bond line was practically imperceptible.

## DISCUSSION

Immature necrotic teeth with trauma history represents a challenge, both from endodontic and restorative perspective, due to the incomplete closure of the apex, and the thin and weakened dentinal walls which makes them susceptible to fracture (1,9). Dental crown fracture is the most common traumatic dental injury for permanent teeth (1).

Concerning restorations of traumatized anterior teeth, both esthetics and mechanical resistance to fracture are of great importance for good, long-lasting results (13). Thus, tooth fragment reattachment is a restorative alternative that consists in adhering tooth fragments to tooth remnants by conventional adhesives (5-6). This procedure is aesthetically more predictable for translucency, opalescence, fluorescence, characterization and surface texture (14).

This case report exemplifies a unique approach of conservative dentistry. As health professionals we must raise awareness in this type of scenarios. We are treating young people that would need a long-term treatment considering aesthetics, but also the biological perspective. An endodontic-restorative approach was essential for the success of this treatment. In order to increase

mechanical resistance, a glass fiber post was used. Moreover, the use of light-transmitting plastic posts in combination with adhesive materials enables intraradicular reinforcement of weakened canals to maintain a functional unit within the dental arch (1,12). Reinforced intra-radicular posts have the main function of assisting in the retention of restorative material and distributing the stress forces, particularly on the anterior teeth which receive oblique, horizontal, and shear forces more frequently, dissipating them along the crown and remaining root, preventing the occurrence of fractures (9). The approach used in this case report must serve as a guide to maintain and treat this type of trauma in a conservative manner. The bonding with composite materials of a reinforced fiber post to root canal should improve the prognosis of the post-core restored tooth by increasing post retention (14) and by reinforcing the tooth structure. This article represent a simple and efficient clinical protocol for the conservative treatment of fractured anterior teeth.


## CONCLUSION

It is possible to achieve aesthetic and functional results in fractured teeth with an open apex using the above-described innovative alternative approach, which addresses aesthetics and function, and incorporates root reinforcement.



## REFERENCES

1. Andreasen J. O. Etiology and pathogenesis of traumatic dental injuries. *Scand J Dent Res* 1970; 78: 329-42.
2. Andreasen J. O., Andreasen FM, Andersson L. Textbook and color atlas of traumatic injuries to the teeth, 4th edn. Oxford: Blackwell Munksgaard; 2007.
3. Maia E. A. V., Baratieri L. N., Andrada M. A. C., et al. Tooth fragment reattachment: fundamentals of technique and two case reports. *Quintessence Int* 2003; 34: 99-107.
4. Buonocore M. G., Quigley J. Bonding of synthetic resin material to human dentin: Preliminary histological study of the bond area. *J Am Dent Assoc* 1958; 56: 807-815.
5. Baratieri L. N., Monteiro S Jr., Andrada M. A. C. Tooth fracture reattachment: Case reports. *Quintessence Int* 1990; 21: 261-270.
6. Santiago, S. L. et al. Restauração de dente anterior fraturado com resina composta: relato de caso clínico. *J Bras Clin Odontol Int* 2000; 22: 12-5.
7. Souza, F. H. C. et al. Reconstrução coronária com resina composta e pino estético intracanal. *J Clin Dent* 2002; 15: 52-7.
8. Torabinejad, M.; Chivian N. Clinical applications of mineral trioxide aggregate. *J Endod* 1999; 25: 197-205.
9. Ferrari M. Fiber posts and endodontically treated teeth: A compendium of scientific and clinical perspectives, 1st edn. South Africa: Modern Dentistry Media; 2008.
10. Mitsui, F. H. O. et al. In vitro study of fracture resistance of bovine roots using different intraradicular post systems. *Quintessence Int* 2004; 35: 612-626.
11. Van Meerbeek B., et al. Buonocore memorial lecture. Adhesion to enamel and dentin: current status and future challenges. *Oper Dent*. 2003; 28: 215-235.
12. Teixeira C. et al. Interfacial evaluation of experimentally weakened roots restored with adhesive materials and fibre posts: An SEM analysis. *J Dent* 2008; 36: 672-682.
13. Vitale M. C., Caprioglio C., Martignone A., Marchesi U., Botticelli A. R. Combined technique with polyethylene fibers and composite resins in restoration of traumatized anterior teeth. *Dent Traumatol* 2004; 20: 172-7.
14. Terry D. A. Adhesive reattachment of a tooth fragment: The biological restoration. *Pract Proced Aesthet Dent* 2003; 15: 403-9.



Attribution (BY-NC) - (BY) You must give appropriate credit, provide a link to the license, and indicate if changes were made. You may do so in any reasonable manner, but not in any way that suggest the licensor endorses you or your use. (NC) You may not use the material for commercial purposes.