

Received:
1-II-2021

Persistent Idiopathic Dentoalveolar Pain. Literature Review and Clinical Case Treated with Intraoral Application of Botulinum Toxin

Accepted:
11-II-2021

Published Online:
5-III-2021

Dolor Idiopático Dentoalveolar Persistente (DIDAP). Revisión de literatura y caso clínico tratado con aplicación intraoral de toxina Botulínica

Andrés R. Cervantes-Chavarría DDS, MS¹

1. Máster en Ciencias Orales University of Minnesota, USA. Especialista en Dolor orofacial y DTM, University of Minnesota, USA. Especialista en Odontología General Avanzada UCR-SEP, Caja Costarricense del Seguro Social-UCR. Odontólogo Asistente, Departamento Cirugía Maxilofacial, Hospital San Juan de Dios, CCSS. Docente del Departamento de Ciencias Diagnósticas y Quirúrgicas. Facultad de Odontología. Universidad de Costa Rica, Costa Rica.
<https://orcid.org/0000-0001-6756-8029>

Autor para correspondencia: Dr. Andrés R. Cervantes-Chavarría - andres.cervantes@ucr.ac.cr

ABSTRACT: Persistent Idiopathic Dentoalveolar Pain (PIDAP) is an orofacial neuropathic pain, which can be difficult to diagnose and is usually accompanied by increasing anxiety from both the patient and the treating dentist. A case of a 38-year-old female patient is presented, and it is shown the diagnostic process and therapeutic approach. The interdisciplinary management accompanied by several pharmacological lines is highlighted: Botulinum toxin was used as an adjunctive treatment allowing it to decrease systemically administered medications dosing and therefore its possible side effects. This condition usually affects psychosocial aspects of the patient and has a major impact on his quality of life. It is very important before initiating an invasive clinical treatment, obtaining a clear differential diagnosis and assessing in some cases the presence of non-odontogenic pain, such as PIDAP.

KEYWORDS: Persistent dento-alveolar pain disorder; PDAP; Intraoral neuropathic pain; Intraoral botulinum toxin.

RESUMEN: El Dolor Idiopático Dentoalveolar Persistente (DIDAP), es un dolor neuropático orofacial, que puede resultar difícil de diagnosticar y generalmente se acompaña de creciente angustia tanto de parte del paciente como también del odontólogo tratante. Se presenta un caso de una paciente femenina de 38 años en donde se demuestra el proceso diagnóstico y abordaje terapéutico. Se resalta el manejo interdisciplinario

acompañado de varias líneas farmacológicas: la toxina Botulínica se utilizó como tratamiento coadyuvante para disminuir la dosis de medicamentos administrados por vía sistémica y por ende sus posibles efectos secundarios. Esta condición habitualmente abarca aspectos psicosociales del paciente y tiende a verse sumamente afectada su calidad de vida. Es de suma relevancia antes de iniciar un tratamiento clínico invasivo, obtener un diagnóstico diferencial claro y valorar en algunos casos la presencia de dolor no ontogénico, como el DIDAP.

PALABRAS CLAVE: Desorden de dolor dentoalveolar persistente; PDAP; Dolor neuropático intraoral; Toxina botulínica intraoral.

INTRODUCTION

Throughout the years the dental profession have faced the challenge of treating a type of persistent pain with no apparent cause in the dentoalveolar region; by other means non dental, dental pain (1,2). Clinical cases in which this happens would usually receive multiple endodontic treatments, exploratory surgeries, crowns, retreats, apicoectomies, extractions, without achieving pain relief. This condition has been known by many different terms such as: phantom tooth pain, atypical odontalgia, persistent dentoalveolar pain disorder, among others (3,4). This lack of consensus on terminology derives from the absence of standardized diagnostic criteria.

In 2012, Nixdorf *et al.* proposed the term Persistent Dentoalveolar Pain Disorder (PDAP)(4). With the goal of facilitating a better understanding of the condition, they conducted a dentistry-based analysis, proposing the term PDAP as a result. From this research, a diagnostic criterion was derived in which the anatomical region, the presence of pain, the subjective report of the patient and the clinical findings were considered. All this led to defining the following: "Persistent pain, localized in the dentoalveolar region, without clinical/radiographic evidence of being caused by any other disease or disorder; which can be primary (without an identified causal event) or secondary (if it is related to infection/trauma or any other dental procedure) (4,5)

Following these efforts, in 2020 was brought to light the International Classification of Orofacial Pain (ICOP 2020) in which diagnostic criteria consensus for Persistent Idiopathic Dentoalveolar Pain (PIDAP) is included as follows "Persistent unilateral intraoral dentoalveolar pain, rarely occurring in multiple sites, with variable features but recurring daily for more than 2 hours per day for more than 3 months, in the absence of any preceding causative event" (6).

The clinical description by the sufferer is commonly described as pain that is constant, located in the dentoalveolar region, is related in most cases to a tooth, which could be linked to a previous invasive dental procedure such as endodontic treatment, surgery oral or a simple dental extraction (7,8). The annoying sensation is described by the patient as a pressure / dull type, sometimes burning, usually aggravated by chewing or touching the area (9,10).

The acceptance and conceptualization for someone suffering from idiopathic persistent dentoalveolar pain is highly complex. Currently research has focused on how difficult it is for the patient to understand that pain perceived as coming from a tooth cannot be alleviated with regular dental procedures, in fact, that these can make the problem worse (9,11,12).

From a biopsychosocial perspective, it has been documented that this type of chronic orofacial

pain has a strong impact on the quality of life of those who suffer it (13). Therefore, it should also be considered that when an individual is affected by a condition like this, it will be influenced by multiple factors such as: co-morbidities (anxiety, depression, etc.), other chronic pain conditions (fibromyalgia, chronic back pain, etc.), educational level, family support and the clinical approach and treatment for pain received by the patient in the past (14).

Regarding its incidence, the presence of persistent dentoalveolar pain, after endodontic treatments, is estimated between 2.5% and 3.1% (15,16). More recently, in a study conducted at the National Network of Dental Practice in the United States, in a sample of 354 patients who received endodontic treatments, 19 patients presented persistent pain of different types (dental, neuropathic or temporomandibular), after 6 months of finished treatment. This number should be considered, since only in that country at least 20 million endodontic treatments are performed each year (15,16).

ETIOLOGY

Previously it was believed that this condition had a psychogenic origin, it was more considered a somatomorphic disorder. This confusion existed, because the emotional damage that this condition can cause in the patient who suffers from it is serious, adding, in addition, the anguish and anxiety that arise when the affected person insists on a dental problem without obtaining a response from the alternatives traditional" (17,18).

Multiple theories exist about its etiology some classified it as primary(idiopathic), if there is no possible causal event; or secondary, if it is closely related to a causal event such as an infection, dental procedure or facial trauma (4). When the condition is classified as secondary, one of the hypotheses raises the deafferentation

of primary afferent fibers of the trigeminal nerve, due to trauma, as in the case of extraction or endodontic treatment, where the analogy is made to the phantom limb or phantom pain, as reported after receiving a limb amputation (19,20). The mechanisms responsible for central sensitization and response amplification are considered to be involved in the pathophysiology of IPDAP (21,22) (21,22).

What is very clear about this condition is its nature as neuropathic pain, which is characterized by partial or complete somatosensory changes in the area innervated by a specific part of the peripheral or central nervous system that is then perceived as pain or pain. hypersensitivity by the affected subject (23,24). It is important to note that odontogenic pain usually resolves after dental treatments such as restorative treatment, endodontic therapy or surgical endodontic treatment. On the other hand, non-odontogenic pain will not disappear after these interventions and, furthermore, the diagnostic tests that are conventionally used for odontogenic conditions can cause confusion in the clinician and lead him to obtain inconclusive answers (25,26).

Its is subclassified in the international classification of orofacial pain as: with and without somatosensory changes: Somatosensory changes are present on qualitative/quantitative Negative (e.g. hypaesthesia and/or hypalgesia) and/or positive (e.g. hyperalgesia and/or allodynia) sensory symptoms and/or signs are present, but not spatially confined to a neuroanatomically relevant area, in contrast to post-traumatic trigeminal neuropathy (6).

This condition is more frequent on females and around their forties. In addition, inside the context of this condition its described a path of 7 years on average before getting an adequate diagnosis along with multiple dental treatments and different evaluations (14).

TREATMENT

Management of chronic pain ideally involves multidisciplinary approach which means interaction of pain specialists, health psychologists, physiotherapists, neurologists and psychiatrists in the most severe cases. Several strategies have been used in order to obtain adequate pain management: First-line medications for trigeminal neuropathic pain used in this condition are the classic tricyclic antidepressants such as amitriptyline or nortriptyline in doses of 20mg to 150mg per day. These drugs have been approved by the FDA for the treatment of neuropathies related to temporomandibular disorders (27).

Peripheral pain modulators such as pregabalin and gabapentin have been shown to be effective for other types of neuropathic pain and when used provide relief in some PDAP patients(12,28,29). Moreover, recent studies recommend serotonin and norepinephrine reuptake inhibitors (SNRIs) such as duloxetine, venlafaxine or milnacipran, as they have shown promising results in various studies in the treatment of neuropathic pain (30-32).

Botulinum toxin has begun to be used experimentally for orofacial neuropathic pain, showing promising results especially for trigeminal neuralgia after intraoral application. This drug acts by de-sensitizing the motor endplate by inhibiting the release of acetylcholine, and it is also believed to reduce glutamate concentrations antidromically. Recent studies have reported an acceptable decrease in pain after intraoral application of botulinum neurotoxin-A in patients with PDAP, reducing the side effects associated with systemic therapy (33-35).

Other strategies are application local anesthetics in the area such as gel or using stents aiming to improve the quality of life of these patients. Alternative medicines and therapies should be considered and recommended, especially if the

patient believes or experiences any relief from them. Finally, the clinician must remember that controlling emotional comorbidities (such symptoms of depression and anxiety), psychiatric comorbidities or any other comorbid chronic pain condition such as fibromyalgia or temporomandibular disorders will be a key component for adequate treatment (13,36-38).

CASE REPORT

38-year-old married female, medical doctor with a radiology specialty, presented to Orofacial Pain evaluation in with the chief complaint of chronic dental pain. Her medical history, and her family medical history are non-contributors to her orofacial pain condition. She denies smoking or drug use. She rates her main stressors as her job and her dental pain. She denied sleep problems or excessive caffeine consumption. The patient gave her consent for the publication of the case for academic or research purposes.

HISTORY OF THE CHIEF COMPLAINT

The patient reported that her symptoms began four years ago and worsened in the last 2 years. Triggering factors was thought by the patient as related to interproximal reductions that were made during orthodontic treatment. She locates the discomfort in the buccal papilla between teeth #24 and #25 extending to the entire quadrant. The pain was described as dull / burning and constant feeling of "having an open wound" with an intensity of 6 on a scale of 0-10. The identified aggravating factors: chewing, eating very cold food, coughing and emotional stress. She was relieved in the past with medications: Gabapentin 1800mg and nortriptyline 20mg, however the side effects were not tolerated by the patient (drowsiness, sleepiness, GI issues). Other drugs such as oxcarbazepine 900mg had no effect on pain. The patient denied oral parafunctional habits or episodes of jaw locking. Previous treatments include multiple

evaluations performed by the following dental specialists: periodontist, prosthodontist, endodontist, and orofacial pain specialist. In addition to medical specialists: otorhinolaryngology and neurology. All of them agreeing that there were no anatomical abnormalities or pathology that explains the pain. Also, she had two occlusal splints and occlusal adjustments both had no impact on her pain.

The patient underwent an MRI of the brain, a CT scan of the maxillary structures, and a CBCT, all of the above were interpreted by certified radiologists, and no alteration was shown.

CLINICAL EXAM

The patient did not present facial symmetry or lymphadenopathy detected during the inspection of the head and neck. Maximum mandibular opening was 40mm and excursion movements were within normal limits and without pain. Click noises were observed in the left TMJ. Extraoral and intraoral palpation of the masticatory muscles, cervical muscles and TMJs did not cause pain. Intraoral palpation and mechanical stimulation in the buccal area of teeth #24 and #25 showed hypersensitivity to touch. Dental examination revealed complete dentition without any obvious dental or periodontal pathology. Evaluation of the cranial nerves revealed no abnormalities.

Cold stimulus to the teeth with showed hypersensitivity in pieces 24 and 25, the pain was 9/10 with the cold stimulus compared to 4/10 in piece 14. The application of topical anesthetic (benzocaine 18% gel) in the oral mucosa and gingival vestibular area of teeth 24 and 25 reduced pain without stimulation, falling from 6/10 to 5/10. Infiltration of local anesthetic (2% lidocaine) reduced pain to 2/10. Previous images showed no abnormalities: periapical, CBCT, MRI of the brain, and CT of the paranasal sinuses.

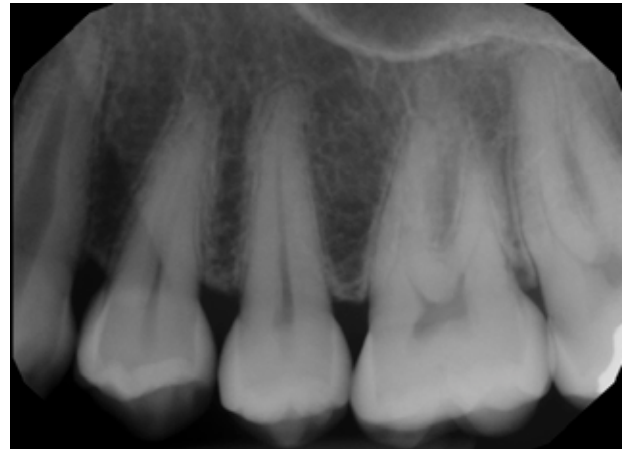


Figure 1: Periapical X ray of the pain area.

DIFFERENTIAL DIAGNOSIS

- Persistent dentoalveolar pain.
- Masticatory myofascial pain with pain referred to the teeth.
- Pre-trigeminal neuralgia.

THERAPEUTIC APPROACH

As initial therapy, she was educated about the condition and was given self care instruction and exercises. In addition, Topiramate (Topamax 25mg Janssen, USA) was prescribed in a titrated dose, starting with 25mg up to 100mg per day. Behavioral therapy was recommended to work on contributing factors.

FOLLOW UP

In the first follow-up at 4 weeks, the patient reported an 80% improvement upon reaching 100mg of Topiramate per day, however, she reported side effects (common for this drug) such as: paresthesia in the hands and legs, partial loss of taste and excessive drowsiness. As a consequence of this excessive side effects, she was not willing to continue with the medication. Intraoral application of botulinum toxin was discussed

as a local option with the goal of decreasing the systemic dose of Topiramate. Following, 50 units of OnabotulinumtoxA, Botox 100u x vial, Allergan USA were applied in the gingival area of tooth #24 distributed in 5 sites: one in the vestibular attached gingiva of 24 and the rest in the interdental papillae (between 23/24/25) by buccal and lingual.

In the second follow-up 4 months later, the patient reported a 50% improvement after the applications of botulinum toxin together with 50 mg of Topiramate daily. It was decided to re-apply the botulinum toxin, but the dose was increased to 150 units in 6 different intraoral sites (interdental papillae from canine to first molar by vestibular and attached gingiva of 24/25 teeth.) One month after the application, the patient reported an 90% improvement, feeling satisfied with the results.

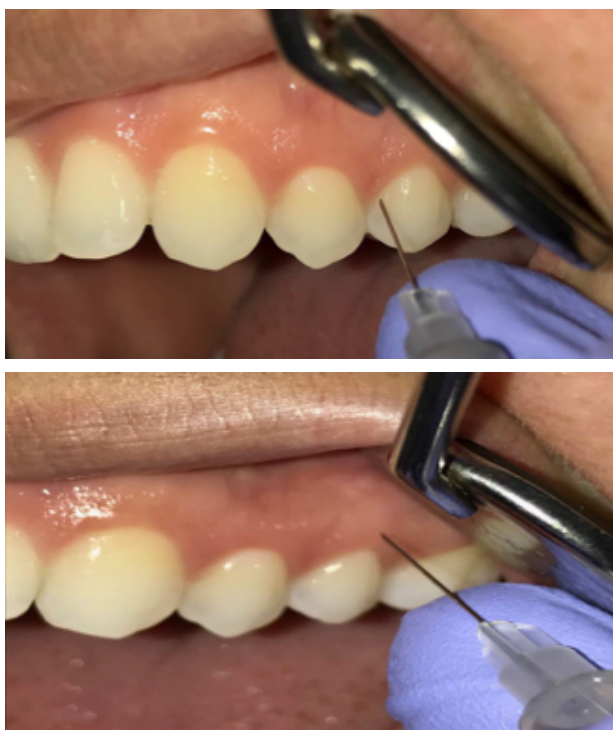

Figure 2: Intraoral sites of infiltration- interpapillary 24/25 and attached gingiva.

DISCUSSION

Persistent idiopathic Dentoalveolar Pain Trastorno de Dolor Dentoalveolar Persistente It is a complex disorder, patients who suffer from it are characterized by a constant search for more dental treatments due to the denial that derives from years of suffering. The treatment of this condition must integrate an interdisciplinary team that includes professionals on psychology or psychiatry. General dentists and specialists should be alert to this condition and before performing an invasive procedure, consider this diagnosis in the absence of apparent organic causes.

The clinical case presented here involved a therapeutic challenge where most of the drugs for systemic use were not tolerated by the patient, situation that is common due to the central nervous system side effects from this kind of medications. Based on the experimental use, application of Botulinum toxin in the painful site is proposed in order to decrease peripheral and central sensitization. In this particular case this approach, allowed to use a lower dose of Topiramate being this strategy being very well tolerated by the patient.

It is the responsibility of the dentist to pay attention to the possible presence of this diagnosis in a patient, since, although it is rare, it has a very large impact on the psyche of those who suffer from it. It is important to note that the diagnosis of persistent dentoalveolar pain is a diagnosis of exclusion and all the most frequent possibilities must be exhausted before affirming that this condition is faced.

Finally, it is important to remark, that an international attempt has been made to bridge consensus about this intricaded condition on

the ICOP 2020; with the development of a standardized diagnostic criteria for persistent idiopathic dentoalveolar pain. Previously, the use of differing terminology and the application of different diagnostic criteria were hindering communication and scientific advancement on this topic. The new Widespread consensus regarding diagnostic criteria presented in the ICOP 2020 gives hope to improve our capacity as clinician and researchers of giving an earlier and better diagnosis.

CONCLUSION

Even recognizing the fact that, the prevalence of PIDAP is relatively low, the impact on quality of life that it can have on patients and on the clinician (dentist) involved is remarkable. The current treatment based on behavioral therapy and pharmacotherapy is in most cases insufficient, given the side effects of the drugs and the challenge for the sufferer on accepting this rare diagnosis. The intraoral application of botulinum toxin as an adjunctive treatment in this diagnosis is an effective alternative, as long as it is applied by a trained clinician due to the potential for severe adverse effects.

Ideally, this disorder should be diagnosed in its early stages. Thus, avoiding making the patient incur multiple dental procedures that will not solve their condition and preventing frustration on the part of the patient and the treating clinician. Unfortunately, this is neither simple nor common.

REFERENCES

1. Marbach J.J., Hulbrock J., Hohn C., Segal A.G. Incidence of phantom tooth pain: An atypical facial neuralgia. *Oral Surgery, Oral Med Oral Pathol.* 1982; 53 (2): 190-3.
2. Rees R.T., Harris M. Atypical odontalgia. *Br J Oral Surg* [Internet]. 1979; 16 (3): 212-8. Available from: <http://dx.doi.org/10.14219/jada.archive.2011.0323>
3. Baad-Hansen L. Atypical odontalgia- Pathophysiology and clinical management. *J Oral Rehabil.* 2008; 35 (1): 1-11.
4. Nixdorf D.R., Drangsholt M.T., Ettlin D.A., Gaul C., De Leeuw R., Svensson P., et al. Classifying orofacial pains: A new proposal of taxonomy based on ontology. *J Oral Rehabil.* 2012; 39 (3):161-9.
5. Nixdorf D.R., Moana-Filho E.J. Nonodontogenic pain after root canal therapy. *Dent Abstr.* 2011; 56 (1): 40-1.
6. Orofacial T., Classification P. International Classification of Orofacial Pain, 1st edition (ICOP). *Cephalalgia.* 2020; 40 (2): 129-221.
7. Melis M., Lobo Lobo S., Ceneviz C., Zawawi K., Al-Badawi E., Maloney G., et al. Views and Perspectives Atypical Odontalgia: A Review of the Literature. *Headache.* 2003; 43:1060-74.
8. Pigg M., Svensson P., Drangsholt M., List T. 7 year follow up of patients Diagnosed with Atypical Odontalgia: A prospective Study. *J Orofac Pain.* 2013; 27 (27): 151-64.
9. Durham J., Nixdorf DR. Healthcare pathway and biopsychosocial impact of persistent dentoalveolar pain disorder: a qualitative study. *Int Endod J.* 2014;47 (12):1151-9.
10. M. B-A, E. V-D, Gay-Escoda C. Atypical odontalgia: A Systematic Review Following the Evidence-Based Principles of Dentistry. *Cranio J Craniomandib Pract.* 2011; 29 (2): 219-26.
11. Forssell H., Jääskeläinen S., List T., Svensson P., Baad-Hansen L. An update on pathophysiological mechanisms related to idiopathic oro-facial pain conditions with implications for management. *J Oral Rehabil.* 2015; 42 (4): 300-22.
12. Ram S., Teruel A., Satish K.S., Clark G. Clinical characteristics and diagnosis of Atypical Odontalgia: Implications for Dentists. *Jada.* 2009; 140: 222-8.
13. Shueb S.S., Nixdorf D.R., John M.T., Alonso B.F., Durham J. ScienceDirect What is the impact of acute and chronic orofacial pain on

- quality of life? J Dent [Internet]. 2015; 43 (10): 1203-10. Available from: <http://dx.doi.org/10.1016/j.jdent.2015.06.001>
14. Durham J., Exley C., John M.T., Nixdorf D.R. Persistent dentoalveolar pain: The patient's experience. J Orofac Pain [Internet]. 2013; 27 (1): 6-13. Available from: <http://www.ncbi.nlm.nih.gov/pubmed/23424715>
 15. Nixdorf D.R., Law A.S., John M.T., Sobieh R.M., Kohli R., Nguyen R.H.N. Differential Diagnoses for Persistent Pain after Root Canal Treatment: A Study in the National Dental Practice-based Research Network. 2015; 41 (4): 457-63.
 16. Nixdorf D.R., Moana-Filho E.J., Law A.S., McGuire L.A., Hodges J.S., John M.T. Frequency of nonodontogenic pain after endodontic therapy: A systematic review and meta-analysis. J Endod [Internet]. 2010; 36 (9): 1494-8. Available from: <http://dx.doi.org/10.1016/j.joen.2010.06.020>
 17. Marbach J.J. Phantom Tooth Pain. J Endod. 1978; 4 (12): 362-72.
 18. Ciaramella A., Paroli M., Lonia L., Bosco M., Poli P. Biopsychosocial Aspects of Atypical Odontalgia. ISRN Neurosci [Internet]. 2013; 2013: 1-10. Available from: <http://www.hindawi.com/ism/neuroscience/2013/413515/>
 19. Marbach J.J. Phantom tooth pain: deafferentation pain. Pa Dent J (Harrisb). 1984; 51 (6): 32-3.
 20. Nixdorf D., Ms D.D.S. Persistent dentoalveolar pain disorder (PDAP): Working towards a better understanding. 2011; (december): 18-25.
 21. Moana-Filho E.J., Bereiter D.A., Nixdorf D.R. Amplified Brain Processing of Dentoalveolar Pressure Stimulus in Persistent Dentoalveolar Pain Disorder Patients. J oral facial pain headache. 2015; 29 (4): 349-62.
 22. Moana-Filho E.J., Nixdorf D.R., Bereiter D.A., John M.T., Harel N. Evaluation of a magnetic resonance-compatible dentoalveolar tactile stimulus device. BMC Neurosci [Internet]. 2010; 11(1):142. Available from: <http://www.ncbi.nlm.nih.gov/pubmed/21029454>
 23. Baad-Hansen L., List T., Jensen T., Svensson P. Increased pain sensitivity to intraoral capsaicin in patients with atypical odontalgia. J Orofac Pain [Internet]. 2006; 20 (2): 107-14. Available from: <http://www.ncbi.nlm.nih.gov/pubmed/16708828>
 24. Ivanovic M., Faris H., List T., Baad-hansen L., Pigg M., El S., et al. Intraoral somatosensory abnormalities in patients with atypical odontalgia-a controlled multicenter quantitative sensory testing study. 2013; 154: 1287-94.
 25. Baad-Hansen L., Pigg M., Ivanovic S.E., Faris H., List T., Drangsholt M., et al. Intraoral somatosensory abnormalities in patients with atypical odontalgia--a controlled multicenter quantitative sensory testing study. Pain [Internet]. 2013; 154 (8):1287-94. Available from: <http://www.ncbi.nlm.nih.gov/pubmed/23725780>
 26. Pigg M. Chronic intraoral pain--assessment of diagnostic methods and prognosis. [Internet]. Swedish dental journal. Supplement. 2011. 7-91 p. Available from: <http://www.ncbi.nlm.nih.gov/pubmed/22338784>
 27. Clark G.T. Pain and Pain Control Persistent neuropathic pain. Calif Dent Assoc J. 2006; 34 (4): 599-600.
 28. Graff-Radford S.B., Solberg W.K. Atypical Odontalgia. J Craniomandib Disord Oral Facial Pain. 1992; 6: 260-6.
 29. Melis M., Secci S. Diagnosis and treatment of atypical odontalgia: a review of the literature and two case reports. J Contemp Dent Pract [Internet]. 2007; 8 (3): 81-9. Available from: <http://www.ncbi.nlm.nih.gov/pubmed/17351685>
 30. Ito M., Kimura H., Yoshida K., Kimura Y., Ozaki N., Kurita K. Effectiveness of milnacipran for the treatment of chronic pain in the orofacial region. Clin Neuropharmacol. 2010; 33 (2): 79-83.

31. Nagashima W., Kimura H., Ito M., Tokura T., Arao M., Aleksic B., et al. Effectiveness of Duloxetine for the Treatment of Chronic Nonorganic Orofacial Pain. *Clin Neuropharmacol* [Internet]. 2012; 35 (6): 1-5. Available from: <http://www.ncbi.nlm.nih.gov/pubmed/23123692>
32. Zagury J.G., Eliav E., Heir G.M., Nasri-Heir C., Ananthan S., Pertes R., et al. Prolonged gingival cold allodynia: A novel finding in patients with atypical odontalgia. *Oral Surgery, Oral Med Oral Pathol Oral Radiol Endodontology* [Internet]. 2011; 111 (3): 312-9. Available from: <http://dx.doi.org/10.1016/j.tripleo.2010.10.008>
33. Babiloni A.H., Kapos F.P., Nixdorf D.R. Intraoral administration of botulinum toxin for trigeminal neuropathic pain. *Oral Surgery, Oral Med Oral Pathol Oral Radiol* [Internet]. 2016; 121 (6): e148-53. Available from: <http://dx.doi.org/10.1016/j.oooo.2016.03.013>
34. Clark G.T., Stiles A., Lockerman L.Z., Gross S.G. A Critical Review of the Use of Botulinum Toxin in Orofacial Pain Disorders. *Dent Clin North Am*. 2007; 51 (1): 245-61.
35. Cuadrado M-L, García-Moreno H., Arias J-A, Pareja JA. Botulinum Neurotoxin Type-A for the Treatment of Atypical Odontalgia. *Pain Med* [Internet]. 2016;pnw040. Available from: <http://painmedicine.oxfordjournals.org/lookup/doi/10.1093/pm/pnw040>
36. Baad-Hansen L. Comparison of Clinical findings and Psychosocial factors in patients with Atypical Odontalgia and Temporomandibular Disorders. *J Oral Rehabil*. 2008; 22: 7-14.
37. Hals E.K.B., Stubhaug A. Mental and somatic co-morbidities in chronic orofacial pain conditions: Pain patients in need of multiprofessional team approach. *Scand J Pain* [Internet]. 2011; 2 (4): 153-4. Available from: <http://dx.doi.org/10.1016/j.sjpain.2011.08.003>
38. List T., Leijon G., Helkimo M., Oster A., Dworkin S.F., Svensson P. Clinical findings and psychosocial factors in patients with atypical odontalgia: a case-control study. *J Orofac Pain* [Internet]. 2007; 21 (2): 89-98. Available from: 17547120.



Attribution (BY-NC) - (BY) You must give appropriate credit, provide a link to the license, and indicate if changes were made. You may do so in any reasonable manner, but not in any way that suggest the licensor endorses you or your use. (NC) You may not use the material for commercial purposes.