

Received:
24-XI-2020

Accepted:
14-I-2021

Published Online:
2-III-2021

Oral Health Status After Orthodontic Treatment: a Retrospective Study

Estado de salud bucal después del tratamiento de ortodoncia: un estudio retrospectivo

Gul Yildiz Telatar DDS¹; Baris Can Telatar DDS²

1. Department of Restorative Dentistry, Recep Tayyip Erdogan University, Faculty of Dentistry, Rize, Turkey. <https://orcid.org/0000-0001-5137-9282>

2. Private Practice of Orthodontics, Rize Turkey. <https://orcid.org/0000-0002-0632-0617>

Correspondence to: Dr. Gul Yildiz Telatar - gulyildiz@gmail.com

ABSTRACT: Orthodontic appliances in the oral cavity may cause problems such as white spot lesions, dental plaque, periodontal disease and root resorption. The aim of this study was to investigate the association between orthodontic treatment and oral health parameters including visible dental plaque, gingival recession and white spot lesions (WSLs). A total of 170 patients (86 females, 84 males) were randomly selected to determine visible dental plaque, gingival recession and white spot lesions by using pre-treatment and post-treatment oral photographs. Except of previously extracted teeth, maxillary and mandibular incisors, canine, 1st and 2nd premolars and 1st molar were evaluated. There was a significant difference between the T0 (before treatment) and T1 (after treatment) groups in visible plaque ($P < 0.001$). The distribution of gingival recession frequencies according to Miller classification before treatment did not differ from the after treatment ($P = .082$). A statistically significant increase in the severity of WSL was detected between the two time points ($P < 0.001$). Males have been shown to have higher WSL incidence after treatment. In conclusion, the present study showed that visible dental plaque and white spot lesions significant increase after orthodontic treatment. Considering the relationship between oral health and orthodontic treatment, clinicians and patients should know the risks and take precautions.

KEY WORDS: Orthodontic treatment; Dental plaque; Gingival recession; White spot lesions.

RESUMEN: Los aparatos de ortodoncia en la cavidad oral puede causar problemas como lesiones de mancha blanca, placa dental, enfermedad periodontal y reabsorción radicular. El objetivo de este estudio fue investigar la asociación entre el tratamiento de ortodoncia y los parámetros de salud bucal, incluida la placa dental visible, la recesión gingival y las lesiones de mancha blanca (LMB). Un total de 170 pacientes (86 mujeres, 84 hombres) fueron seleccionados al azar para determinar la placa dental visible, la recesión gingival y las lesiones de manchas blancas mediante el uso de fotografías orales antes y después del tratamiento. Excepto los dientes extraídos previamente, se evaluaron incisivos maxilares y mandibulares, caninos, premolares y primeros molares. Hubo una diferencia significativa entre los grupos T0 (antes del tratamiento) y T1 (después del tratamiento) en la placa visible ($P < 0.001$). La distribución de las frecuencias de recesión gingival según la clasificación de Miller antes del tratamiento no mostraron diferencias significativas con respecto al postratamiento ($P = 0.082$). Se detectó un aumento estadísticamente significativo en la gravedad de LMB entre los dos puntos de tiempo ($P < 0.001$). Se ha demostrado que los hombres tienen una mayor incidencia de LMB después del tratamiento. En conclusión, el presente estudio mostró que la placa dental visible y las lesiones de manchas blancas aumentaron significativamente durante el tratamiento de ortodoncia. Teniendo en cuenta la relación entre la salud bucal y el tratamiento de ortodoncia, los médicos y los pacientes deben conocer los riesgos y tomar precauciones.

PALABRAS CLAVE: Tratamiento de ortodoncia; Placa dental; Recesión gingival; Lesiones de mancha blanca.

INTRODUCTION

Placement of fixed orthodontic appliances in the oral cavity may cause problems such as white spot lesions, dental plaque, periodontal disease and root resorptions (1,2). Plaque bacteria in the oral cavity is the most important factor in the progression of periodontal disease and dental caries (3).

Oral hygiene maintenance becomes difficult due to the presence of brackets, belts, springs, coils and belt wires used during orthodontic treatment (4). Acidogenic bacteria metabolize carbohydrates and produce acid, which in turn leads to decrease of the plaque pH. When the pH of oral cavity is below 5.5, calcium and phosphate ions released from hydroxyapatite crystals in enamel. Thus, demineralization occurs in enamel and white spot lesions (WSL) are seen (5,6). Formation of the

white spot lesions around orthodontic brackets can occur within 4 weeks after beginning of the treatment (7). The prevalence of white spots among orthodontic patients ranges from 2% to 96% (7,8).

The hypothesis is that orthodontic treatment negatively affect the oral hygiene maintenance, could increase dental plaque and demineralization. The objective of current retrospective study was to investigate the relationships between orthodontic treatment and oral health parameters including visible dental plaque, gingival recession and white spot lesions.

MATERIALS AND METHODS

This study was approved by the Non-Interventional Clinical Research Ethics Committee of Recep Tayyip Erdogan University (protocol number: 2020/60). All procedures were performed

in accordance with the Declaration of Helsinki and informed consent was obtained from all patients before being included in the study. The material of our study consisted of 170 individuals who were treated between 2017-2020 at the private orthodontic clinic in Rize, Turkey. Clinical oral photographs of patients were used before and after treatment for oral health evaluations. The exclusion criteria were the history of systemic or genetic diseases, regular medication use, cleft lip and palate, orthognathic surgery and fluorosis.

The oral health status, including visible plaque, gingival recession and white spot lesions was evaluated with the help of intraoral photographs by one calibrated examiner. Clinical oral photographs were captured using a Canon (Canon, Tokyo, Japan) digital camera 550D camera body with a 2.8/100 mm macro lens. The camera was equipped with Canon Macro Ring Lite MR-14EX II light flash.

Each intraoral photography including sagittal and frontal plane was analyzed on a computer screen in a room with dimmed ambient lighting. Then, the visible plaque, labial gingival recession and white spot lesions were recorded. Except of previously extracted teeth, maxillary and mandibular incisors, canine, 1st and 2nd premolars and 1st molar were evaluated. The visible plaque scoring on the photograhly was made according to the previously described study (9). According to Miller's classification the gingival recession was scored (10).

Before (T0) and after treatment (T1), teeth were evaluated used a modified white spot lesion index (WSL-Index) by Gorelick *et al* (8). The visual slide evaluation of the individual teeth was based on a labial surface examination assessing the severity of WSL.

Intrarater reliability was assessed by comparing two measurements carried out by

the examiner. The examiner first analyzed the parameters of 25 photographs, and then reanalyzed them in the same images 2 weeks later: A high level of agreement was found between two periods (coefficient alpha: 0.97).

STATISTICAL ANALYSIS

The SPSS23.0 statistical software package was used for data processing. The Shapiro-Wilk test was used to test the likelihood that the distribution of data was normal.

The differences in three age groups across the mean age and mean treatment duration (month) were compared with Student's t-tests. The chi-square (χ^2) test was used for comparisons of gender and angle classification between the age groups.

The differences in before and after treatment across categories of gingival recession and white spot lesions were compared McNemar-Bowker test. Intergroup differences between treatment periods were investigated with paired t-test for visible plaque evaluation.

RESULTS

The patient demographic variables before treatment are presented in Table 1. The clinical photographs of 170 subjects (84 males and 86 females) with a mean age of 16.2 years were included in this study. Angle Class 3 frequency was significantly less frequent in the all age groups ($p=0.027$).

Distributions of visible plaque and gingival recession before and after orthodontic treatment groups are listed in Table 2. There was significant difference between the T0 and T1 groups in visible plaque (1.54 ± 0.50 ; $P < 0.001$). Mean dental plaque was observed 0.5 (SD=0.2) in the pretreatment and 2.1 (SD=0.4) in posttreatment groups, respectively. The distribution of gingival recession

frequencies according to Miller classification before treatment did not differ from the after treatment ($P=0.082$).

The total number of white spot lesions at the two time points, T0 and T1, are presented in Table 3. Before treatment 3755 (93.7%) of the 4008 teeth did not exhibit WSL on the labial surfaces. The 10 teeth exhibited severe WSL at T0, after treatment severe

lesions were found in 116 teeth. A statistically significant increase in the severity of WSL was detected between the two time points ($P<.001$).

It has been determined that the incidence of WSL after treatment tends to exhibit more WSL in males than in female patients (Figure 1). According to this, 248 teeth exhibited WSL in females and males had 342 WSL on their teeth after treatment.

Table 1. Demographic variables of the study.

	Age ≤ 12 (n=57)	12 < Age >16 (n=58)	Age ≥ 16 (n=55)	Total
Age (mean±SD) ^a	10.9±1.1	14.6±0.5	23.4±1.8	16.2±5.3
Gender (n, %) ^b				
Female	28 (49.1)	30 (51.7)	28 (50.9)	86 (50.6)
Male	29 (50.9)	28 (48.3)	27 (49.1)	84 (49.4)
Treatment Duration (month) (mean±SD) ^a	19±2.6	20±2.5	22±4.1	20.6±3.2
Angle Classification(n, %) ^b				
Class 1	22 (38.6)	26 (44.8)	29 (52.7)	77 (45.2)
Class 2	20 (35.1)	22 (37.9)	24 (43.6)	66 (33.8)
Class 3	15 (26.3)	10 (17.2)	2 (3.6)	27 (21.0)

^aStudent's t-test, ^bχ² test.

Table 2. Distribution of visible plaque and gingival recession values in the patients.

	Before Treatment (T0)	After Treatment (T1)	P-value
Visible plaque (mean±SD) ^a	0.5±0.2	2.1±0.4	< 0.001
Gingival recession (by Miller index) (n, %) ^b			
Absent	3852 (96.1)	3847 (95.1)	
Class I	140 (3.5)	142 (4.2)	.082
Class II	16 (0.4)	19 (0.7)	

^aPaired t-tests, ^bMcNemar-Bowker test

Table 3. Number and percentage of buccal surfaces with WSL detected at T0 and T1 on photographs.

	Before Treatment (T0) (n,%)	After Treatment (T1) (n,%)	P-value ^a
No WSL	3755 (93.7)	3418 (85.3)	<0.001
Slight WSL	241 (6.0)	420 (10.5)	
Severe WSL	10 (0.25)	116 (2.9)	
Cavitation WSL	2 (0.05)	54 (1.3)	

^aMcNemar-Bowker test

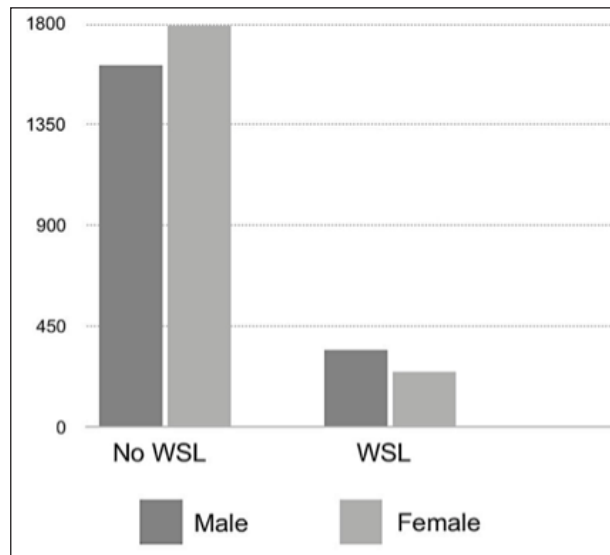


Figure 1. Distribution of the WSLs among the gender groups after treatment.

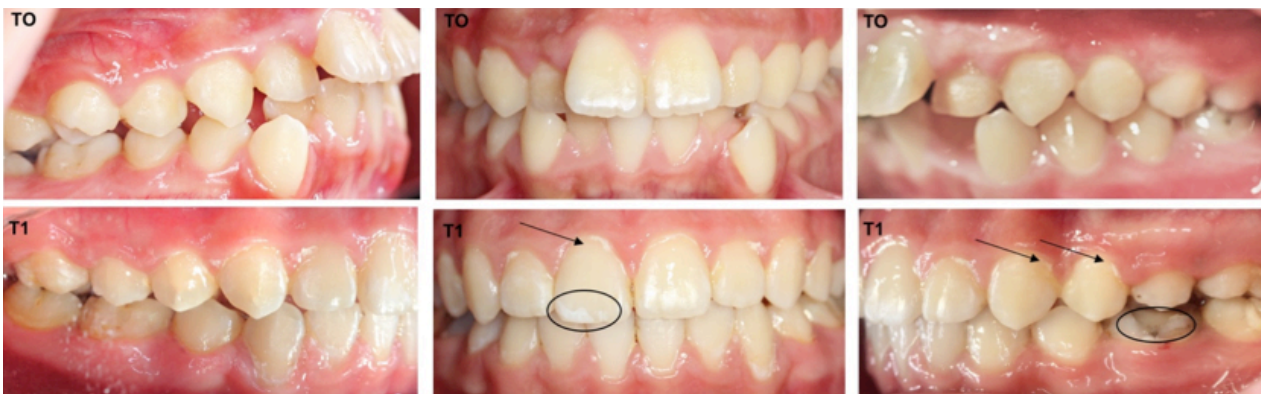


Figure 2. Example of clinical oral photographs from one subject captured at before (T0) and after (T1) orthodontic treatment. The arrow used to show dental plaque, WSL is also seen in the circle.

DISCUSSION

The purpose of current study was to investigate the relationships between orthodontic treatment and oral health parameters using intraoral photographs. In the literature, several researchers have used intraoral images to evaluate white spot lesions and periodontal status before, during, or after orthodontic treatment (8,11,12). In this study, standardized intraoral photographs were used to achieve the retrospective visual examinations. This method has also been referred in literature as a reliable method (9,13,14).

In present study, the visible plaque values increased statistically significant between the baseline and the end of treatment in all patients. This results are similar to the findings of the previous research, which presented that orthodontic appliances form a retention site for plaque (14). Similarly, Boke *et al.* have reported that the mean value of visible dental plaque showed significant increases during orthodontic treatment (11). Although some studies consistent that amount of dental plaque increases by fixed orthodontic treatment (15), some researchs have not observed increases (16,17). This difference

might be attributed to the study duration times and educations given to patients (16).

The examination of gingival recessions in present study was carried out only on color images according to the Miller classification. This method demonstrated to be reliable, informative, and reproducible (18). According to our results, the distribution of gingival recession frequencies before treatment did not differ from the after treatment. Experimental evidence shows that orthodontic tooth movement does not actually cause gingival recession but can create an predisposing environment especially if the teeth are repositioned in a facial direction (19). It has been reported that orthodontic treatment is not main factor for gingival recession however it might has an indirect effect on gingival recession if teeth are repositioned in a labial direction. Recession during orthodontic treatment may not be progressive and the response may be more related to individual variation in the quality of the gingival tissues around specific dentoalveolar areas (20). Orthodontic treatment is not an important risk factor for the development of gingival recession. Although greater amounts of maxillary expansion during treatment increase the risks of posttreatment recession, the effects are minimal (21). Most studies assessing recession just after orthodontic treatment have been shown no relationship (22,23).

We found that 6.3% of the patients exhibited WSL already before treatment. This result lies within the range reported in previous study by Lavrov *et al.* (24). They speculated 15.5 % of pateints have WSL at the beginning of the treatment. In contrast, other studies reported much higher WSL prevalences before treatment due to the use of different WSL scoring systems and different WSL definitions (8,25,26). In present study, Gorelick index was used for WSL detection. The original or modification of this scoring system is commonly used for evaluation of WSL (13). Based on photographs examination this study showed

orthodontic treatment caused increased WSL prevalence. Our result is similar to the findings of the previous studies, which showed that higher WSL prevalence associated with orthodontic treatments (8,27). Calculus formation and increased plaque accumulation during orthodontic treatment could be reason for new WSL development (28,29). It has also been reported that diffuculty of cleaning orthodontic appliances fixed at the critical sites leading to enamel decalcification and white spot lesion formation around orthodontic brackets (30).

In our study male patients have been shown to have higher WSL incidence after treatment. A previous study reported that male and female patients had WSL incidences of 46% and 29%, respectively after orthodontic treatment (31). Similarly, Boersma *et al.* found that 40% of the buccal surfaces in male patients had demineralization, compared with %22 in females (6). Julien *et al.* reported the percentage of male subjects who developed WSLs during treatment to be higher (%25) than the percentage of females (%22) (32). In contrast, Akin *et al.* suggested that gender was not a significant factor in WSL development (13). This gender difference may be due to the commonly reported better oral hygiene habits in female patients than in males (33).

There were limitations of this study. Oral hygiene habits of the patients could not be evaluated before the treatment. It has been reported that use of prophylactic fluoride supplements during orthodontic treatment might inhibit demineralization (13). The lack of present study was evaluation of the effectiveness of preventive treatments.

CONCLUSIONS

By using only standardized general photographic records, this study presented that the mean plaque values and white spot lesions exhibited significant increases during orthodontic treatment. Although gingival recessions were not associated with fixed appliance treatment. Considering the

relationship between oral health and orthodontic treatment, clinicians and patients should know the risks and take precautions.

CONFLICT OF INTEREST

The authors declare no conflicts of interest.

REFERENCES

1. Segal G.R., Schiffman P.H., Tuncay O.C. Meta analysis of the treatment-related factors of external apical root resorption. *Orthod Craniofac Res.* 2004; 7 (2): 71-8.
2. Balenseifen J.W., Madonia J. V. Study of Dental Plaque in Orthodontic Patients. *J Dent Res.* 1970; 49: 320-4.
3. Ousehal L., Lazrak L., Es-said R., Hamdoune H., Elquars F., Khadija A. Evaluation of dental plaque control in patients wearing fixed orthodontic appliances: A clinical study. *Int Orthod.* 2011; 9: 140-55.
4. Al-Kawari H.M., Al-Jobair A.M. Effect of different preventive agents on bracket shear bond strength: In vitro study. *BMC Oral Health [Internet].* 2014; 14 (1): 1-6. Available from: BMC Oral Health.
5. Staley R.N. Effect of Fluoride Varnish on Demineralization Around Orthodontic Brackets. *Semin Orthod.* 2008;14 (3): 194-9.
6. Boersma J.G., Van Der Veen M.H., Lagerweij M.D., Bokhout B., Prahl-Andersen B. Caries prevalence measured with QLF after treatment with fixed orthodontic appliances: Influencing factors. *Caries Res.* 2005; 39: 41-7.
7. Srivastava K., Tikku T., Khanna R., Sachan K. Risk factors and management of white spot lesions in orthodontics. *J Orthod Sci.* 2013; 2 (2): 43-9.
8. Gorelick L., Geiger A.M., John A. Incidence of white spot Jbmxation after bonding and banding. *Am J Orthod.* 1982; 81: 93-8.
9. Kelly A., Antonio A.G., Maia L.C., Luiz R.R., Vianna R.B.C., Quintanilha L.E.L.P. Reliability assessment of a plaque scoring index using photographs. *Methods Inf Med.* 2008; 47 (5): 443-7.
10. Geiger A.M. Mucogingival problems and the movement of mandibular incisors: A clinical review. *Am J Orthod.* 1980; 78 (5): 511-27.
11. Boke F., Gazioglu C., Akkaya S., Akkaya M. Relationship between orthodontic treatment and gingival health: A retrospective study. *Eur J Dent.* 2014; 8 (3): 373-80.
12. Mattick C.R., Mitchell L., Chadwick S.M., Wright J. Fluoride-releasing elastomeric modules reduce decalcification: A randomized controlled trial. *J Orthod.* 2001; 28: 217-9.
13. Akin M., Tazcan M., Ileri Z., Basciftci F.A. Incidence of White Spot Lesion During Fixed Orthodontic Treatment. *Turkish J Orthod.* 2013; 26 (2): 98-102.
14. Beerens M.W., Boekitwetan F., Van Der Veen M.H., Ten Cate J.M. White spot lesions after orthodontic treatment assessed by clinical photographs and by quantitative light-induced fluorescence imaging; A retrospective study. *Acta Odontol Scand.* 2014; 73 (6): 441-6.
15. Alexander S.A. Effects of orthodontic attachments on the gingival health of permanent second molars. *Am J Orthod Dentofac Orthop.* 1991; 100 (4): 337-40.
16. Rakhshan H., Rakhshan V. Effects of the initial stage of active fixed orthodontic treatment and sex on dental plaque accumulation: A preliminary prospective cohort study. *Saudi J Dent Res [Internet].* 2015; 6 (2): 86-90. Available from: <http://dx.doi.org/10.1016/j.sjdr.2014.09.001>
17. Edith L.C., Montiel-Bastida N.M., Leonor S.P., Jorge A.T. Changes in the oral environment during four stages of orthodontic treatment. *Korean J Orthod.* 2010; 40 (2): 95-105.

18. Melsen B., Allais D. Factors of importance for the development of dehiscences during labial movement of mandibular incisors. *Am J Orthod Dentofac Orthop.* 2005; 127: 552-61.
19. Wennström J.L., Lindhe J., Sinclair F., Thilander B. Some periodontal tissue reactions to orthodontic tooth movement in monkeys. *J Clin Periodontol.* 1987; 14: 121-9.
20. Joss-Vassalli I., Grebenstein C., Topouzelis N., Sculean A., Katsaros C. Orthodontic therapy and gingival recession: A systematic review. *Orthod Craniofac Res.* 2010;13: 127-41.
21. Morris J.W., Campbell P.M., Tadlock L.P., Boley J., Buschang P.H. Prevalence of gingival recession after orthodontic tooth movements. *Am J Orthod Dentofac Orthop* [Internet]. 2017; 151 (5): 851-9. Available from: <http://dx.doi.org/10.1016/j.ajodo.2016.09.027>
22. Årtun J., Grobety D. Periodontal status of mandibular incisors after pronounced orthodontic advancement during adolescence: A follow-up evaluation. *Am J Orthod Dentofac Orthop.* 2001; 119 (1): 2-10.
23. Djeu G., Hayes C., Zawaideh S. Correlation between Mandibular Central Incisor Proclination and Gingival Recession during Fixed Appliance Therapy. *Angle Orthod.* 2002; 72: 238-45.
24. Lovrov S., Hertrich K., Hirschfelder U. Enamel Demineralization during Fixed Orthodontic Treatment-Incidence and Correlation to Various Oral-hygiene Parameters Schmelzdemineralisation während festsitzender kieferorthopädischer Behandlung-Inzidenz und Zusammenhang mit verschiedenen Parametern. *J Orofac Orthop/Fortschritte der Kieferorthopädie.* 2007; 68: 353-63.
25. Lucchese A., Gherlone E. Prevalence of white-spot lesions before and during orthodontic treatment with fixed appliances. *Eur J Orthod.* 2013; 35 (5): 664-8.
26. Mizrahi E. Enamel demineralization following orthodontic treatment. *Am J Orthod.* 1982; 82: 62-7.
27. Øgaard B., Larsson E., Henriksson T., Birkhed D., Bishara S.E. Effects of combined application of antimicrobial and fluoride varnishes in orthodontic patients. *Am J Orthod Dentofac Orthop.* 2001; 120 (28): 35.
28. Zimmer B.W., Rottwinkel Y. Assessing patient-specific decalcification risk in fixed orthodontic treatment and its impact on prophylactic procedures. *Am J Orthod Dentofac Orthop.* 2004; 126: 318-24.
29. Willmot D.R. Scientific section: White lesions after orthodontic treatment: Does low fluoride make a difference? *J Orthod.* 2004; 78: 1049.
30. Moolya N., Sharma R., Shetty A., Gupta N., Gupta A., Jalan V. Orthodontic bracket designs and their impact on microbial profile and periodontal disease: A clinical trial. *J Orthod Sci.* 2014; 3 (4): 125-31.
31. Chapman J.A., Roberts W.E., Eckert G.J., Kula K.S., González-Cabezas C. Risk factors for incidence and severity of white spot lesions during treatment with fixed orthodontic appliances. *Am J Orthod Dentofac Orthop.* 2010; 138 (2): 188-94.
32. Julien K.C., Buschang P.H., Campbell P.M. Prevalence of white spot lesion formation during orthodontic treatment. *Angle Orthod.* 2013; 83: 641-7.
33. Sundararaj D., Venkatachalapathy S., Tandon A., Pereira A. Critical evaluation of incidence and prevalence of white spot lesions during fixed orthodontic appliance treatment: A meta-analysis. *J Int Soc Prev Community Dent.* 2015; 5 (6): 433-9.



Attribution (BY-NC) - (BY) You must give appropriate credit, provide a link to the license, and indicate if changes were made. You may do so in any reasonable manner, but not in any way that suggest the licensor endorses you or your use. (NC) You may not use the material for commercial purposes.