

CASE REPORT

DOI: 10.15517/IJDS.2022.48720

Received:
1-IX-2021

Incidental Finding of Bullous Concha by Cone Beam
Computed Tomography

Accepted:
4-X-2021

Published Online:
18-X-2021

Hallazgo incidental de concha bullosa por tomografía computarizada
de haz cónico

Débora M. Távora DDS, MSc, PhD¹; Gina D. Roque-Torres DDS, MSc, PhD²;
Elíana D. Costa DDS, MSc, PhD³; Danieli M. Brasil DDS, MSc, PhD⁴;
Matheus L. Oliveira DDS, MSc, PhD⁵

1. Metropolitan Faculty of Grande Fortaleza. Fortaleza, Ceara, Brazil.

<https://orcid.org/0000-0002-7063-2607>

2. Center for Dental Research, School of Dentistry, Loma Linda University, California, USA.

<https://orcid.org/0000-0003-3848-4891>

3. Division of Oral Radiology, Department of Oral Diagnosis, Piracicaba Dental School, University of Campinas. Piracicaba, São Paulo, Brazil. <https://orcid.org/0000-0003-4463-7436>

4. Division of Oral Radiology, Department of Oral Diagnosis, Piracicaba Dental School, University of Campinas. Piracicaba, São Paulo, Brazil. <https://orcid.org/0000-0002-9519-4578>

5. Division of Oral Radiology, Department of Oral Diagnosis, Piracicaba Dental School, University of Campinas. Piracicaba, São Paulo, Brazil. <https://orcid.org/0000-0002-8054-8759>

Correspondence to: Dra. Danieli Moura Brasil - danielibrasil@hotmail.com

ABSTRACT: This study aimed to describe the imaging aspects of a concha bullosa discovered incidentally by means of cone-beam computed tomography (CBCT) imaging. A female patient underwent a CBCT exam, and a bilateral extensive pneumatization of the middle concha was verified, presenting a larger dimension of the right side and a deviated septum. The patient reported nasal obstruction and loss of smell. The CBCT for covering the maxillofacial region allowed the discovery of this incidental finding, allowing the patient to be referred for appropriate treatment.

KEYWORDS: Turbinates; Anatomic variation; Paranasal sinuses; Cone-beam computed tomography.

RESUMEN: Este estudio tuvo como objetivo describir los aspectos imaginológicos de una concha bullosa hallada incidentalmente por medio de imágenes de tomografía computarizada de haz cónico (TCHC). Una paciente de sexo femenino fue sometida a examen de TCHC y se verificó una neumatización extensa bilateral de la concha media, presentando una mayor dimensión del lado derecho, así como desvío del tabique. El paciente refirió obstrucción nasal y pérdida del olfato. La TCHC de la región maxilofacial permitió localizar este hallazgo incidental, permitiendo derivar al paciente para el tratamiento adecuado.

PALABRAS CLAVE: Cornetes nasales; Variación anatómica; Senos paranasales; Tomografía computarizada de haz cónico; Hallazgos incidentales.

INTRODUCTION

The nasal cavity is divided by a central septum in two lateral compartments, whose external walls are composed of the superior, middle and inferior conchae. The space beneath the nasal conchae represents a passage of the nasal cavity and is defined as meatus (1).

The nasal structures can be affected by different anatomical variations, such as pneumatization (concha bullosa), paradoxical curvature, bifurcation, trifurcation and the presence of secondary and accessory conchae (2). The most common anatomical variation is the concha bullosa (3), which consists of a pneumatic cavity present inside the nasal concha (1,2), presenting as a clinical implication the narrow or block the ostiomeatal channels and disrupt the normal airflow and the mucociliary clearance of the sinuses (4).

Concha bullosa can be identified by means of clinical evaluation, endoscopy and computed tomography (CT) (5). Cone-beam CT (CBCT) has demonstrated great accuracy in depicting fine anatomical structures of hard tissues (6). Thus, the aim of this case report was to describe the imaging aspects of a concha bullosa discovered incidentally in a CBCT scan and to discuss with the current scientific literature.

CASE REPORT

A 22-year-old white female patient was referred to the radiology clinic. A CBCT scan was obtained for orthodontic purposes by using the I-Cat unit (Imaging Sciences International, Pennsylvania, USA) with a field of view of 13x17 cm, voxel size of 0.25mm and exposure time of 40 seconds, after collecting informed consent from the patient. CBCT multiplanar reconstructions (Figure 1, Figure 2 and Figure 3) revealed as an incidental finding the presence of a bilateral middle turbinate pneumatization of an extensive type according to Bolger's classification (7). In the coronal reconstructions, the right side showed a larger extension than the left side with multiple septa, giving rise to small cells (Figure 1). In axial sections, the deviations of the nasal septum are observed on the right side (Figure 2). Figure 3 shows the 3D reconstruction of the concha bullosa. Figure 4 shows the image of a patient with nasal concha without pneumatization.

The patient was not aware of having this condition, nor did she recall any trauma in the nasal region, but reported mild nasal obstruction and loss of olfaction. The patient was referred to the otolaryngologist. After a careful evaluation of the clinical history and CBCT images, surgical intervention was disregarded because no limiting symptom was present, being indicated the clinical follow-up of the patient.

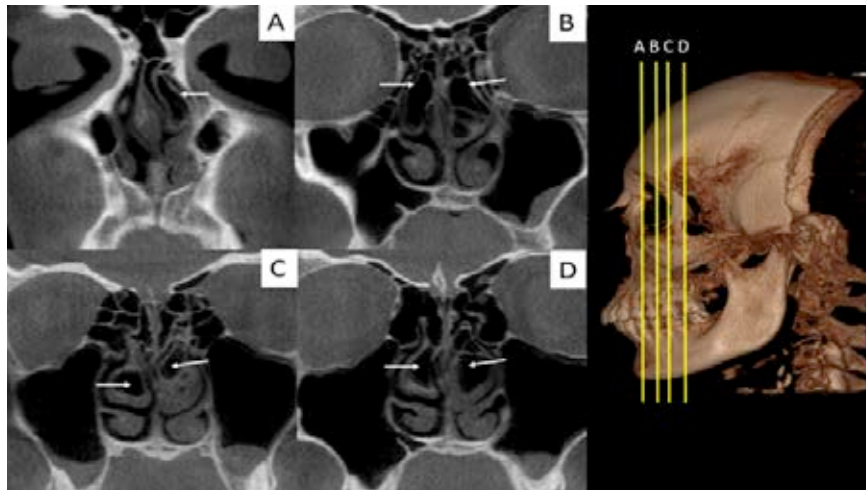


Figure 1. Coronal reconstructions of the nasal cavity (A,B,C,D). Full arrows indicate the concha bullosa with septation.

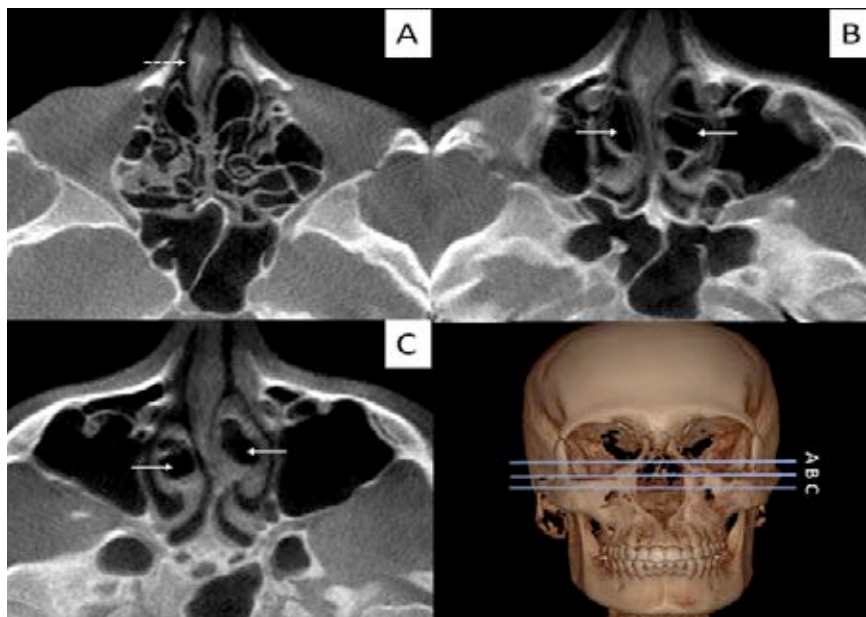


Figure 2. Axial reconstructions of the nasal cavity (A,B,C). Arrows indicate concha bullosa and dashed arrow indicate nasal septum deviation.

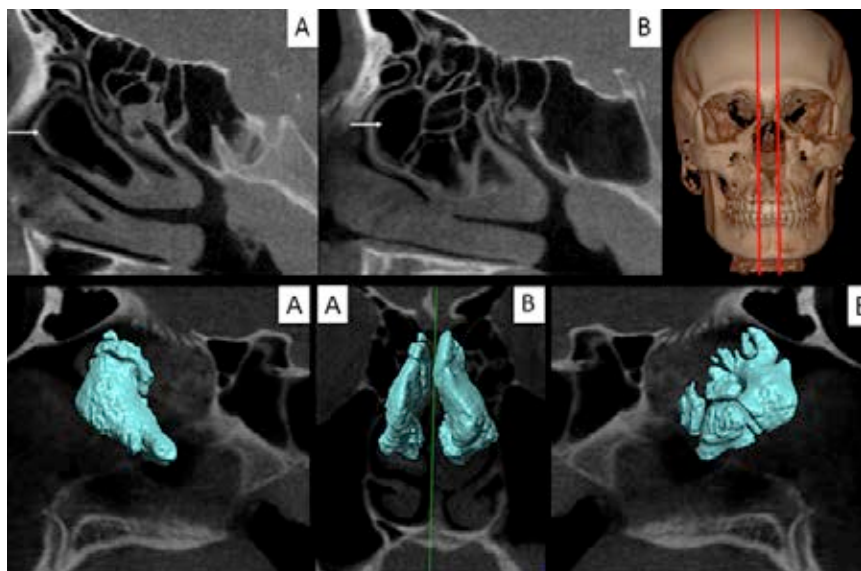


Figure 3. Sagittal reconstructions of the nasal cavity, right(A) and left side(B). Arrows indicate the concha bullosa. 3D Concha bullosa (in blue).

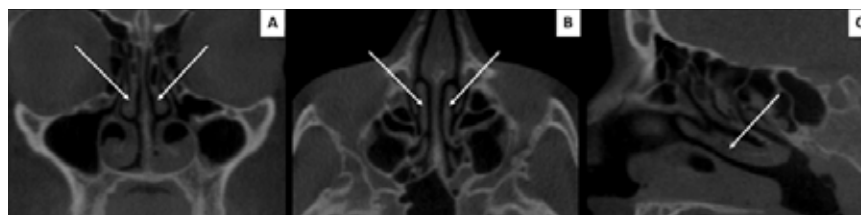


Figure 4. Coronal(A), axial(B) and sagittal(C) reconstructions of the nasal cavity indicating patient with nasal concha without pneumatization.

DISCUSSION

Concha bullosa is defined as a partial or complete pneumatization of the turbinate (8), that tends to be asymptomatic, but in some cases may constitute a mass that impairs ventilation and mucus drainage of the ostiomeatal region, leading to sinusitis (1,9).

The scientific literature has suggested the existence of two theories for the cause of middle turbinate pneumatization, one related to compensatory changes in airflow due to nasal septum deviation, and another to individual anatomical variations (2). It is still observed that

mouth breathers may present a higher incidence of concha bullosa with loss of olfaction (10), which is in agreement with the present case. Besides that, the nasal septum and the middle concha develop around the same time, but concha bullosa arises later.

Several studies have reported the presence of both concha bullosa and nasal septum deviation (4,11,12), which is in agreement with the present case. Conversely, Uygur *et al* (13) evaluated a group of 100 people with extensive concha bullosa and only two patients (2%) presented deviated nasal septum. Moreover, according to Bolger *et al* (7), the concha bullosa can be classified into

lamellar type that shows pneumatization in the vertical blade of the middle concha, and bullous and extensive types that show pneumatization in the lower part and the entire concha, respectively. The patient reported, in this case, presents the extensive type of concha bullosa, which is the least common type and represents 15.7% of the cases reported in the literature.

In this sense, the progress of modern imaging modalities, such as computed tomography (CT), makes possible a better treatment plan before nose/sinus surgery. CT provides accurate information and provides fine details of the patient's anatomy, revealing the presence of anatomical variations (1,9). Surgical approach of concha bullosa should carefully preserve the medial lamella and resect only the lateral half of the turbinate. Nasal surgeons can establish accurate and safe access to the lumen of the concha bullosa by evaluating the limits and extensions of the middle turbinate pneumatization on CT images (9). Cone-beam CT images of the present case revealed bilateral concha bullosa with some septa on the left side and nasal septum deviation. Surgical excision was not indicated because no significant symptoms were observed. In cases where surgery is needed, CBCT images are strongly recommended for successful surgical planning.

Although the nasal structures are not the main area of expertise of dental practitioners, a good understanding of the normal anatomy and most common anatomical variations is important, due to the possibility of the discovery of incidental findings (14), and that in the present study it was possible to refer the patient to the otorhinolaryngologist. Furthermore, it is observed that the benefit-risk when prescribing the CBCT

exam should be considered, due to the biological effects of X-radiation.

CONCLUSION

Cases of concha bullosa with multiple septa are still scarce, however, the increasing use of modern imaging modalities, such as CBCT, favors the detection of this anatomical variation.

ACKNOWLEDGMENTS

The authors gratefully acknowledge financial support from Coordenação de Aperfeiçoamento de Pessoal de Nível Superior – Brazil (CAPES) – Finance Code 001.

AUTHOR CONTRIBUTION STATEMENT

Conceptualization and Design: D.M.T. and G.D.R-T.
 Literature Review: E.D.C. and D.M.B.
 Methodology and Validation: E.D.C. and M.L.O.
 Formal Analysis: M.L.O.
 Investigation and data collection: D.M.T. and G.D.R-T.
 Resources: not applicable
 Data Analysis and Interpretation: D.M.B.
 Writing-Original Draft Preparation: D.M.T. and D.M.B.
 Writing-Review & Editing: E.D.C. and G.D.R-T.
 Supervision: G.D.R-T. and M.L.O.
 Project Administration: not applicable
 Final approval of the version to be published: D.M.T., G.D.R-T., E.D.C., D.M.B. and M.L.O.

ACKNOWLEDGMENTS

The authors gratefully acknowledge financial support from Coordenação de Aperfeiçoamento de Pessoal de Nível Superior – Brazil (CAPES) – Finance Code 001.

REFERENCES

1. Koo S.K., Moon J.S., Jung S.H., Mun M.J. A case of bilateral inferior concha bullosa connecting to maxillary sinus. *Braz J Otorhinolaryngol.* 2018; 84 (4): 526-528.
2. Koo S.K., Kim J.D., Moon J.S., Jung S.H., Lee S.H. The incidence of concha bullosa, unusual anatomic variation and its relationship to nasal septal deviation: A retrospective radiologic study. *Auris Nasus Larynx.* 2017; 44 (5): 561-570.
3. Braun H., Stammberger H. Pneumatization of turbinates. *Laryngoscope.* 2003; 113 (4): 668-72.
4. Mohebbi A., Ahmadi A., Etemadi M., Safdarian M., Ghourchian S. An epidemiologic study of factors associated with nasal septum deviation by computed tomography scan: a cross sectional study. *BMC Ear, Nose and Throat Disorders.* 2012; 12: 15.
5. Peric A., Baletic N., Sotirovic J. A case of an uncommon anatomic variation of the middle turbinate associated with headache. *Acta Otorhinolaryngol Ital.* 2010; 30 (3): 156-159.
6. Oliveira M.L., Tosoni G.M., Lindsey D.H., Mendoza K., Tetradis S., Mallya S.M. Influence of anatomical location on CT numbers in cone beam computed tomography. *Oral Surg Oral Med Oral Pathol Oral Radiol.* 2013; 115 (4): 558-64.
7. Bolger W.E., Butzin C.A., Parsons D.S. Paranasal sinus bony anatomic variations and mucosal abnormalities: CT analysis for endoscopic sinus surgery. *Laryngoscope.* 1991; 101 (1 Pt 1): 56-64.
8. Onerci M. *Endoscopic Sinus Surgery.* Ed. Kutsan Ofset, Ankara, Turkey, 1st edition. 1996: 22-23.
9. San T., Erdoğan B., Taşel B. Triple-divided concha bullosa: a new anatomic variation. *Case Rep Otolaryngol.* 2013: 342615.
10. Apuhan T., Yildirim Y.S., Simşek T., Yilmaz F., Yilmaz F. Concha bullosa surgery and the distribution of human olfactory neuroepithelium. *Eur Arch Otorhinolaryngol.* 2013; 270 (3): 953-7.
11. Cho J.H., Park M.S., Chung Y.S., Hong S.C., Kwon K.H., Kim J.K. Do anatomic variations of the middle turbinate have an effect on nasal septal deviation or paranasal sinusitis? *Ann Otol Rhinol Laryngol.* 2011; 120 (9): 569-74.
12. Yiğit O.1, Acioğlu E., Cakir Z.A., Şişman A.S., Barut A.Y. Concha bullosa and septal deviation. *Eur Arch Otorhinolaryngol.* 2010; 267 (9): 1397-401.
13. Uygur K.1, Tüz M., Doğru H. The correlation between septal deviation and concha bullosa. *Otolaryngol Head Neck Surg.* 2003: 129 (1): 33-6.
14. da Costa E.D., Verner F.S., Peyneau P.D., de Freitas D.Q., de Almeida S.M. Diagnosis of ethmoid sinolith by cone-beam computed tomography: case report and literature review. *Oral Radiol* 2019; 35 (1): 68-72.



Attribution (BY-NC) - (BY) You must give appropriate credit, provide a link to the license, and indicate if changes were made. You may do so in any reasonable manner, but not in any way that suggest the licensor endorses you or your use. (NC) You may not use the material for commercial purposes.