



CASE REPORT:

Management of Endo-Perio Lesion in a Tooth with an Unfavorable Prognosis: a Clinical Case Report with an 18-Month Follow-Up

Tratamiento de una lesión endo-perio-perio en un diente de pronóstico desfavorable:
informe de un caso clínico con seguimiento durante 18 meses

Micheline Sandini Trentin DDS, PhD, MSc¹ <https://orcid.org/0000-0001-5040-3578>
Felipe Gomes Dallepiane DDS, MSc student² <https://orcid.org/0000-0001-9677-9984>
Paola Serraglio Figueiredo DDS, PhD, MSc¹ <https://orcid.org/0000-0002-8314-4151>
Ana Luiza Becker DDS¹ <https://orcid.org/0009-0004-1416-6447>
Síndel Leocovick DDS student¹ <https://orcid.org/0000-0001-9255-8209>
Thais Mageste Duque DDS, PhD, MSc² <https://orcid.org/0000-0003-2265-8690>
João Paulo De Carli DDS, PhD, MSc¹ <https://orcid.org/0000-0002-4705-6226>
Jose Roberto Vanni DDS, PhD, MSc³ <https://orcid.org/0000-0002-4364-1567>

¹School of Dentistry, University of Passo Fundo, Passo Fundo, RS, Brazil.

²School of Dentistry, Federal University of Santa Catarina, Florianópolis, SC, Brazil.

³School of Dentistry, Meridional Dental Study Center, Passo Fundo, RS, Brazil.

Correspondence to: Felipe Gomes Dallepiane - dallepianefe@gmail.com

Received: 8-I-2024

Accepted: 8-IV-2024

ABSTRACT: The aim of this case study is to report a successful clinical case of an endo-perio lesion in a tooth with an initially unfavorable prognosis, followed up for 18 months. A male patient, public servant, non-smoker, without a history of diabetes, and married sought dental treatment in 1995 due to periodontal problems. He was then 40 years old and diagnosed with moderate to advanced periodontal disease. The initial treatment consisted of supra and subgingival scaling, followed by the extraction of teeth indicated for removal. After discharge, the patient adhered to a preventive periodic maintenance (PPM) program to control periodontal disease recurrence. In 2021, tooth 43 showed an unfavorable endo-perio lesion during a routine check-up. Despite treatment options, the patient opted for conservative treatment with endodontic and periodontal procedures. Simultaneously, PPM sessions were performed. The patient was monitored every six months, showing regression of periodontal pockets and significant improvement after 18 months. This case highlights the importance of patient adherence to PPM, demonstrating that a conservative approach and proper maintenance can lead to positive clinical outcomes even in cases with an initially unfavorable prognosis.



KEYWORDS: Combined modality therapy; Endodontics; Periodontal disease.

RESUMEN: El objetivo de este estudio de caso es informar de un caso clínico exitoso de una lesión endo-perio en un diente con un pronóstico inicialmente desfavorable, seguido durante 18 meses. Un paciente varón, funcionario público, no fumador, sin antecedentes de diabetes y casado buscó tratamiento odontológico en 1995 debido a problemas periodontales. Tenía entonces 40 años y se le diagnosticó enfermedad periodontal de moderada a avanzada. El tratamiento inicial consistió en un raspado supra y subgingival, seguido de la extracción de los dientes cuya extracción estaba indicada. Tras el alta, el paciente siguió un programa de mantenimiento periódico preventivo (MPP) para controlar la recidiva de la enfermedad periodontal. En 2021, el diente 43 mostró una lesión endoperio desfavorable durante una revisión rutinaria. A pesar de las opciones de tratamiento, el paciente optó por un tratamiento conservador con procedimientos endodónticos y periodontales. Simultáneamente, se realizaron sesiones de MPP. Se realizó un seguimiento semestral de la paciente, que mostró una regresión de las bolsas periodontales y una mejora significativa al cabo de 18 meses. Este caso pone de relieve la importancia de la adherencia del paciente al MPP, demostrando que un enfoque conservador y un mantenimiento adecuado pueden conducir a resultados clínicos positivos incluso en casos con un pronóstico inicialmente desfavorable.

PALABRAS CLAVE: Terapia de modalidad combinada; Endodoncia; Enfermedad periodontal.

INTRODUCTION

Factors such as microbial infections, periodontal tissue alterations, the complex anatomy of pulpal structures, trauma, and resorptions destroy periodontal and pulpal tissues when interconnected. Endo-perio lesions develop when such issues progress and affect both tissues (1-3).

The etiology and pathogenesis of endodontic/periodontal disease occur individually, as each tissue is affected differently through a chain of microorganisms, including *Actinobacillus actinomycetemcomitans*, *Eikenella corrodens*, *Fusobacterium nucleatum*, *Prevotella intermedia*, *Bacteroides forsythus*, *Treponema denticola*, *Porphyromonas gingivalis*, found in periodontal pockets, pulp tissue infections, and adjacent tissue alterations (3-4).

The physiological communication pathways between pulp and periodontal tissues occur through lateral/accessory canals, dentinal tubules, and

mostly the apical foramen. This region presents nerves and blood vessels that maintain tooth vitality, and an inflammatory process with pathogen migration begins when pulp debris, smear layers, or necrotic remnants extend beyond the pulp, affecting protective and supporting tissues of the periodontium. The reverse situation may also occur. Therefore, periodontal diseases with infections that produce by-products may affect healthy pulp tissues, contaminating them (1-2).

Endo-perio lesions are challenging clinical conditions due to the simultaneous involvement of periodontal and endodontic tissues, which may occur acutely or chronically (5). The difficult endo-perio lesion diagnosis may increase the likelihood of risks and errors in clinical practice. Clinical findings in patients with endo-perio lesions may vary and include deep periodontal pockets, bleeding on probing, suppuration, and bone resorption from inflammation around the affected teeth and their destruction (6).

The aim of this study is to present the diagnosis, clinical management and treatment of endo-perio lesions. Obtaining an accurate diagnosis and applying individual tests to each periodontal and endodontic lesion are fundamental to ensuring successful treatment.

CASE REPORT

This clinical case report followed the guidelines of the Preferred Reporting Items for Case Reports in Endodontics (PRICE) 2020 (7). Figure 1 summarizes the case management timeline. This study was submitted to and approved by the Research Ethics Committee of the University of Passo Fundo (CEP/UPF) (Opinion number 6.114.431) after patients signed an Informed Consent Form (ICF).

Patient A.C., male, public servant, in good systemic health, non-smoker, non-diabetic, and married, had his initial dental appointment on February 2, 1995, to address periodontal issues. In the initial clinical examination, the patient was 40 years old and diagnosed with moderate to advanced periodontal disease, referred by the current 2018 classification as Stage III, Subclassification B. The patient had most teeth in the mouth, except for lower and upper third molars. The periodontal clinical examination showed a significant amount of dental plaque, gingival bleeding, and pockets with probing depths greater than 5mm in most sites, with some reaching 7mm. The patient also had grade II mobility in lower incisors, grade III furcation involvement in tooth 37, and an endo-perio lesion along with grade II furcation involvement on the buccal aspect of tooth 27, both of which were indicated for extraction. Periodontal treatment was initiated based on this clinical diagnosis.

The initial periodontal treatment consisted of weekly supragingival scaling by arches,

targeted oral hygiene index (OHI), and subgingival scaling by sextants. Next, teeth 27 and 37 were extracted, and the patient began regular preventive periodic maintenance (PPM) to preserve the remaining teeth in the mouth.

In 2005, teeth 14 and 15 were extracted (Figure 2.A), and three months later, a maxillary sinus lift procedure was performed in the region corresponding to teeth 14 and 15 to place implants in the area. After the patient was discharged from the initial treatment, he understood that clinical periodontal therapy success depended on his adherence to regular PPM at specific intervals and frequency. In the first two years following the initial treatment, PPM was conducted every four months. Then, the interval was extended to six months to assess and control periodontal disease recurrence. In 2005, tooth 36 was individually evaluated because the patient complained of pain, and a significant bone loss was radiographically detected. An endo-perio lesion was diagnosed, and the tooth was referred for endodontic treatment. However, the six-month preservation did not reach the expected clinical success, leading to tooth extraction (Figure 2.B). The patient continued with PPM in the subsequent years. In 2006, implants were placed in the region of teeth 14, 15 (Figure 2.C), 36, and 37 (Figure 2.D, Figure 2.E, Figure 2.F).

In 2021, the patient returned to the dental office for his routine PPM, and tooth 43 showed an endo-perio lesion with an unfavorable prognosis (Figure 3.A). The vitality test yielded a negative response to cold. The patient received two treatment options: 1) Extraction of tooth 43, followed by local bone grafting and implant placement in the region; 2) Simultaneous periodontal and endodontic therapy in tooth 43, periodically observing the patient's healing response to the proposed treatment. Considering the severity of the condition, the ongoing effective patient/professional

plaque control, and the awareness of the significance of PPM for periodontal health and tooth maintenance, the patient chose the conservative treatment, even though he understood the risks of potentially losing this tooth in the future.

Tooth 43 was entirely asymptomatic, with significant mobility and slight purulent content drainage along the gingival sulcus on the distal aspect of the tooth. The vitality test yielded a negative response to cold. The radiographic evaluation showed extensive periodontal bone loss, particularly on the distal aspect of the tooth, extending into the periapical region and surrounding the entire periapical area (Figure 3.A).

Thus, a coronal opening was performed with a 1014 spherical bur, followed by rubber dam isolation and disinfectant penetration into the root canal using 2% chlorhexidine gel and copious saline irrigation. Next, an apex locator determined the root canal length confirmed with a digital radiograph, resulting in a 25mm working length (WL) (Figure 3.B).

Subsequently, the root canal was prepared with a single-use reciprocating endodontic instrument WaveOne Gold large #45/5 (Dentsply Maillefer, Ballaigues, Switzerland). Saline was the irrigating solution, and chemomechanical preparation used 2% chlorhexidine gel as an auxiliary chemical substance. A final irrigation step was performed after completing root canal preparation, alternating between 17% EDTA (Biodinâmica,

Ibiporã, PR, Brazil) with three cycles of 20 seconds each, using an EasyClean tip (Easy Equipamentos Odontológicos, Belo Horizonte, Brazil) also driven by reciprocating motion.

Next, the root canal was filled, drying with absorbent paper points, and using AHplus endodontic cement with a single calibrated cone with a 45 diameter adapted approximately 1.5mm short of the apical foramen (Figure 3.C). The final access cavity sealing used glass ionomer cement, and a final radiograph was taken. The patient was instructed to undergo subsequent radiographic and clinical follow-up appointments (Figure 3.D).

Simultaneously, PPM sessions were performed with root flattening and scaling under local anesthesia with 2% mepivacaine with 1:100,000 epinephrine, aided by Gracey mini-five 5/6 curettes and physiological saline for subgingival irrigation.

The patient underwent radiographic and clinical follow-up every six months, maintenance periodontal appointments, and lesion regression monitoring (Figure 3.E, Figure 3.F, Figure 3.G). Figure 3.H and Figure 3.I, shows the final clinical aspect of the patient after 18 months of clinical follow-up. The periodontal pocket regressed on the distal aspect: 5mm of probing depth and 3.5mm of gingival level; on the mesial aspect: 5mm of probing depth and 3mm of gingival level; and on the buccal aspect: 6mm of gingival level and 3mm of probing depth.

PRICE 2020 Flowchart

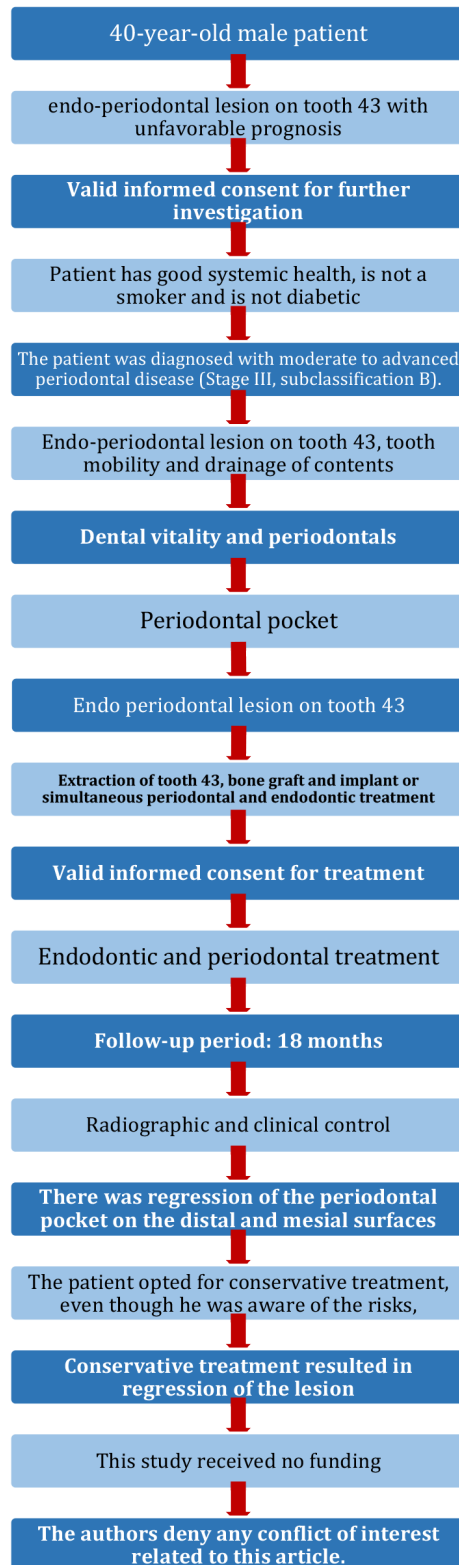


Figure 1. PRICE 2020 Flowchart.

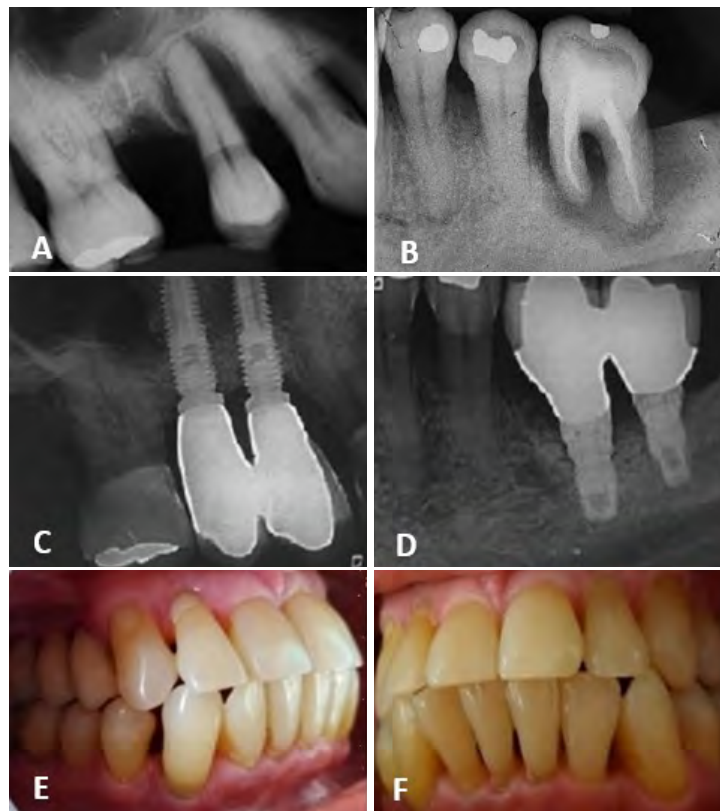


Figure 2. A: Extraction of elements 14 and 15; B: Extraction of element 36; C: Implants in regions 14 and 15; D: Implants in regions 36 and 37; E and F: Photographs after implant placement.

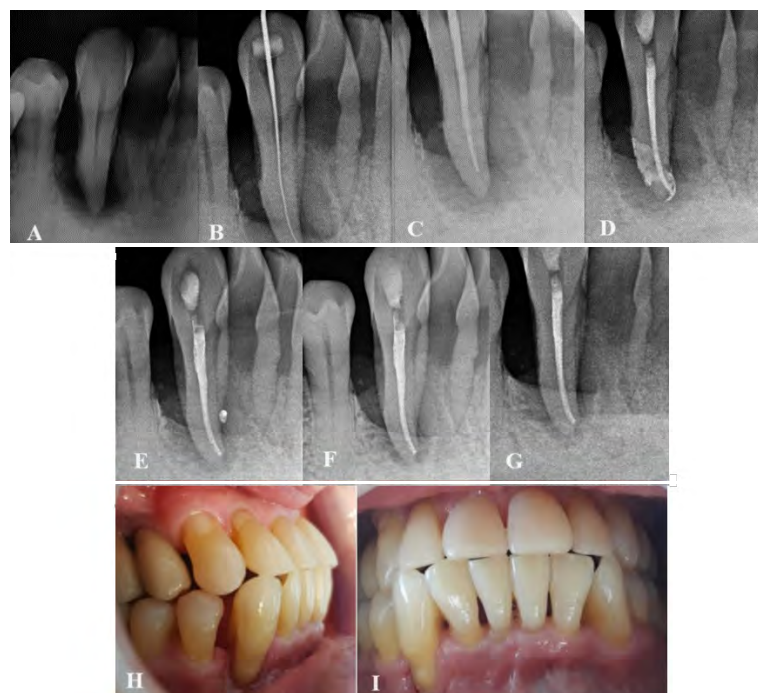

Figure 3. A: Element 43 with an extensive lesion; B: Working length; C: Master cone test; D: Obturation and final radiograph; E: 6-month follow-up; F: 12-month follow-up; G: 18-month follow-up; H and I: Current clinical photograph after endodontic and periodontal treatments.

DISCUSSION

This case report presented a patient with an endo-perio lesion in tooth 43 with an unfavorable prognosis who chose to attempt dental maintenance. Based on a 28-year follow-up, this case report aimed to track the progression of an endo-perio lesion, demonstrating a significant influence on the response to the proposed treatment. On the one hand, the findings showed that factors such as age, sex, dental arch, tooth position, and lesion origin significantly affected tissue healing outcomes. On the other hand, patient adherence to periodontal maintenance/support therapy and biofilm control was also crucial for dental preservation and oral health (8).

In case of ineffective lesion treatment and incomplete canal sealing, these may harbor bacterial necrotic debris that potentially causes lesion progression or endodontic reinfection (9). Therefore, effectively treating these lesions involves eliminating the microbial factor from the root canal system and periodontal pocket simultaneously and, if possible, restoring supporting bone structures that determine the prognosis of tooth function in the dentoalveolar system (10).

The pulp vitality test is the first step for clinically assessing endo-perio lesions (11). For the referred patient, the absence of vitality in the affected tooth suggested endodontic involvement. The periodontal examination of tooth 43 showed a pocket depth of 10mm on the distal, 5mm on the facial, 4mm on the lingual, and 7mm on the mesial aspects, serving as a pathway for exudate drainage. In these cases, bacteria from the periodontal pocket are the source of infection in the root canal. An originating hypothesis for the periodontal lesion was the lack of a distal contact point of the tooth, causing food debris accumulation and consequent periodontal tissue inflammation and bone loss.

Endo-perio lesions show the pulp and periodontium connected through the apical foramen. Hence, any pulp inflammation may extend to the periapical tissue, causing local periapical inflammation directly associated with bone resorption (12). The lesion was diagnosed as primary periodontal and secondary endodontic, meaning that the periodontal pocket progression caused pulp involvement through a lateral canal or primary apical foramen, infecting pulp tissues and requiring endodontic treatment (9). The vertical bone loss from the lesion also contributed to the decision for conservative treatment. Therefore, the endodontic treatment was performed appropriately and simultaneously with periodontal therapy, reducing the risk of introducing bacteria and their exudates and promoting better initial periapical tissue healing (13).

The present endo-periodontal lesion suggests an unfavorable prognosis for the single-rooted tooth, while Guo *et al.* (2022) concluded that this is highly related to the patient's oral hygiene maintenance quality, loss of attachment, degree of mobility, and crown-root ratio (3). Kim *et al.* (2008) state that endo-perio lesions often show a lower success rate than isolated endodontic lesions, even when aided by a dental microscope during treatment (4). Thus, Herrera *et al.* (2018) concluded that periodontitis patients present worse prognoses than those without the condition (5).

Therefore, the outcome was satisfactory despite the poor prognosis. Episodes of exudate suppuration through the periodontal pocket occurred after the endodontic treatment, leading to a new round of tooth scaling, resulting in an acceptable healing process. The patient's initial complaints were resolved, the gingival condition improved, and exudate drainage decreased during the clinical examination. Although clinical signs and symptoms usually reduce after treatment, the periapical lesion may persist for months or even years (14). The follow-up radiographs showed satisfactory healing with bone deposition in the

affected area, consistent with the findings of Fang *et al.* (2021), who concluded that adequate endodontic treatment combined with basic periodontal therapy significantly reduces pain, controls oral inflammation progression, improves periodontal health, and increases the retention rate of affected teeth in patients with endo-perio lesions (15).

CONCLUSION

The presented case successfully illustrates the treatment of a complex endo-perio lesion in tooth 43 using a multidisciplinary and conservative approach. Patient adherence to long-term preventive periodontal maintenance, along with good oral hygiene, was essential for preserving oral health for nearly 30 years. Despite previous challenges, such as extractions and implants, the decision to concurrently perform periodontal and endodontic treatment on tooth 43 was beneficial, promoting tooth preservation. Collaboration between periodontic and endodontic specialties, combined with meticulous treatment planning and patient education, contributed to a positive outcome.

This case highlights the relevance of an integrated approach in treating complex dental problems and the value of patient cooperation in achieving and maintaining oral health. Continuous follow-up and monitoring were crucial for assessing overall treatment success. These comprehensive case studies provide valuable insights into managing challenging conditions and demonstrate the potential for favorable outcomes. Further research in this field may enhance the understanding of best practices for similar cases in the future.

CONFLICT OF INTEREST

The authors have no conflicts of interest to declare.

PROTECTION OF HUMAN AND ANIMAL SUBJECTS

The authors declare that the procedures followed were in accordance with the regulations of the relevant clinical research ethics committee and with those of the Code of Ethics of the World Medical Association (Declaration of Helsinki). This study was submitted to and approved by the Research Ethics Committee of the University of Passo Fundo (CEP/UPF) (Opinion number 6.114.431) after patients signed an Informed Consent Form (ICF).

CONFIDENTIALITY OF DATA

The authors declare that they have followed their work center protocols on access to patient data and for its publication.

RIGHT TO PRIVACY AND INFORMED CONSENT

The authors have obtained the written informed consent of the patients or subjects mentioned in the article. The corresponding author is in possession of this document.

AUTHOR CONTRIBUTION STATEMENT

Conceptualization and design: M.S.T., F.G.D. and P.S.F.

Literature review: A.L.B. and S.L.

Methodology and Validation: M.S.T., F.G.D. and P.S.F.

Formal analysis: J.R.V.

Investigation and data collection: F.G.D. and P.S.F.

Resources: M.S.T.

Data analysis and interpretation: A.L.B. and S.L.

Writing-original draft preparation: T.M.D. and J.P.D.C.

Writing-review & editing: F.G.D.

Supervision: M.S.T., T.M.D. and J.P.D.C.

Project administration: J.P.D.C. and J.R.V.

Funding acquisition: M.S.T.

REFERENCES

1. Rotstein I., Simon J. The endo-perio lesion: a critical appraisal of the disease condition. *Endod Topics*. 2006; 13 (1): 34-56.
2. Singh P. Endo-perio dilemma: a brief review. *Dent Res J*. 2011; 8 (1): 39-47.
3. Guo J., Li Y., Lin X., Yang X., Shi W., Lu X. Prognostic Factors of Combined Periodontal and Endodontic Lesions: A Retrospective Study. *Contrast Media Mol Imaging*. 2022; 2022: e5042097.
4. Kim E., Song J.S., Jung I.Y., Lee S.J., Kim, S. Prospective clinical study evaluating endodontic microsurgery outcomes for cases with lesions of endodontic origin compared with cases with lesions of combined periodontal-endodontic origin. *J Endod*. 2008; 34 (5): 546-551.
5. Herrera D., Retamal-Valdes B., Alonso B., Feres M. Acute periodontal lesions (periodontal abscesses and necrotizing periodontal diseases) and endo-periodontal lesions. *J Clin Periodontol*. 2018; 45: S78-S94.
6. Takahashi K., Yamazaki K., Yamazaki M., Kato Y., Baba Y. Personalized Medicine Based on the Pathogenesis and Risk Assessment of Endodontic-Periodontal Lesions. *J Pers Med*. 2022; 12 (10): 1688.
7. Nagendrababu V., Chong B.S., McCabe P., Shah P.K., Priya E., Jayaraman J., Pulikkotil S.J., Setzer F.C., Sunde P.T., Dummer P.M.H. PRICE 2020 Guidelines for reporting case reports in Endodontics: A consensus-based development. *Int Endod J*. 2020; 53 (5): 619-626.
8. Manresa C., Sanz-Mirelles E.C., Twigg J., Bravo M. Supportive periodontal therapy (SPT) for maintaining the dentition in adults treated for periodontitis. *Cochrane Database Syst Rev*. 2018; 1 (1): CD009376.
9. Al-Fouzan K. A New Classification of Endodontic-Periodontal Lesions. *Int J Dent*. 2014; 2014: 919173.
10. Grudianov A.I., Makeeva M.K., Pyatigorskaya N.V. Modern concepts of etiology, pathogenesis and treatment approaches to endo-perio lesions. *Annals Russ Acad Med Scien*. 2013; 68 (8): 34-36.
11. Aksel H., Serper A. A case series associated with different kinds of endo-perio lesions. *J Clin Exp Dent*. 2014; 6 (1): 91.
12. Jakovljevic A., Miletic M., Nikolic N., Beljic-Ivanovic K., Andric M., Milasin J. Notch signaling pathway mediates alveolar bone resorption in apical periodontitis. *Med Hypotheses*. 2019; 124: 87-90.
13. Harrington G.W., Steiner D.R., Ammons W.F. The periodontal-endodontic controversy. *Periodontol 2000*. 2002; 30 (1): 123-130.
14. Friedman S. The prognosis and expected outcome of apical surgery. *Endod Topics*. 2005; 11 (1): 219-262.
15. Fang F., Gao B., He T., Lin Y. Efficacy of root canal therapy combined with basic periodontal therapy and its impact on inflammatory responses in patients with combined periodontal-endodontic lesions. *Am J Transl Res*. 2021; 13 (12): 14149-14156.