



Management of the transverse dimension (expansion) with microscrews (TADS)

Manejo de la dimensión transversal (expansión) por medio de microtornillos (TADS)

Lorenzo Puebla Ramos*

ABSTRACT

An effective alternative for the correction of the skeletal transverse maxillary deficiency is through expansion with the use of Microscrews or temporary skeletal anchorage devices (TADS). With this technique we can perform separation or disjunction of the midpalatal suture so the maxillary processes may separate to correct the transverse maxillary discrepancy in relation to the lower arch without dentoalveolar compensation. This means that pure bone expansion will be performed avoiding dental and/or alveolar compensations that may be deceiving regarding the amount of expansion required for the correction or alignment of the arches. Two or four microscrews are placed directly bilaterally on the palate so that afterwards an acrylic plate with expansion screw is cemented over the microscrews and this in turn rests or leans on the palatal mucosa avoiding direct contact with the tooth crowns to prevent dentoalveolar inclinations and thus perform a purely bony expansion. Hyrax and Hass-type expansion screws were used and rapid palatal expansion was performed with two activations per day. This type of expansion may be orthopedic or surgically assisted. The technique is simple, inexpensive, accurate and with a high rate of effectiveness, but definitely requires knowledge of anatomy, physiology and of course mechanical basis for treatment success.

RESUMEN

Una alternativa efectiva para la corrección de la deficiencia transversal esquelética en el maxilar superior, es por medio de la expansión con el uso de microtornillos o aditamentos de anclaje esquelético temporal (TADS). Con esta técnica podemos realizar la separación o disyunción de la sutura media palatina y los procesos maxilares se podrán separar para corregir el problema de discrepancia transversal del maxilar superior con respecto al inferior sin compensaciones dentoalveolares. Es decir que se realizará expansión puramente ósea, evitando tener compensaciones dentales y/o alveolares que pueden engañarnos en cuanto a la cantidad de expansión requerida para la corrección del alineamiento de las arcadas. Los microtornillos se colocan directamente sobre el paladar en forma bilateral, pudiendo ser dos o cuatro tornillos para que posteriormente se cimente una placa de acrílico con tornillo de expansión sobre los microtornillos y ésta a su vez descansa o se apoya sobre la mucosa palatina evitando tener contacto directo sobre las coronas de los dientes para evitar inclinaciones dentoalveolares, y de esta manera hacer una expansión puramente ósea. Se utilizaron tornillos de expansión tipo Hyrax y tornillos tipo Hass y se realizó expansión rápida palatina con dos activaciones por día. Este tipo de expansión puede ser ortopédica o quirúrgica asistida. La técnica es sencilla, económica, precisa y con un alto índice de efectividad, pero definitivamente se requiere de conocimientos de anatomía, fisiología y por supuesto de bases mecánicas para alcanzar el éxito del tratamiento.

Key words: Skeletal transverse deficiency, microscrews, Hyrax-type screw and Hass-type screw, disjunction of the suture.

Palabras clave: Deficiencia transversal esquelética, microtornillos, tornillo tipo Hyrax y tipo Hass, disyunción de la sutura.

INTRODUCTION

The use of accessories for intraosseous anchorage began before the middle of the last century and it was precisely Gainsforth¹ and Higley who made the first publication of the theme in the year 1945. Later, in 1969, they were used on a human mandible with class II elastics for retraction of the upper anterior sector, this procedure was performed by Linkow.^{2,3} In 1983 Creekmore and Eklund used microscrews in the anterior nasal spine for intrusive forces achieving more than 6 mm of intrusion.⁴ Bae and collaborators in 2002 recommended that the diameter of the ideal

microscrews should be 1.2 mm.^{5,6} The intraosseous temporary anchorage devices are increasingly being used in different dental specialties, but without doubt in orthodontics is where they have found their best use, despite the fact that microscrews (monocortical and bi cortical screws) are taken from the applied

* Orthognathic Surgery Professor of the «Federico Gómez» Children's Hospital of Mexico.

experiences in maxillofacial surgery.⁵ The term TADS was coined by Mah and Bergstrand from a publication in the United States with the purpose of standardizing the terminology.⁷ There is little information on the use of microscrews for the treatment of maxillary collapse and even more scarce are the bibliographic references on the subject.

The correction of the transverse maxillary deficiency occurs by means of the expansion of the same maxilla, and it may be orthopedic or surgically assisted. Orthopedic maxillary expansion was described first by Angell in a case report more than 145 years ago.^{8,9} Many years after, in the 60's, the subject was resumed by Andrew Hass¹⁰ who has remained until nowadays as, perhaps, the most recognized author that contributed the most to this kind of treatment, which he called transverse maxillary deficiency and that he performed in young orthodontic patients. The other mode to correct maxillary deficiencies is through surgery (surgically assisted expansion) which is performed in patients who have already completed their growth or who present early skeletal maturation or who are associated with some congenital defect, as craniosynostosis, linked to syndromes such as Crouzon syndrome, Apert, Carpenter, and Chotzen Pfeiffer.¹¹ However, today this concept of growth anticipation and bone maturation is more controversial than ever.

In 1959 Kole¹² recommended performing osteotomies in the cortical bone to diminish resistance to dentoalveolar movements. Converse and Horowitz¹³ recommended labial and palatal osteotomies in 1969. Perhaps the most recommended and used technique nowadays is that of Obwegeser¹⁴ and Steinhauser.¹⁵ The exact term that is known today for this technique is surgically assisted rapid palatal expansion («SARPE», by its acronym in english).¹⁶

Both the orthopedic and the surgically assisted expansion¹⁷ requires the use of an expansion screw and in both techniques, the criteria of rapid palatal expansion are applied which consists in the number of turns that have to be given to the screw perday¹⁸ depending on the specialist.

MAXILLARY EXPANSION THROUGH MICROSCREWS

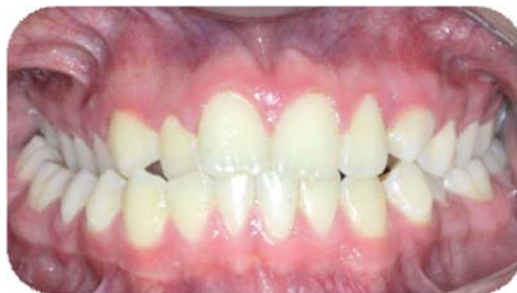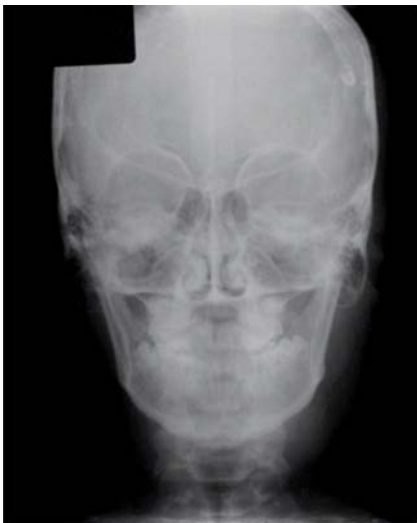The diagnosis and treatment of the transverse discrepancies has always been a point of controversy among orthodontists and the dental profession in determining the way, and particularly, the time to initiate the correction. The point of greatest confusion in the diagnosis of transverse issues is when an assessment is made only clinically and based solely

on the intermaxillary dental relationship, especially in the posterior area and emphasis is not made on the assessment of the maxillary skeletal width regarding the mandible. A clear example is when we have transverse skeletal discrepancies between the maxilla and the mandible without the existence of a crossbite or when there is a collapsed and deep palate without presenting a posterior cross bite and in addition there may be a low position of the tongue on the mandible. Another item of controversy is when do we have to or when is it possible to perform an orthopedic or expansion or what is the time limit in which we only have surgically assisted¹⁷ expansion as an alternative.

There are two fundamental aspects of the decision of when and how we perform maxillary expansion. The first is to assess the maturation status of the median palatal suture. It is well known that there are five stages of bone maturation: a) straight suture line, b) scalloped suture line, c) parallel, scalloped suture lines, d) complete fusion of the palatal bone with no evidence of suture and e) anterior fusion of the maxilla.¹⁹ The other important aspect is to assess peripheral bone density (central or axial densitometry and densitometry) in the area where our anchorage will be placed and we can do this in a simple and easy manner by means of the correct interpretation of a panoramic and/or periapical X-ray or in a much more accurate way but of a far higher cost to the patient by means of a computed tomography (CT).²⁰

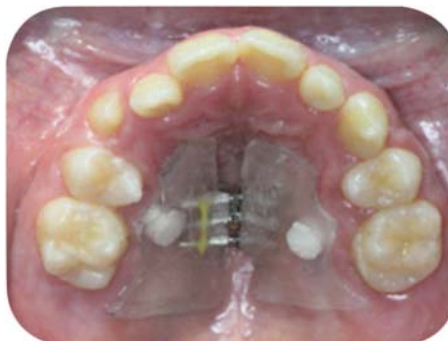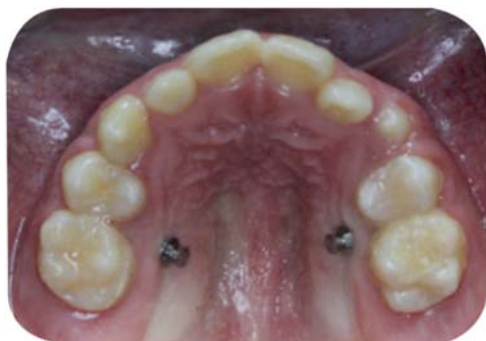Transverse problems are the first that should be cared for and/or solved in any type of dental treatment, but especially in orthodontic treatments. If we rank in order of importance the functional occlusal problems to resolve in the three planes of the space, we'd start out by solving the transverse problems, followed by the vertical and finally the sagittal ones. This does not mean that one is more important than the other, but if we take into consideration the fact that when solving transverse problems, if not doing so correctly, we may generate unwanted changes in the vertical and sagittal planes. This is why it is important to perform the diagnosis in the order in which occlusion problems will be dealt with (*Figures 1 and 2*).

Today the use of temporary anchorage devices (TADS), most commonly known as microscrews, is an indispensable tool for the management of orthodontic treatments in any form (preventive, interceptive, corrective, or surgical phase). Unfortunately there is a fairly high percentage of orthodontists at national and international level that do not use them, either by lack of preparation, anatomical ignorance, fear of any systemic disease of the patient or by deeply being rooted to the technique they handle or even economic



Figures 1 and 2.

The diagnosis should not be limited to the clinical aspect but also the radiographic one, in which the transverse skeletal relationships of the maxilla and the mandible should be measured. *Itate niae volesti*



Figures 3 and 4.

Shows the insertion sites for the microscrews and the acrylic plate. The plate is placed separate from the crowns of the posterior teeth crowns to avoid dentoalveolar compensation movements.

issues, etc. None of the abovementioned reasons justifies the reluctance to use microscrews, since there is sufficient information in books, articles, papers, research, workshops, courses, etc. to strengthen and grow the sufficient theoretical and practical knowledge to be able to confidently use and trust microscrews.

This article is based on a proposal for correcting transverse problems without neglecting vertical and, of course, sagittal control. It is handled on the basis of performing the expansion by means of mucoperiosteic anchorage, that is, by placing microscrews directly on the palate and an acrylic plate with an expansion screw that will rest on the palatal mucosa (*Figures 3 and 4*).

That is how the transverse problem is corrected, but most importantly, there is no dentoalveolar support to confuse us about whether the maxillary suture disjunction is really being made or if it is just a crown tilting and subsequent alveolar movement.²¹ Here we must be careful with vertical control since it may bring the mandible down and backwards, producing lip incompetence with the consequent chin

retrusion. Then at this point, the transverse problem is «corrected» but two additional effects are already present: (caused by us) the vertical and sagittal.

Microscrews are a very important tool that helps us to develop multiple procedures, in this case, expansion. First it is important to determine the type of desired expansion, the area where we want to expand and the amount of expansion to be performed.²² Due to the type of volume present in the maxilla, we must use screws according to the thickness of the mucosa where it will be placed. It can be approximately an 8 mm screw, as one of the disadvantages that we have is the basal bone type²⁰ that might become one of the reasons for failure in the retention of the implant. The quantities and sequence of activations of the screw will depend on the characteristics of each patient, but mainly on the orthodontist's clinical concepts and mechanics (*Figure 5*). Screws must have certain features such as a self-tapping and self-drilling configuration. Another feature is that the microscrew's head has a base in the form of a plate to avoid invagination into the palatal mucosa or local inflammation; the bigger the screw

head, the better for having greater support for the plate over the microscrew, i.e. we want a lot of support and less adhesion. An important recommendation to comply with the principles of this technique is that we must constantly monitor and palpate the buccal

area of the mucosa to check for root exposure of the posterior teeth thus causing some periodontal irreversible damage. Additionally, we must testify that the maxillary lateral segments truly are experiencing crossbite correction (*Figure 6*).

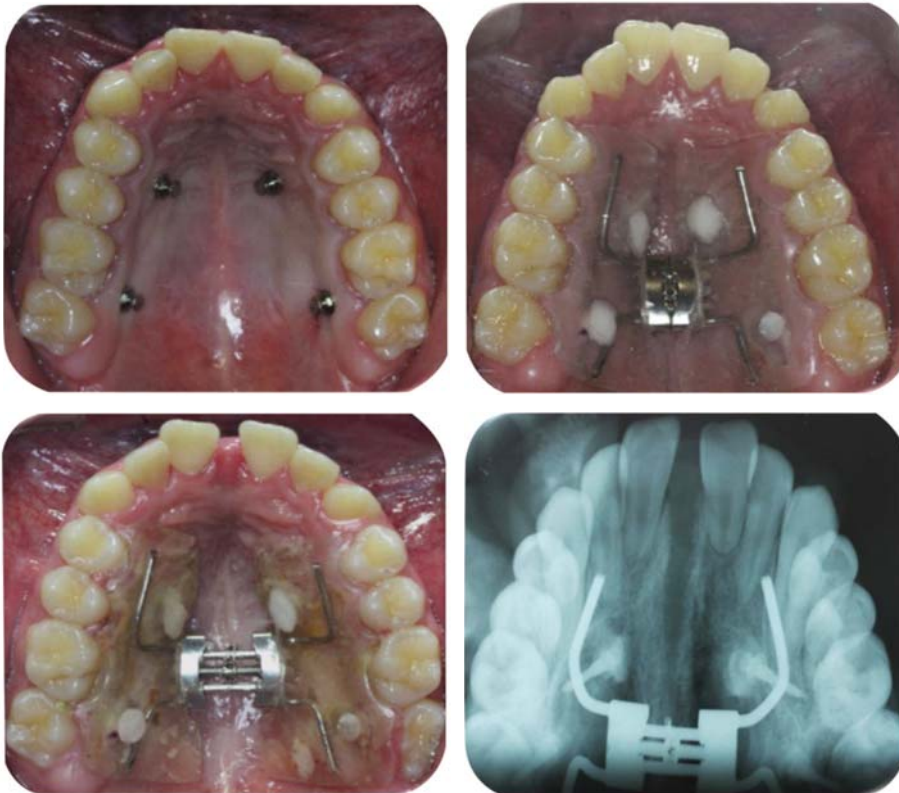


Figure 5.

The screws used were Hyrax-type but it may also be a Hass or any other kind of screw just as the amount of activations varies according to the operator's criteria. Notice that the acrylic is not over the clinical crowns.

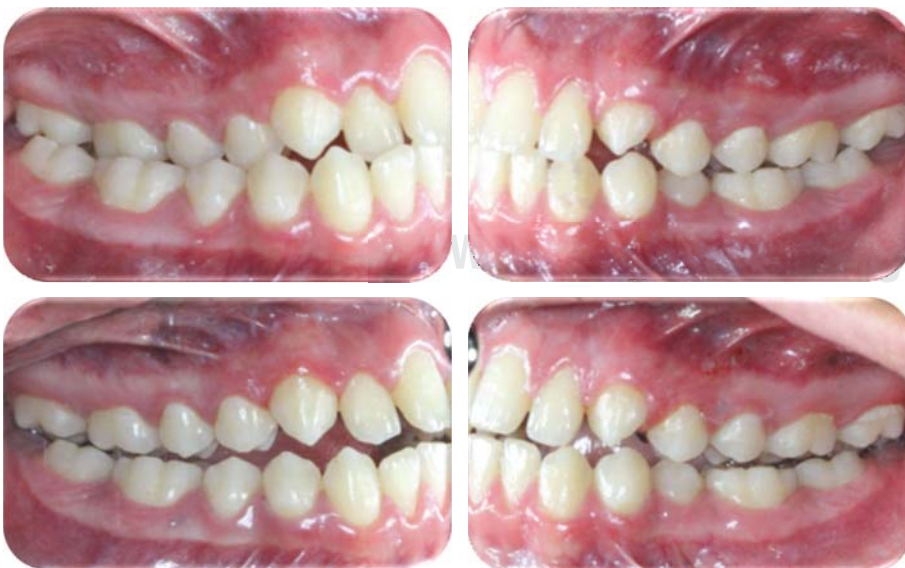

Figure 6.

True displacement of the maxillary lateral segments is present avoiding dental compensations that might give place to confusions regarding disjunction of the maxillary suture. Notice how the upper palatal cusps do not lower nor do the molar roots are exposed.

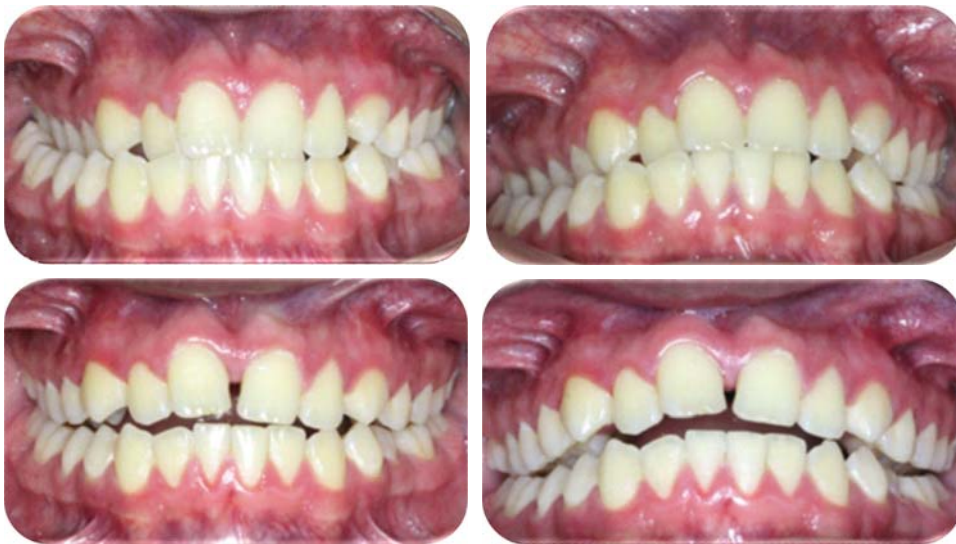

Figure 7.

Notice that the posterior crossbite is corrected but with no dental or alveolar inclinations that might generate occlusal and functional instability with a greater possibility of relapse.

Diagnosis and treatment of occlusal disorders have to be carried out in the three planes of space as it was once suggested by McHorris,^{23,24} because the treatment's result or failure will be in the same direction, therefore dental diagnosis should be performed without dental compensation. In *figure 7* the response of the expansion without any dentoalveolar effect such as labial inclinations and lowering of the palatal cusps really shows maxillary expansion due to the disjunction of the midpalatal suture;²⁵ a clinical sign is the presence of an anterior diastema, but of course this should be corroborated radiographically.

CONCLUSIONS

The correction of the transverse issues is without doubt the most complex vector to solve because if improperly diagnosed and treated, dental displacement may be generated as well as alveolar inclinations and periodontal damage, therefore, when speaking of the three planes of space in which the maxillo-mandibular relationship finds itself we must start our diagnosis and treatment plan precisely in the transverse dimension, then follow with the vertical and finally the sagittal. Shown here is an alternative solution to this problem which is effective and easy to perform. This technique may be applied both in orthopedic and surgically assisted expansions.

There is a huge responsibility in the use of the temporary anchorage devices (TADS), so it is required to have sufficient knowledge of anatomy, physiology, biomechanics, growth and development, bone architecture, etc., so that the results are favorable.

It is a relatively new technique, in progress of checking their results, so more research and clinical

publications are needed in this regard; so that it is a completely reliable and safe treatment alternative, both for the patient and the specialist. The results must be reviewed and verified by means of auxiliary diagnostic as scans, photos, study models, etc.

REFERENCES

1. Gainsforth BL. A study of orthodontic anchorage possibilities in basal bone. *Am J Orthod Oral Surg.* 1945; 31: 406-417.
2. Linkow LI. Implanto-orthodontics. *J Clin Orthod.* 1970; 4: 685-790.
3. Echarrri P, Kim TW, Favero L, Kim HJ. Ortodoncia & microimplantes. Técnica completa paso a paso. Ripano Editorial Médica. Madrid, 2007.
4. Creekmore TD, Eklund MK. The possibility of skeletal anchorage. *J Clin Orthod.* 1983; 17: 266-269.
5. Jae-Hyun Sung, Hee-Moon Kyung, Seong-Min Bae, Hyo-Sang Park, Oh-Won Kwon, McNamara JA Jr, Álvarez A. Microimplantes en ortodoncia. Editorial Providence. Argentina. 2007.
6. Bae SM, Park HS, Kyung HM, Kwon OW, Sung JH. Clinical application of micro-implant anchorage. *J Clin Orthod.* 2002; 36: 298-302.
7. Korrodi Ritto A. Skeletal anchorage with microimplants. Facies, Centro de Estudios Armonía Facial, Lda. Portugal. Mayo 2007.
8. Angell EH. Treatment of irregularity of permanent adult teeth. *Dent Cosmos.* 1860; 1: 540-544.
9. Timms DJ, Emerson C Angell (1822-1903). Founding father of rapid maxillary expansion. *Dent Hist.* 1997; (32): 3-12.
10. Haas AJ. The treatment of maxillary deficiency by opening the midpalatal suture. *Angle Orthod.* 1965; 35: 200-217.
11. Kinsman SL, Johnston MV. Craniosynostosis. In: Kliegman RM, Behrman RE, Jenson HB, Stanton BF et al. *Nelson textbook of pediatrics.* 19th ed. Philadelphia, Pa: Saunders Elsevier; chap 585, 2011; 12.
12. Kole H. Surgical operations on the alveolar ridge to correct occlusal abnormalities. *Oral Surg Oral Med Oral Pathol.* 1959; 12: 515-529.
13. Converse JM, Horowitz SL. Facial deformity. In: Horowitz SL, Hixon EH et al. The nature of orthodontic diagnosis. St. Louis: The C.V. Mosby Company; chap. 14. 1966; 249-283.

14. Obwegeser HL. Surgical correction of small or retrodisplaced maxillae. *Plast Reconstr Surg.* 1969; 43 (4): 351-365.
15. Steinhauser EW. Midline splitting of the maxillary osteotomy: A new technique. *J Oral Surg.* 1972; 30 (6): 413-422.
16. Suri L, Teneja P. Surgically assisted rapid palatal expansion: a literature review. *Am J Orthod Dentofacial Orthop.* 2008; 133: 290-302.
17. Pérez A, Ruíz R. Expansión rápida palatina asistida quirúrgicamente. *Revista Odontológica Mexicana.* 2008; 12 (4): 199-216.
18. Torres H. Tesis doctoral sobre efectos de la disyunción palatina sobre el flujo de aire nasal. Granada España. Universidad de Estomatología.
19. Angelieri F, Cevidanes LHS, Franchi L, Goncalves JR, Benavides E, McNamara JA Jr. Sao Paulo and Araraquara, Brazil. Ann Arbor, Mich, and Florence, Italy. *Am J Orthod Dentofacial Orthop.* 2013; 144: 759-769.
20. Merchán MS. Estudio densitométrico en maxilar y mandíbula con tomografía computarizada cuantitativa. Universidad Complutense de Madrid. 2013.
21. Tausche E, Hansen L, Hietschold V, Lagravère MO, Harzer WD. Germany, and Edmonton, Alberta, Canada. *Am J Orthod Dentofacial Orthop.* 2007; 131: 00.
22. Lagravère MO, Carey JP, Heo G, Toogood RW, Major PW. Edmonton, Alberta, Canada. Transverse, vertical, and anteroposterior changes from bone-anchored maxillary expansion vs traditional rapid maxillary expansion: A randomized clinical trial. *Am J Orthod Dentofacial Orthop.* 2010; 137: 304.e1-304.e12).
23. McHarris W. Occlusion, part I. *J Clin Orthod.* 1979; 13: 606-620.
24. McHarris W. Occlusion, part II. *J Clin Orthod.* 1979; 13: 684-702.
25. Isaacson R, Ingram AH. Forces produced by rapid maxillary expansion: H. Forces presented during treatment. *Angle Orthodont.* 1964; 34 (4): 261-268.

Mailing address:

Lorenzo Puebla Ramos

E-mail: lorenzopr_1@hotmail.com