



Treatment of irregular interdental spaces in a skeletal class II using a traditional approach: case report

Tratamiento de espacios interdentes irregulares en una clase II esquelética, mediante enfoque tradicional: presentación de un caso

Evelyn Carrera Garrido,* Gabriel Sáez Espínola[§]

ABSTRACT

An apparently healthy 12-year-old male patient attended the clinic with the following reason for consultation: «I want to close the spaces between my teeth». Upon clinical and radiographic examination, the patient appeared symmetric, dolichocephalic, hyperdivergent with a skeletal class II malocclusion due to maxillary protrusion. The intraoral analysis revealed an Angle molar and canine class II and irregular interdental spaces in the upper central and lower anterior region as well as a deep overbite. Orthodontic treatment consisted of phase I: leveling and alignment with NiTi 0.012", NiTi 0.014", and NiTi 0.016" upper and lower archwires; phase II: correct the deep bite through 0.016" x 0.016" SS reverse curve archwires with CII intermaxillary elastics; phase III: closed elastomeric chain for closing the central diastema and the spaces in the lower anterior segment. Finally, phase IV, which consisted of: bracket repositioning, and fixed upper and lower retention. Satisfactory results were obtained: facial, dental, aesthetic and functional.

Key words: Irregular interdental spaces, skeletal class II.

Palabras clave: Espacios interdentes irregulares, clase II esquelética.

RESUMEN

Se presenta paciente de sexo masculino de 12 años 6 meses de edad, aparentemente sano, quien a la consulta reporta «quiero que me cierren los huecos». Al análisis clínico y radiográfico aparentemente simétrico, braquicefálico, hiperdivergente, clase II esquelética por protrusión maxilar, intraoralmente presenta clase II canina y molar de Angle derecha e izquierda; presencia de espacios interdentes irregulares en el segmento central superior y anteroinferior y mordida profunda. El tratamiento ortodóntico consistió en fase I: nivelación y alineación, NiTi 0.012", 0.014" y 0.016" superior e inferior. La fase II: corregir la mordida profunda 0.016" x 0.016" SS curva inversa con elásticos intermaxilares CII. La fase III: cierre de diastema central y en segmento anteroinferior con uso de cadena cerrada. Por último, la fase IV, que consistió en: re-nivelación con brackets, y retención fija superior e inferior. Se lograron resultados satisfactorios: faciales, dentales, estéticos y funcionales.

INTRODUCTION

Today, cosmetic appearance of the teeth is part of a global image, interacting closely with facial esthetics. Since a nice smile is governed in large part by symmetry the specialist has an important role in resolving the closure of irregular spaces, giving the patient a solution through orthodontic treatment.

Irregular spacing of the midline are considered diastemas that vary in magnitude between the mandibular or maxillary central incisors in fully erupted teeth.¹

Bishara (1972) described the diastema of the midline as a common form of malocclusion, identified by a space between the upper central incisors and rarely between lower central incisors.²

Diastemas were defined as «a space greater than 0.5 mm between the proximal surfaces of teeth».³

Baume (1950) helped to clarify the concept of irregular spaces in the deciduous dentition stating that they are congenital and not a product of development. After evaluating series of models of children during the eruption period of the permanent incisors, he concluded that in arches with spaced deciduous

* Graduate.

§ Teacher.

Department of Orthodontics of the Postgraduate Studies and Research Division of the Odontology Faculty, UNAM.

© 2017 Universidad Nacional Autónoma de México, [Facultad de Odontología]. This is an open access article under the CC BY-NC-ND license (<http://creativecommons.org/licenses/by-nc-nd/4.0/>).

This article can be read in its full version in the following page:
<http://www.medigraphic.com/ortodoncia>

incisors (type I), properly aligned anterior teeth would usually erupt; while in arches with deciduous incisors without spaces (type II), approximately 40% would present anterior crowding.⁴

DIAGNOSIS AND TREATMENT

Diastemas may be congenital or acquired and in their etiology they may involve several factors, such as: low insertion of the labial frenum, excessive width of the dental arch, asymmetric teeth, trauma, periodontal disease, tooth mobility, tongue habit-suction, tooth agenesis, bruxism, deep bite, mouth breathing, open bite, iatrogenic orthodontic or orthopedic treatments, and collapse of posterior bite.⁵

There are several techniques available to perform the closure of irregular spaces; using various materials among which are: closed coil springs, elastomeric chains, different types of wire and cables with different cross sections. In the stage of retention, if the case is not eliminated it will be difficult to maintain the space closed. Thus, in young patients tongue reminders should be used for the lingual activity and in adults immediate retainers should be placed, with permanent use, such as a fixed retainer covering from canine to canine uniting the six anterior teeth.⁶

The objective of this case report is to present a case of irregular interdental spaces in the anterior region of the maxilla and the mandible treated traditionally.

CASE REPORT

Male patient of 12 years 6 months of age, student, attended the Orthodontics Clinic of the Division of Postgraduate Studies and Research in the Faculty of Dentistry of the UNAM. The patient presented for consultation and referred the following: «I want to close the gaps». Upon interrogation, the patient did not mention any pathologic data. Extraoral examination was performed and it was observed: a brachicephalic patient with an increase in proportion of the middle third (37%), normal capillary insertion as normal insertion of the auricles. The patient had a concave facial profile, semi-straight nose with rounded tip and presence of mentolabial fold.

Upon the initial intraoral evaluation, the presence of irregular spacing in the upper and lower anterior region was observed along with deep bite, a 3 mm overbite and a 4 mm overjet. In the lateral intraoral photographs, there was a bilateral canine and Angle molar class II. In the upper occlusal photograph we observed an ellipsoidal arch form, tooth #15 palatally displaced and tooth #23 labially positioned. In the

lower arch, a parabolic arch form may be observed. Tooth #33 was in a lingual position and there were irregular interdental spaces in the lower anterior segment.

The lateral headfilm revealed a skeletal class II due to retrognathism and inclinations of the upper and lower incisors.

In the initial panoramic X-ray, 32 permanent teeth may be noted, including upper and lower third molars, and a normal crown/root ratio (*Figures 1 to 4*).

Goals of treatment

As a facial objective, we tried to improve the profile and lip position. Functionally, to maintain temporomandibular joint health. The dental objectives were: to close the interdental spaces in the upper and lower anterior segments, improve the deep bite, achieve bilateral molar and canine class I, correct dental rotations and inclinations, maintain dental midlines aligned, decrease the overbite- and overjet and coordinate arches.

Treatment plan

Orthodontic treatment was performed with 0,022" Roth appliances. Phase I consisted in: leveling and alignment, 0.012" NiTi, 0.014" NiTi and 0.016" NiTi upper and lower archwires. Phase II consisted in: correct the deep bite 0.016" × 0.016" SS reverse curve archwire with CII intermaxillary elastics. Phase III was: closure of central diastema and spacing in the anterior segment with use of closed chain. Finally, phase IV, which consisted in: re-leveling with brackets, and upper and lower fixed retention (*Figure 5*).

RESULTS

The extraoral clinical examination revealed that facial balance and harmonious profile, with a broad smile was achieved.

In the final intraoral evaluation, closure of the central diastema in the upper anterior segment may be observed as well as in the lower anterior segment. The anterior bite improved, with better overbite and overjet, alignment, leveling with good dental harmony and coincident midlines. Intraoral photographs in the right and left side show a bilateral molar and canine class I, paraboloid arch forms with a good intercuspation.

The final lateral headfilm revealed an adequate skeletal relationship, hyperdivergency, the interincisal angle opened, the upper and lower incisors are found within normal values.

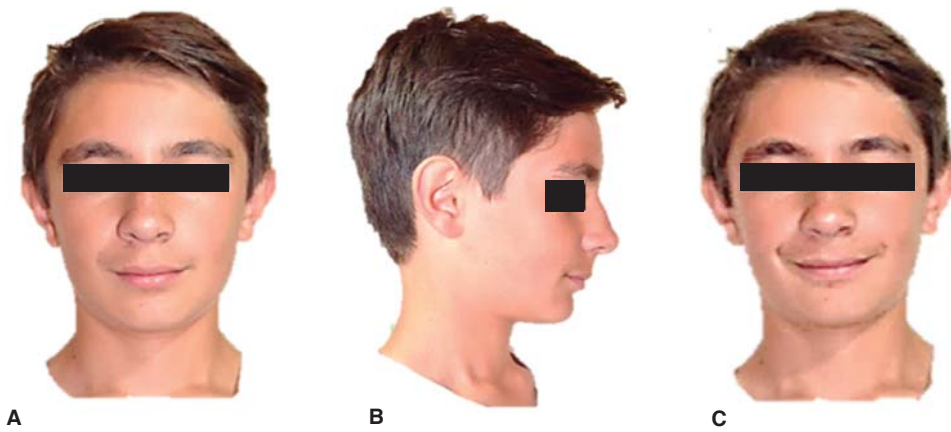

Figure 1.

Initial facial evaluation. **A.** Front, **B.** Profile, and **C.** Smile.

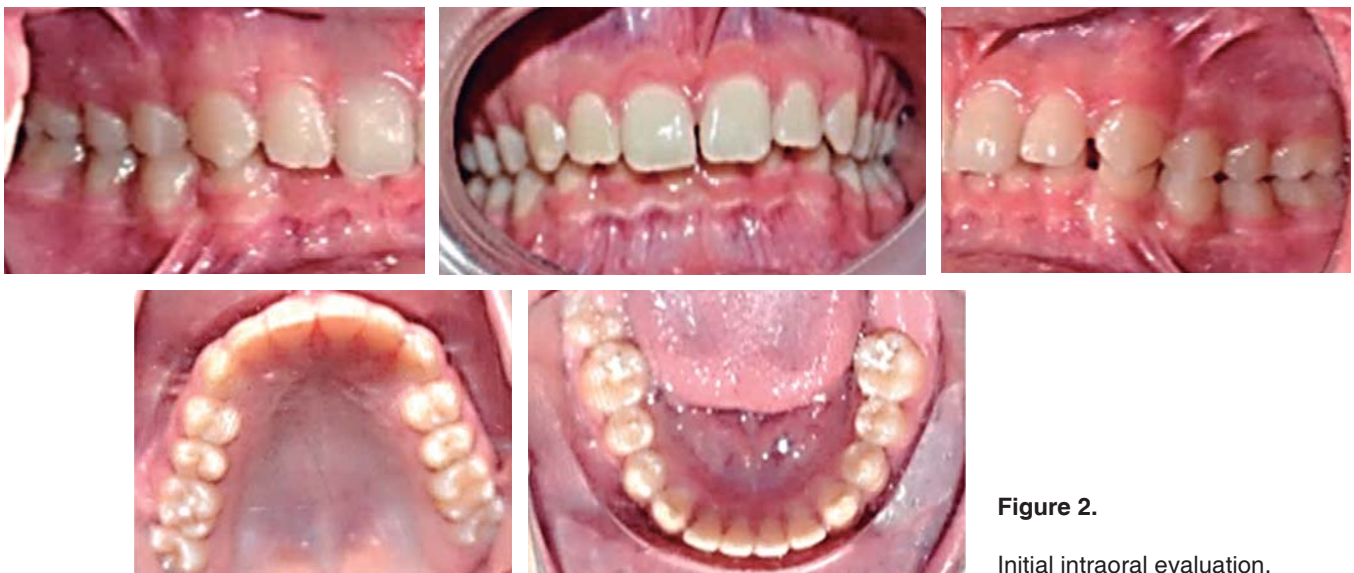

Figure 2.

Initial intraoral evaluation.

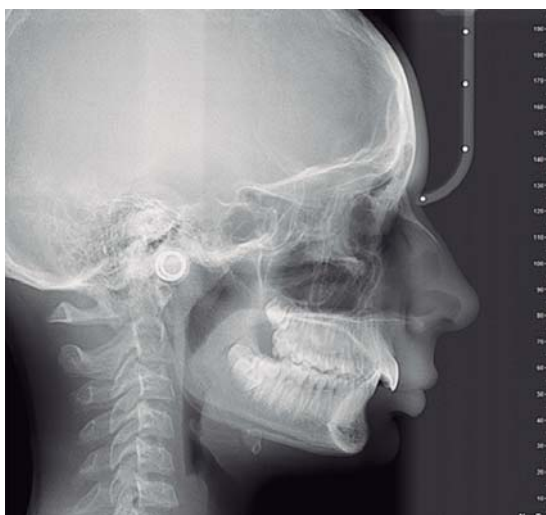

Figure 3. Initial lateral headfilm.

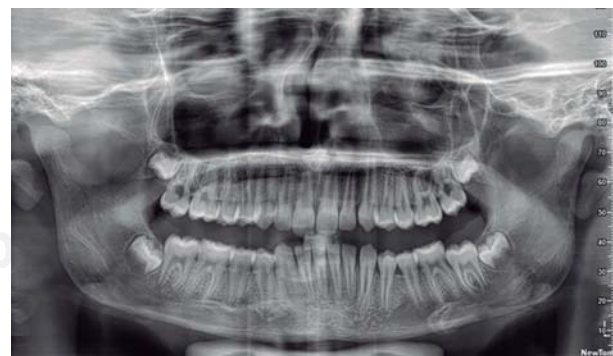

Figure 4. Initial panoramic radiograph.

In the final panoramic X-ray end an acceptable root parallelism may be observed. Upper and lower fixed retention was placed (*Figures 6 to 9*).

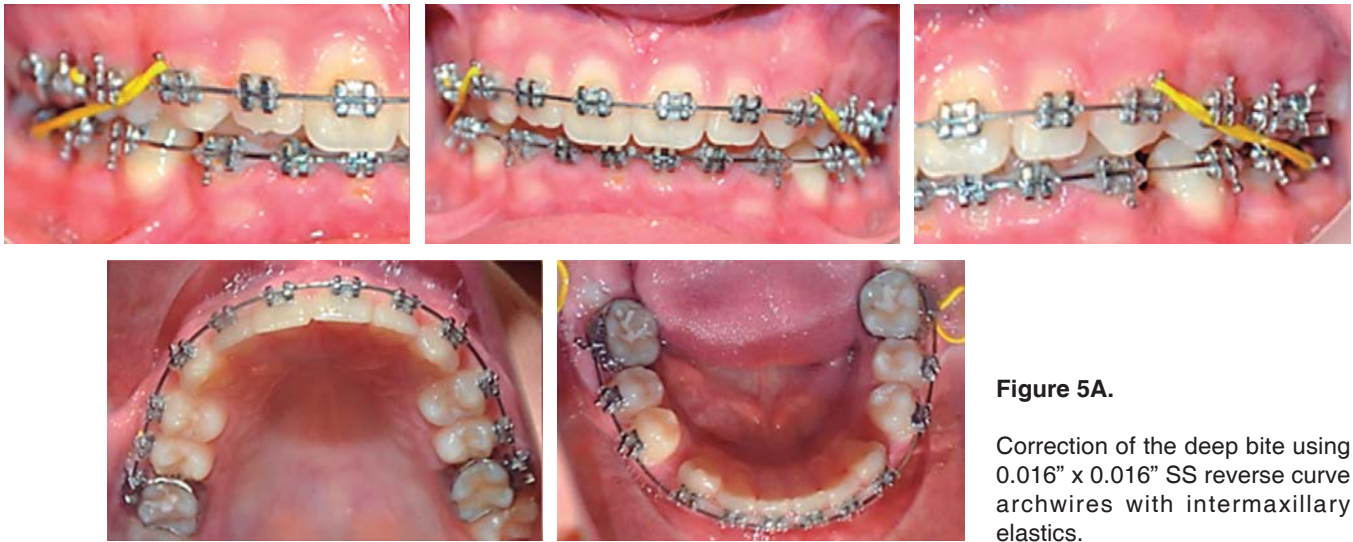

Figure 5A.

Correction of the deep bite using 0.016" x 0.016" SS reverse curve archwires with intermaxillary elastics.

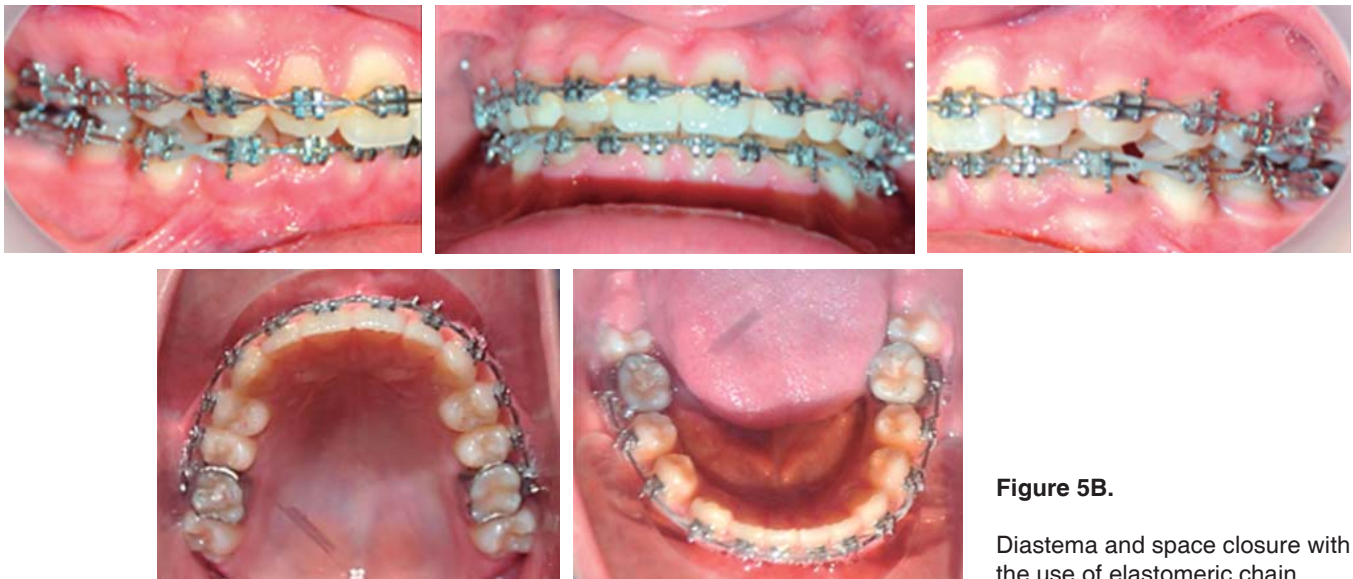

Figure 5B.

Diastema and space closure with the use of elastomeric chain.

DISCUSSION

Diastema is a common aesthetic complaint of patients that affects their quality of life to a certain extent. The appearance of the diastema of the midline as part of normal dental development makes it difficult for the specialists to decide whether or not to intervene at an early stage. There are many techniques available in the field of orthodontics to close the space of the midline using several materials among which we can find: closed coil springs, elastomeric chains, different types of wire and cables with different cross sections.

This study makes reference to the traditional space closure between teeth in the upper and lower anterior segment, restoring the function and aesthetics.

Mulligan⁵ studied mechanics for diastema closure and long-term stability.

The effective treatment of irregular interdental spaces requires a correct diagnosis of the etiology that includes medical and dental records; clinical and radiographic examinations and assessments of tooth size.^{6,7}

We agree with Graber⁸ who concludes that traditional closure of irregular spaces with rectangular wire causes a bodily movement of the central incisors

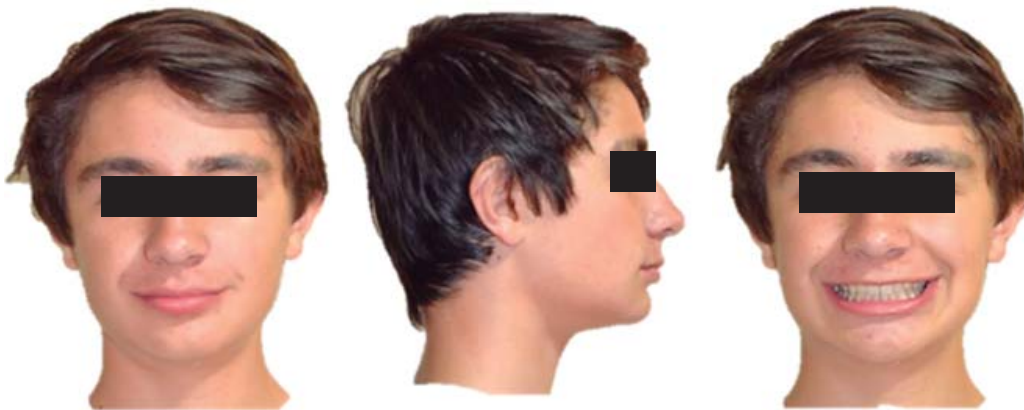

Figure 6.
Final facial photographs.

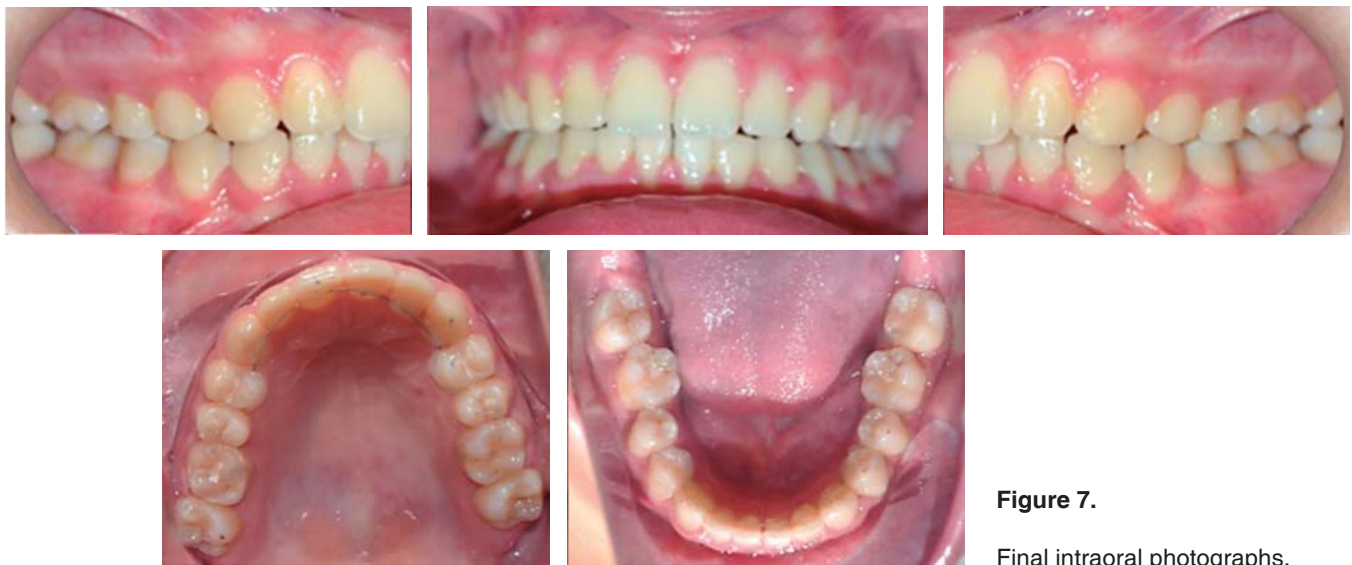

Figure 7.
Final intraoral photographs.

resulting in root parallelism and reducing undesirable movements.

The results of the present study agree with those from Zhang YF,⁹ who claim that closing irregular interdental spaces improves the aesthetic expectations of the patient due to his or her motivation during orthodontic treatment. Treatment should be planned properly, based on the required orthodontic movements, the stability of these changes and if the likely aesthetic result is going to meet the patient's expectations.

CONCLUSIONS

Performing a correct diagnosis will result in an effective treatment plan guiding the specialist to take a wise decision for the benefit of the patient. In this case,

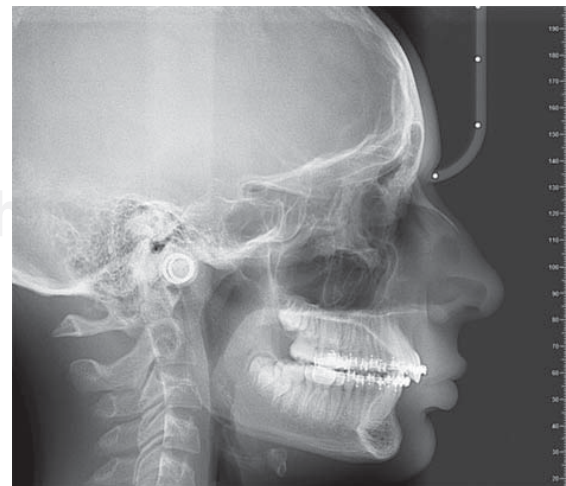

Figure 8. Final lateral headfilm.

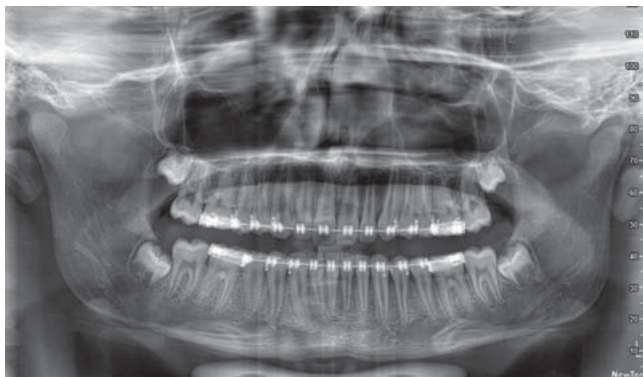


Figure 9. Final panoramic radiograph.

closure of irregular interdental spaces was achieved as well as dental Class I molar relationship without undesirable effects.

Designing correctly the retainer will achieve control in tooth stability.

REFERENCES

1. Sondankar AP, Gulve N, Patani S. "M" Mechanics for the management of maxillary Midline Diastema. *J Ind Orthod Soc.* 2013; 47 (4): 229-231.
2. Bishara SE. Management of diastemas in orthodontics. *Am J Orthod.* 1972; 61 (1): 55-63.
3. Nainar SM, Gnanasundaram N. Incidence and etiology of midline diastema in a population in south India (Madras). *Angle Orthod.* 1989; 59 (4): 277-282.

4. Baume LJ. Physiological tooth migration and its significance for the development of occlusion; the biogenesis of overbite. *J Dent Res.* 1950; 29 (4): 440-447.
5. Mulligan TF. Diastema closure and long-term stability. *J Clin Orthod.* 2003; 37 (10): 560-574.
6. McVay TJ, Latta GH Jr. Incidence of the maxillary midline diastema in adults. *J Prosthet Dent.* 1984; 52 (6): 809-811.
7. Gass JR, Valiathan M, Tiwari HK, Hans MG, Elston RC. Familial correlations and heritability of maxillary midline diastema. *Am J Orthod Dentofacial Orthop.* 2003; 123 (1): 35-39.
8. Graber TM. Panoramic radiography in orthodontic diagnosis. *Am J Orthod.* 1967; 53:799-821.
9. Zhang YF, Xiao L, Li J, Peng YR, Zhao Z. Young people's esthetic perception of dental midline deviation. *Angle Orthod.* 2010; 80 (3): 515-520.

RECOMMENDED READINGS

- Sullivan TC, Turpin DL, Artun J. A postretention study of patients presenting with a maxillary median diastema. *Angle Orthod.* 1996; 66 (2): 131-138.
- Gkantidis N, Kolokitha OE, Topouzelis N. Management of maxillary midline diastema with emphasis on etiology. *J Clin Pediatr Dent.* 2008; 32 (4): 265-272.
- Richardson ER, Malhotra SK, Henry M, Little RG, Coleman HT. Biracial study of the maxillary midline diastema. *Angle Orthod.* 1973; 43 (4): 438-443.

Mailing address:

Evelyn Carrera Garrido

E-mail: eccg1617@gmail.com