

Clinical case

Aggressive pediatric hip fibromatosis with severe joint destruction. A case report

Ruiz CO,* Avila MZ,** López AD,*** Garzón MDM,**** Isunza AR*****

National Pediatric Institute

ABSTRACT. Fibrous or desmoid tumors are grouped under the term fibromatosis; there are several groups; the pediatric aggressive form is rare, especially the pelvis and/or hip presentation. This causes a variable degree of destruction of the surrounding tissues. It is a diagnosis by exclusion and histopathologic testing; treatment is always surgical and conservative treatment is indicated only for special locations and/or patient conditions. This article reports a case of aggressive pediatric hip fibromatosis with severe joint destruction, as well as the work-up and management protocol followed at the National Pediatrics Institute Pediatric Orthopedics Service to approach bone tumors. No cases similar to this one have been reported.

Key words: fibromatosis, neoplasm, hip, joint, child, diagnosis, histology, treatment, guide.

RESUMEN. Los tumores fibrosos o desmoides se agrupan en el término de fibromatosis, existiendo varios grupos, siendo la forma agresiva infantil rara, aún más en su presentación en pelvis y/o cadera. Esta produce destrucción de los tejidos circundantes en grado variable. Su diagnóstico es por exclusión y comprobación histopatológica, el tratamiento es siempre quirúrgico, siendo conservador únicamente en localizaciones especiales y/o condiciones propias del paciente. En este artículo reportamos un caso de fibromatosis agresiva infantil en cadera con destrucción grave de la articulación, no existiendo hasta el momento un reporte similar, así como el protocolo de estudio y manejo que se sigue en el servicio de Ortopedia Pediátrica del Instituto Nacional de Pediatría para abordar los tumores óseos.

Palabras clave: fibromatosis, neoplasia, articulación, cadera, niño, diagnóstico histológico, protocolo, tratamiento.

Introduction

Many fibrous proliferative lesions relapse but do not metastasize. As a group, they are known as fibromatosis.^{1,2,3} A keloid is a benign skin tumor in which the repair process after a lesion does not stop spontaneously.¹⁻⁵ Irradiation fibromatosis, as its name suggests, is a lesion that may appear after soft tissue radiotherapy.¹⁻³ The most common fibromatoses are the plantar and the palmar ones; the latter are associated with Dupuytren's contracture, with adults being the most commonly affected group; plantar fibromatosis affects the medial half of the middle aspect of the plantar fascia and is characterized by tenderness; in both of them the treatment is surgical and consists of *en bloc* resection to avoid relapses.¹⁻⁵ Peyronie's disease, a fibrous proliferative lesion affecting the penis, sometimes occurs in patients with plantar or palmar fibromatosis. Desmoid tumors (aggressive fibromatosis, musculofascial fibroma-

Nivel de evidencia: IV (Act Ortop Mex, 2010)

* Orthopedic Surgeon, Pediatric Orthopedist graduated from the National Pediatrics Institute.

** Medical Radiologist, adscribed to Imágenes Diagnósticas, Mazatlán.

*** Orthopedic Surgeon, staff physician, Pediatric Orthopedics Service, National Pediatrics Institute.

**** Orthopedic Surgeon, staff physician and assistant professor of the Pediatric Orthopedics University Course, National Pediatrics Institute.

***** Orthopedic Surgeon, head of the service and titular professor of the Pediatric Orthopedics University Course, National Pediatrics Institute.

Please address all correspondence to:

Dr. César Ruiz Osuna

Av. Rafael Buelna Núm. 198, Hacienda Las Cruces, CP 82126, Cons. 513, Polimédica Sharp-Mazatlán; Nextel 62*212364*2, Movil 669 12 10 582, E-mail: c.ruiz.o@hotmail.com

Este artículo puede ser consultado en versión completa en <http://www.medigraphic.com/actaortopedica>

tosis, grade I fibrosarcomas of the desmoid type) are local aggressive lesions originating in the connective tissues and infiltrating the neighboring tissues, with a marked trend to persist.¹⁻⁵ Even though most authors consider them as benign, Posner et al. consider them as malignant.⁵ These lesions are most frequent in the anterior abdominal wall of women who have had children; those in other locations are frequently called extraabdominal desmoids.^{1-3,5} Extraabdominal desmoids are most frequent in the scapular girdle, the arm, the thigh, the neck, the pelvis, the forearm and the popliteal fossa.¹⁻⁴ The natural history of untreated lesions is usually a slow and inexorable growth with invasion of the contiguous structures.^{1,2,4,5} However, there may be spontaneous regressions; in a published series, 29% of the patients treated with partial excision did not have any signs of disease in the last follow-up. Desmoid tumor regression has been attained with indomethacin and ascorbic acid, tamoxifen and testolactone, and chlorothiazide. Desmoid tumors may appear beside colon polyps, osteomas and epidermal cysts in Gardner syndrome.²⁻⁵ The juvenile aponeurotic fibroma is a rare characteristic lesion found in small children, usually in the hand or feet, with a definitive trend towards relapse after removal.¹⁻⁴ The elastofibroma of the back is a benign tumor occurring in old individuals, it is located anterior to the lower aspect of the scapula, beside the gracilis and rhomboid muscles.^{1,2,6} Progressive fibrous myositis is a generalized, primary and rare muscle disease that appears in childhood and may be the initial phase of progressive ossifying myositis.^{1,2,3,4,5} Congenital generalized fibromatosis is a possibly familial disease, extremely rare, that produces stillbirth or a quick death after birth.^{1,2,5} Several proliferative fibrous tumors have been defined during infancy, such as: infantile dermal fibromatosis, fibrous hamartoma of childhood, diffuse infantile fibromatosis, and some varieties of aggressive infantile fibromatosis.¹⁻⁵ Any of the different types of fibromatosis warrant the same type of treatment, consisting of *en bloc* resection with free margins to prevent relapses from occurring.¹⁻⁶

Clinical case

Female, 9-year old patient, student, catholic, can read and write, born and living in Xalapa, Veracruz; her relevant family history includes her maternal grandfather who died of prostate cancer; allergic to trimetoprim-sulphamethoxazole, varicella zoster at 7 years of age, incomplete fracture of the left radius and ulna a year ago, her current condition began on April 14, 2009 with pain, redness, local heat and functional disability of the right hip; she was given NSAIDs for tendinitis of the short pelvic rotators; on April 21, 2009 the diagnosis of septic arthritis was made and she underwent hip arthrotomy with a posterior approach, and was on several antimicrobial regimens for 75 days; the patient has been unable to stand on both feet and walk, she presented at the Shriner's Hospital in Mexico, where she was referred to the INP for diagnosis and

treatment. She was admitted at the pediatric orthopedics service with diagnosis of bone neoplasia of the right hip; the physical exam reported a conscious oriented female, with a Glasgow score of 15, Tanner 2, forced attitude, robust body habitus, a motor ASIA score of 100, ASIA and Frankell E, incapable of bipedestation due to the right pelvic limb, claudicating and assisted gait at the expense of the right pelvic limb, and pelvic swing at the expense of the right pelvic limb (*Figure 1*). Positive right Thomas (*Figure 2*), positive right Trendelenburg (*Figure 3*), negative

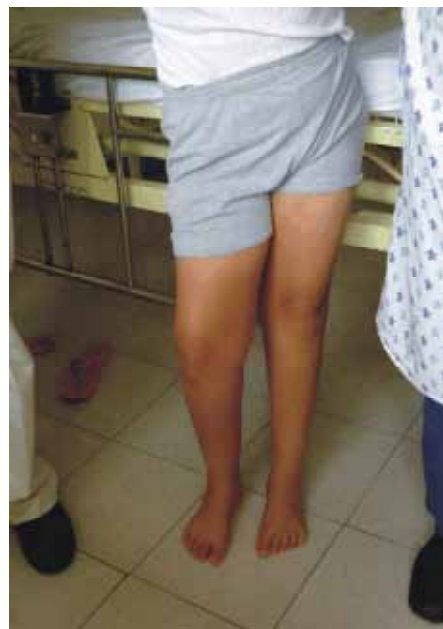

Figure 1. Pelvic swing.

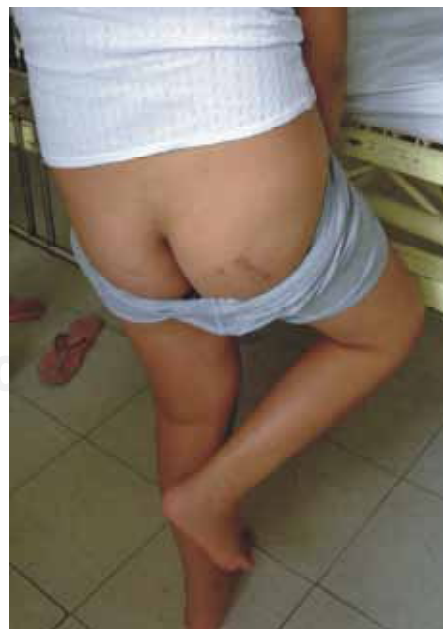

Figure 2. Right Trendelenburg.

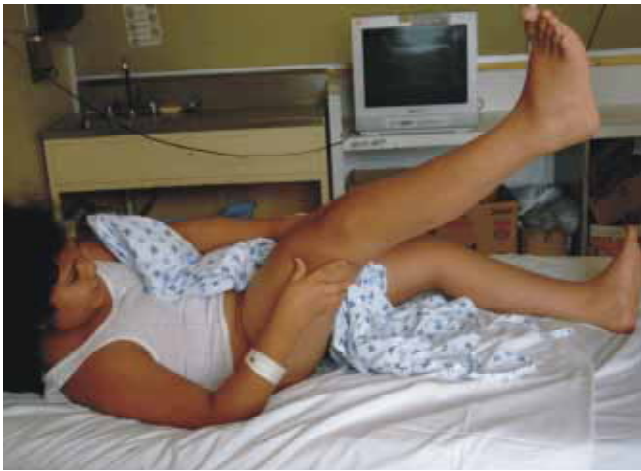

Figure 3. Right Thomas.



Figure 4. Negative Galleazi.

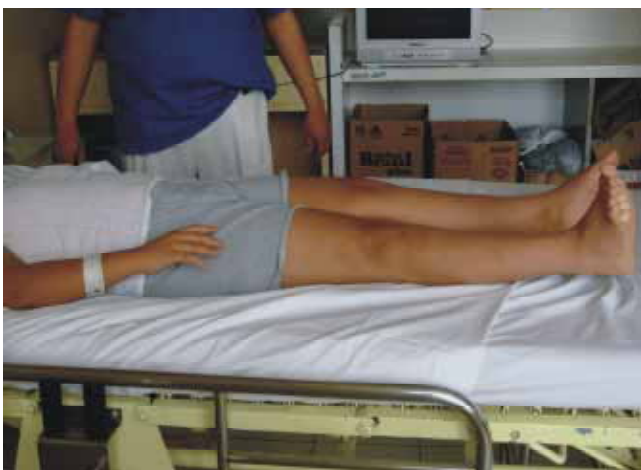

Figure 5. Attitude of the right pelvic limb.

Galleazi (*Figure 4*), right pelvic limb with a flexion, abduction and lateral rotation attitude (*Figure 5*), absence of active ranges of motion in the right hip, complete passive ranges of motion in the right hip but with pain (with the exception of adduction) (*Figure 6*), no Celsus, no collateral venous network, no regional adenomegalies, normal vascular exam of the right pelvic limb, hypertrophic scar of a posterior approach in the right hip (*Figure 7*), an AP pelvic X-ray was taken (13/07/09) showing lytic lesions (dots, comas and rings), with a festooned margin originating from the right iliac wing, femoral head, acetabulum and ischiopubic ramus, soft tissue lesion, radiolucent matrix, bone matrix formation, the lesions break the cortices of the femoral head and the bottom of the acetabulum, with a combined periosteal reaction (*Figure 8 and 9*), a metasta-



Figure 6. Complete abduction.

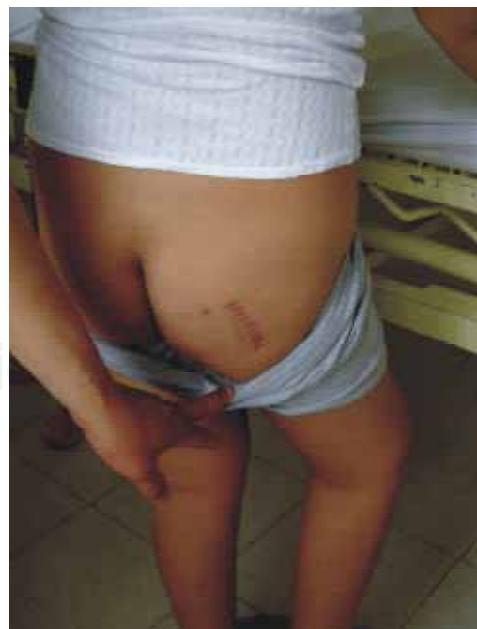

Figure 7. Keloid scar.

tic bone series was performed that confirmed the findings in the AP pelvic X-ray and did not find any more lesions in other segments; laboratory tests to confirm bone metabolism, inflammation reactants and tumor markers reported persistently elevated alkaline phosphatase, calcium, phosphorus and uric acid, so a sequela of septic arthritis was ruled out and the possibility of a neoplasia was considered; a nuclear MRI of the pelvis was ordered (06/08/09), which found a destructive lesion at T1, of medium to low density and high density at T2, with rupture of the femoral head and acetabular cortices, involving the right iliac wing and ischiopubic ramus, as well as invasion of the pelvic cavity soft tissues and the anterolateral compartment of the

proximal muscle (*Figure 9-11*); Tc-99m bone scans were performed (31/07/09) that showed hyper uptake of the radiolabeled drug in the right hip, with labeled ciprofloxacin (05/08/09) without any uptake (*Figure 12 and 13*), with thallium (07/08/09) that showed drug hyper uptake in the right hip in the early phase and a node in the left thigh; there was hyper uptake in the left thigh and femur during the late phase (*Figure 14*), with methoxy isobutyl isonitrile (02/10/09) it was concluded that there is a neoplastic process in the right hip with a metabolism suggestive of multidrug resistance; a Smith Petersen incisional biopsy was performed taking samples of the anterior rectus, sar-

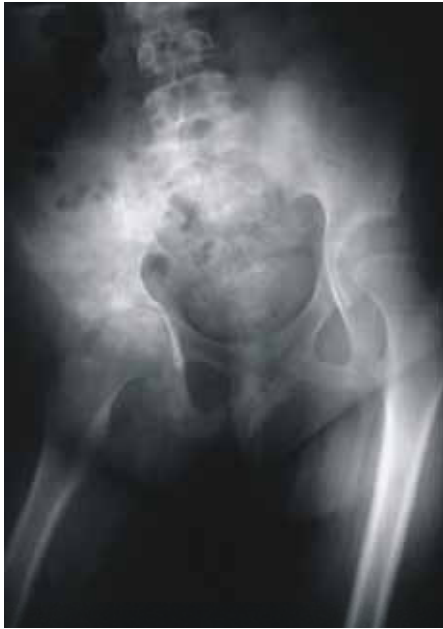

Figure 8. AP pelvic X-ray.

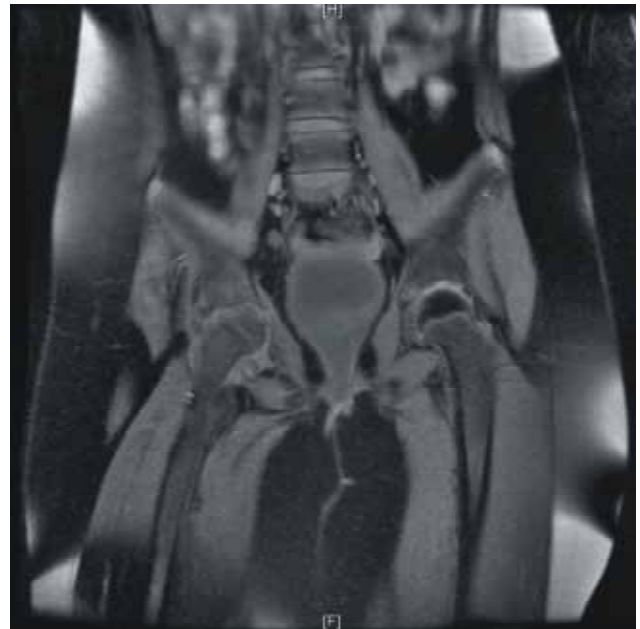

Figure 10. Pelvic NMR.

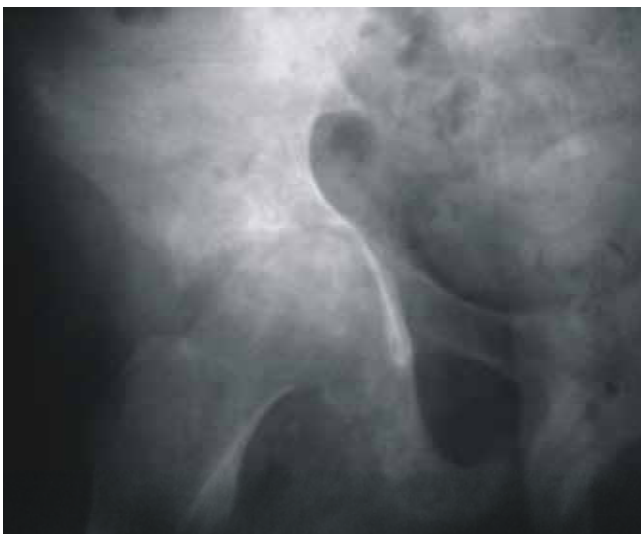

Figure 9. AP pelvic X-ray

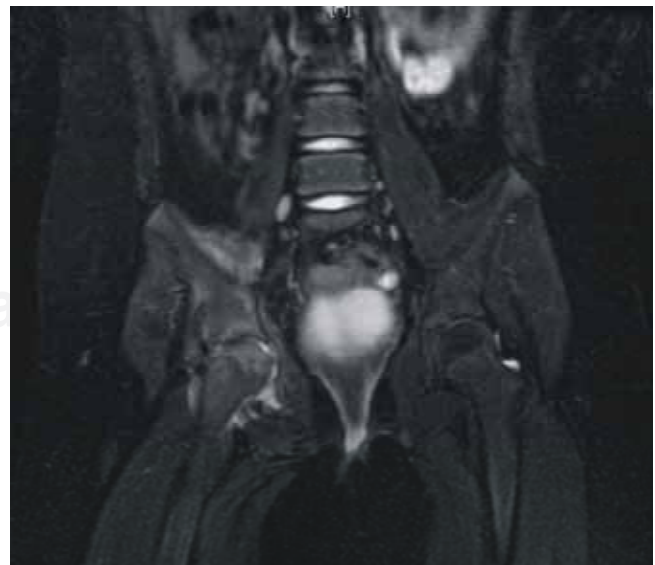


Figure 11. Pelvic NMR.

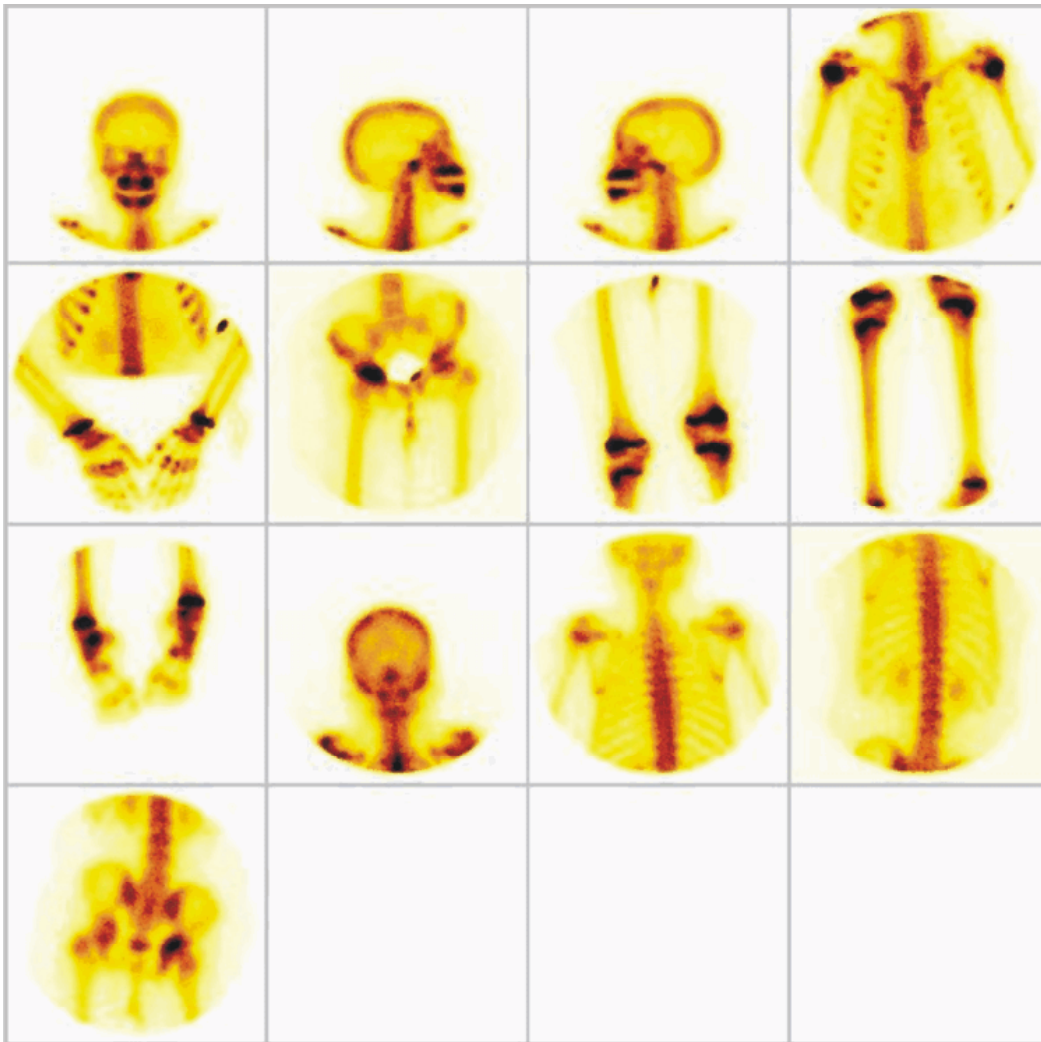


Figure 12. Tc-99m bone scan.

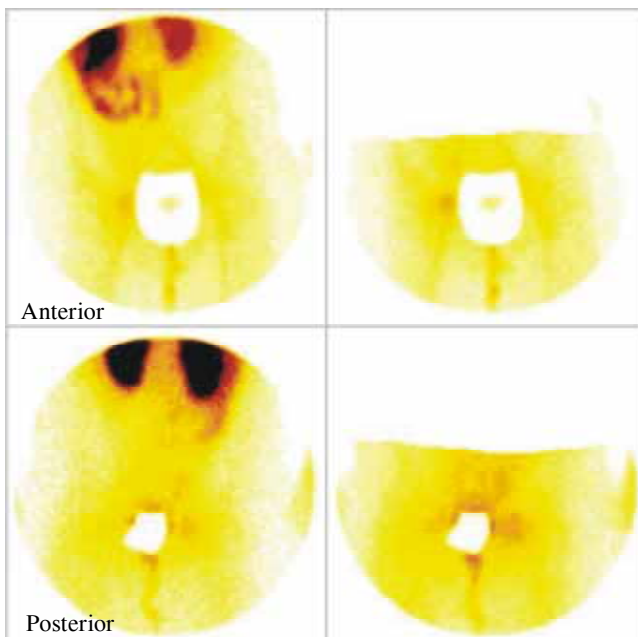


Figure 13. Labeled ciprofloxacin bone scan.

torius, articular capsule, femoral neck, acetabulum and femoral head, with the following histopathologic report: FIBROMATOSIS PROCESS WITH NO EVIDENCE OF OSTEOMYELITIS; the patient was maintained with physical rehabilitation, she is being followed-up, does not have hip pain, apparently she does not have any tumor activity, is capable of bipedestacion and has assisted gait.

Conclusion

From the beginning this case represented the challenge of making the differential diagnosis between sequelae of an infectious process and a bone tumor process of the hip; the former was ruled out based on the radiologic and biochemical findings; we initially suspected a Ewing type of bone marrow neoplasia due to the gamma scan, radiologic and biochemical features. Considering the histopathologic result of aggressive fibromatosis and ruling out the sequelae of an infectious process, we decided to provide conservative treatment (physical rehabilitation) and follow her up to later assess whether she required surgical treatment or not.

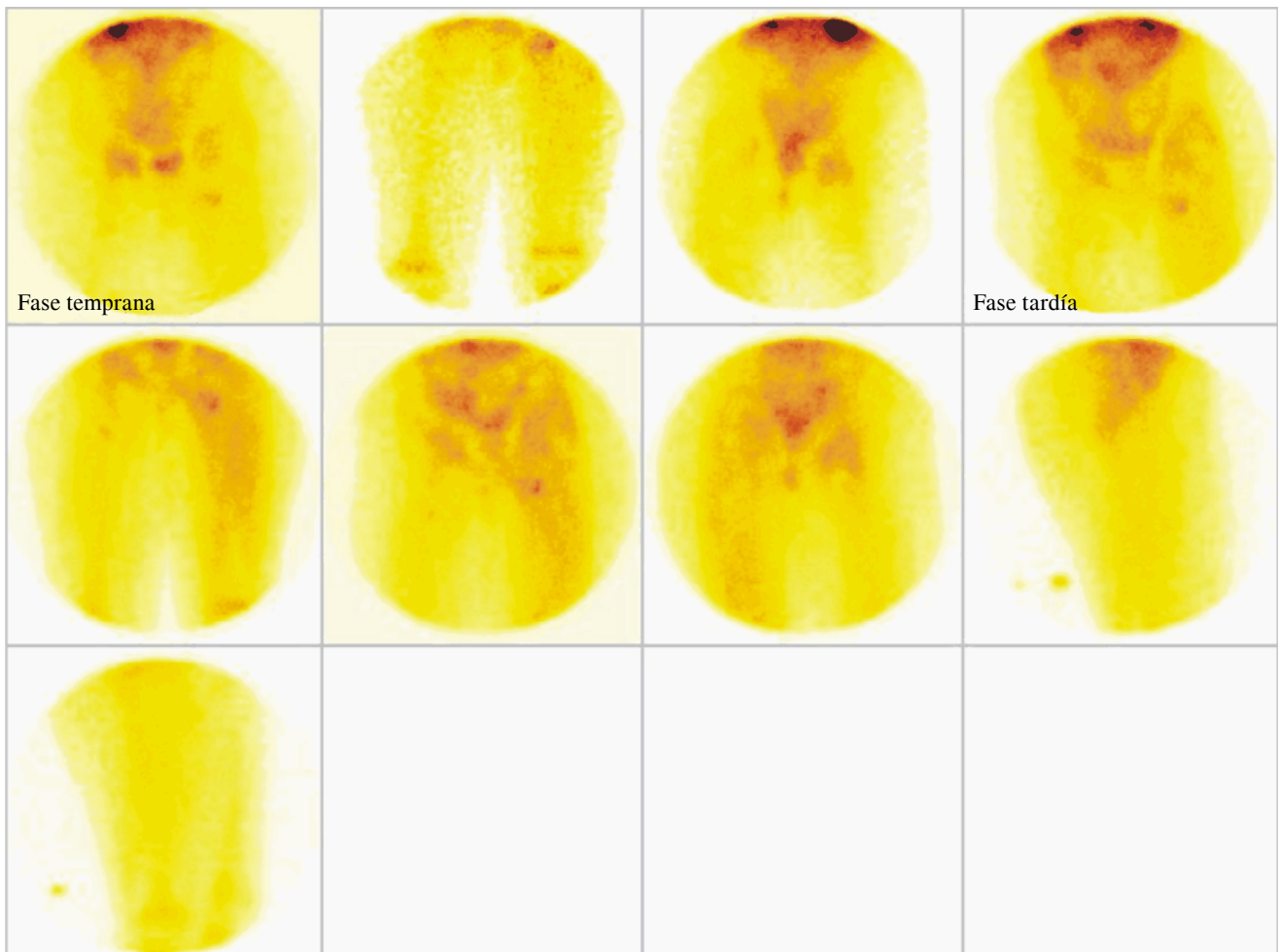


Figure 14. Thallium bone scan.

References

1. Campbell: Cirugía Ortopédica, 10a. Edición, 2005, Vol. 1, Edit. Elsevier: 861-78.
2. Robbins SL, Kumar V: Patología Humana, 4a. Edición, 1999, Vol. 2, Edit. Interamericana: 504-21.
3. Arnaud EJ, Perrault M, Revol M, et al: Surgical treatment of dermatofibrosarcoma protuberans. *Plast Reconstr Surg* 1997; 100: 884.
4. Cushner FD, Morwessel RM: Myositis ossificans in children. *Orthopedics* 1995; 18: 287.
5. Posner MC, Shiu MH, Newsome JL, et al: The desmoids tumor: not a benign disease. *Arch Surg* 1989; 124: 191.
6. Zembish A, Schick S, Trattinig S, et al: Elastofibroma dorsi: study of two cases and magnetic resonance imaging findings. *Clin Orthop* 1999; 364: 213.