

## Original article

## Grade III acromioclavicular dislocation treated with a minimally invasive approach

Algarín-Reyes JA,\* Salcedo-Dueñas JA,\* Rodríguez-Olguín J,\*\*  
Bello-González A,\*\*\* Sancho-Barroso F\*\*\*\*

Polanco Mexican Red Cross Hospital

**ABSTRACT. Objective:** To determine the efficacy of minimally invasive surgery (MIS) in the treatment of type III acromioclavicular dislocations using the UCLA and DASH evaluations. **Material and methods:** Prospective, longitudinal, observational study; clinical series of patients with a diagnosis of type III acromioclavicular dislocation who underwent MIS consisting of percutaneous reduction, placement of a 4.5 mm cortical screw, an 11 mm metallic washer and 1.6 mm Kirschner nails at the Polanco Red Cross Hospital from July 2007 to July 2009. The evaluations were done using the UCLA test and the DASH questionnaire. **Results:** The total number of patients was 42; 5 females and 37 males. According to the UCLA test, 86% of them had excellent to good results and 14% partial to poor results. The results of the DASH questionnaire were as follows: 80% had no difficulty to mild difficulty; 18% had moderate to severe difficulty, and 2% had disability for performing daily life activities. **Conclusions:** MIS is a good treatment for the management of type III acromioclavicular dislocation with long-term results based on the UCLA test and the DASH questionnaire.

**Key words:** luxation, shoulder, ambulatory surgery, evaluation.

**RESUMEN. Objetivo:** Determinar la eficacia de la técnica mínimamente invasiva (MIS) en el tratamiento de las luxaciones acromioclavicular tipo III por medio de las evaluaciones UCLA y DASH. **Material y métodos:** Estudio prospectivo, longitudinal, observacional, serie clínica de pacientes con diagnóstico de luxación acromioclavicular III que fueron sometidos a la técnica MIS, consistente en reducción percutánea, colocación de tornillo cortical 4.5 mm más arandela metálica 11 mm y clavillos Kirschner 1.6 mm, en el Hospital Cruz Roja Mexicana «Polanco» de Julio 2007 a Julio del 2009. Evaluado por medio del test UCLA y cuestionario DASH. **Resultados:** 42 pacientes, 5 femeninos y 37 masculinos, de acuerdo al test UCLA, presentaron 86% de excelentes a buenos resultados, 14% de resultados parciales a pobres. Cuestionario DASH se obtuvieron como resultados: 80% sin dificultad a dificultad leve, 18% dificultad moderada a severa y 2% incapacidad ante sus actividades cotidianas. **Conclusiones:** La técnica MIS es un buen tratamiento en el manejo de la luxación acromioclavicular tipo III sustentadas a largo plazo por medio de la UCLA y DASH.

**Palabras clave:** luxación, hombro, cirugía ambulatoria, evaluación.

#### Level of evidence: IV (Act Ortop Mex, 2010)

\* Orthopedist and Traumatologist Graduated from the Trauma Center, Mexican Red Cross.

\*\* Staff Physician at the Trauma Center, Mexican Red Cross.

\*\*\* Head of Service at the Trauma Center, Mexican Red Cross.

\*\*\*\* Orthopedist and Traumatologist, Angeles Mocol Group.

Please address all correspondence to:

Dr. José Antonio Algarín Reyes. Calle Espíritu Santo Núm. 69A. Col Barrio del niño Jesús. Delegación Coyoacán, Código Postal: 04330. Tel: 0445532586559/16647075.

E-mail: limp\_9wes@yahoo.com.mx, algarin\_antonio@hotmail.com.

Este artículo puede ser consultado en versión completa en <http://www.medigraphic.com/actaortopedica>

#### Introduction

The acromioclavicular dislocation was described since the egyptian papyri. Hippocrates was the first to distinguish the acromioclavicular injuries from the glenohumeral ones, as well as to determine the mechanism of injury.<sup>1,2</sup>

The acromioclavicular (AC) joint is an arthrodial joint composed of a fibrocartilaginous meniscus and surrounded by a thin capsule preventing its horizontal displacement. It is reinforced by the acromioclavicular ligaments: anterior, posterior and superior, with the latter being the strongest one. Its dynamic stabilizers are the deltoid and trapezius muscles; its passive stabilizers are the coracoclavicular liga-

ments (conoid and trapezoid). The conoid ligament prevents the upward displacement of the clavicle relative to the coracoid, and the trapezoid prevents the medial translation of the clavicle relative to the acromion when supporting axial loads. The normal acromioclavicular space is 6mm, a greater articular space is considered as pathological. The normal coracoclavicular interval is from 1.1 to 1.3 cm approximately. Half of all the normal AC joints have a certain degree of saddling on the clavicle, which contributes to explain the mechanism of injury that may lead to a clavicular fracture or an acromioclavicular dislocation.<sup>3</sup>

AC joint dislocations are most often incomplete than complete, with a ratio of 2:1. This is because the deltotrapezoidal fascia provides a passive stabilization of the lateral clavicle, even after a complete tear of the coracoclavicular (CC) and AC ligaments. The complete dislocation of the AC joint requires the tear of both the CC and the AC ligaments, as well as of the acromioclavicular articular capsule and the deltotrapezoidal fascia. Recent cadaver research has shown that the AC joint can stand high forces of as much as 500 to 700 N.<sup>3-8</sup>

The mechanisms of direct injury, which are the most common ones, occur after a blow in the upper edge of the acromion and cause both shearing and compression of the joint, as well as a variable degree of articular displacement. The indirect mechanism, especially due to falls on an arm detached from the body, produce both shearing and compression of the joint.<sup>1,8,9</sup> Tossy et al. described three types of AC dislocation, to which Rockwood et al. added three subgroups. The classification is based on the extent of the disruption of the AC and CC ligaments, using radiologic types of displacement of the clavicle relative to the acromion. In type III, the AC and CC ligaments are torn and the attachments of the deltoid and trapezium are torn from the distal clavicle.<sup>5-10</sup>

Concerning type III repairs, different studies have shown that surgery offers a clear advantage compared with conservative treatment.<sup>7,9,12,13,15</sup> Despite these experiences, many authors still recommend an individualized approach for the type III injuries. The indications for surgical or conservative management are based on the patient's characteristics, i.e., age, activity level and demand for cosmetic results.

Treatment is controversial particularly in young athletes and manual workers involved in activities requiring the repetitive lifting of heavy objects. Besides the discussion on the indication of surgical management, there is a lack of consensus around the suitability of the various surgical techniques. The fact that there are 50 to 70 different surgical procedures reported in the literature for the treatment of CA dislocations indicates that the optimum procedure for this condition has not been found yet.<sup>7,13-15</sup>

The major causes for the variation among the current techniques may be summarized into four categories: the time when the surgery was performed, the choice of the surgical approach, the choice of ligament reconstruction, and the technique used to stabilize the reconstruction.<sup>12</sup>

The commonly described methods include ligament reconstruction, coracoclavicular fixation, excision of the distal clavicle, direct fixation of the AC joint, and dynamic muscle transfer. Rockwood, Guy and Griffin, in 1988, in a patient series reported in the literature using the Weaver-Dunn technique, found good results in 80% of their patients. Ten years later, Daniel K. Guy et al., who implemented the modification of the UCLA test (on which this study is based), operated on 23 patients using the Weaver-Dunn technique and reported good to excellent functional results in 19 patients, and fair to poor results in four. Sim E. et al. used the hook plate to maintain the reduction of the acromioclavicular dislocation and reported a case series of 21 males operated on, with excellent results in 8 patients, good in 7, and poor in one; they used the functional scale of Poingenurst et al.<sup>2</sup>

Minimal incision surgery (MIS) is a surgical approach that allows performing interventions through small incisions without the direct exposure of the surgical planes, leading to minimum trauma of the neighboring tissues, and uses radiologic or fluoroscopic control during the intervention as a guide.<sup>16</sup>

At the Mexican Red Cross Hospital the Tossy-Rockwood III acute acromioclavicular dislocations are treated surgically. They are managed with percutaneous reduction with an MIS technique, plus the placement of a 4.5 mm cortical screw with an 11 mm metal washer, meniscectomy and arthrodesis with 1.6 mm Kirschner nails, fixing the clavicle to the acromion.

All patients undergoing shoulder surgery are evaluated using clinoradiologic scales, such as the UCLA scale modified by Guy et al., and the daily functional assessment questionnaire, such as the DASH, as a support to the medico-surgical results.<sup>2,17,18</sup>

The objective of this paper is to determine the efficacy of the MIS technique in the treatment of type III acromioclavicular dislocations using the UCLA and DASH evaluations.

## Material and methods

This is a prospective, longitudinal, observational study, a clinical series of patients seen at the Polanco Mexican Red Cross Hospital with a diagnosis of Tossy-Rockwood III acromioclavicular dislocation during the period between July 2007 and July 2009. The following parameters were established as the inclusion and exclusion criteria:

### Inclusion criteria

- Patients with Tossy-Rockwood type III acute acromioclavicular dislocation treated surgically from July 2007 to July 2009.
- Patients with skeletal maturity.
- Patients with fully integrated clinical records.
- Patients with Tossy-Rockwood type III acute acromioclavicular dislocation plus lesions not involving the ipsilateral scapular girdle.

### Exclusion criteria

- Patients who died during the study period.
- Patients with acute acromioclavicular dislocation, Tossy-Rockwood types I, II, IV, V and VI.
- Patients who discontinued the follow-up or rehabilitation.
- Patients with a fracture in another region of the scapular girdle.
- Patients who did not comply with the DASH and UCLA evaluations.
- The patients' records included the clinical and radiological data (shoulder AP, shoulder stress AP, and shoulder oblique X-rays) (*Figure 1*). Preoperative pain was assessed using the visual analog scale (VAS). A preoperative trace was done and then the patients underwent surgery with the MIS technique. Surgeons were chosen at random for patient treatment and analysis.

### Surgical technique

Percutaneous reduction is performed with patients under balanced general anesthesia. They are placed in dorsal decubitus in the beach chair position on a radiolucent table with the arm at 0°, and the forearm bent at 90° on the abdomen. After performing asepsis and antisepsis of the shoulder, a 1.5 cm-long incision is made with a No. 14 scalpel on the surface of the AC joint. The articular disc, the torn capsular ligaments and the fragments of the articular cartilage found between the acromion and the clavicle are removed. A curette is used to refresh the borders of the clavicle and the acromion, more vigorously on the clavicle side (2 mm).

A 1 cm incision is made with a scalpel No. 14; plane dissection is performed until the upper surface of the clavicle is located with Kelly forceps. Using fluoroscopic control, a monocortical drilling of the clavicle is performed with a 4.5 mm drill bit (drill bit guide 4.5/3.2 mm); a 3.2 mm drill bit is used to drill both cortices of the clavicle as well as 75% of

the coracoid process (*Figure 2*). A thread cut is performed with a male tap and then a 4.5 mm cortical screw with an 11 mm metal washer is placed all the way to the entry site of the screw on the clavicle. Note: the washer is used to increase the contact surface, avoid microfractures and facilitate extraction.

A 1.6 mm Kirschner nail is placed percutaneously with the drill and, under fluoroscopic control, it is passed through the acromion through the AC joint. With the support of a triple guide, a second Kirschner nail is placed parallel to and in the same position as the first one. The skin incisions are closed with simple stitches using 3-0 Nylon suture (*Figure 3*). The nails are bent and cut and then protected. The universal shoulder immobilizer is put in place and the procedure ends with a postoperative radiographic control (*Figure 4*).

### Postoperative management

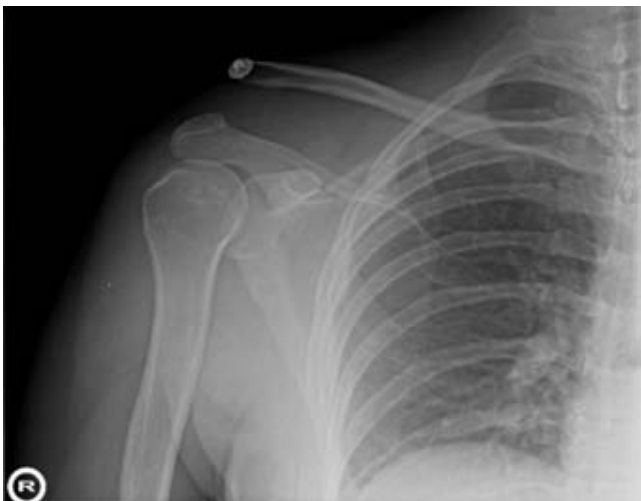Postoperative pain was assessed with the VAS at six hours. In accordance with their added conditions, patients were discharged with a prescription of nonsteroidal anti-inflammatory agents for 7 days (*Figure 5*).

The follow-up was performed at week 2, when the surgical wound was assessed, the stitches were removed and pendular exercises were begun. Patients were instructed not to elevate the arm more than 90°.

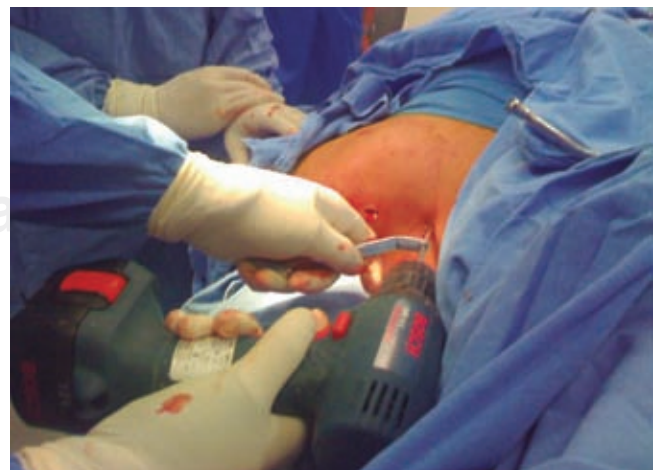Patients were assessed again at week 6, when the percutaneous Kirschner nails were removed with forced pressure forceps or Kelly forceps at the office using a sterile technique; isometric exercises were begun.

At week 8 the 4.5 mm cortical screw was removed with a screwdriver at the office with local anesthesia using the same surgical incision site. A stringent rehabilitation therapy was begun at this moment to improve the ranges of motion and for muscle strengthening purposes.

At weeks 10 and 14 the ranges of motion were assessed and home rehabilitation was continued. If the patients'



**Figure 1.** Grade III acromioclavicular dislocation.



**Figure 2.** Drilling from the clavicle to the coracoid with a 3.2 mm drill bit.

ranges of motion were less than 50% of normal, they were referred to rehabilitation therapy controlled by a specialized therapist.

At week 18 the patients were seen again for clinical and radiographic evaluation using the UCLA test. The latter consists of a total score of 20 that includes maintenance of the reduction, range of motion, muscle strength, pain, weakness, change of occupation, patient satisfaction and complications.

A total score of 18-20 means excellent results; 15-17, good results; 12-14, partial results, and poor results, less than 11. The DASH score, which assesses the patient's daily activities, was also used. Finally, the patients were seen again at week 24 to assess their final result and to be discharged.

## Results

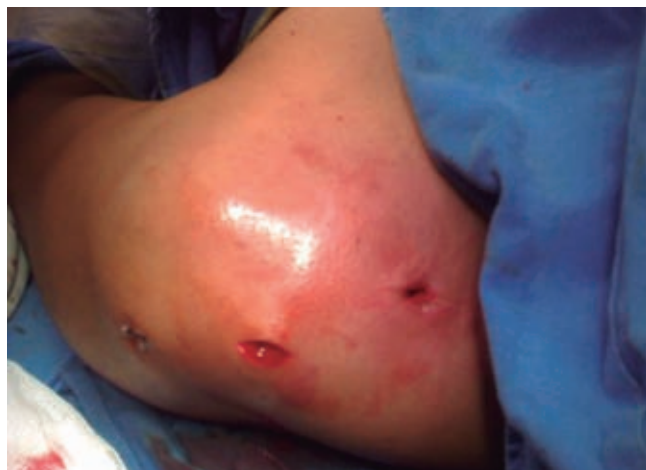A total of 42 patients were included, 37 males (88%) and 5 females (12%), with a clinical and radiographic diagnosis of Tossy-Rockwood Type III acute acromioclavicular dislocation, treated with percutaneous reduction, placement of a

4.5 mm cortical screw plus an 11 mm metal washer and 1.6 mm Kirschner nails, and followed-up for at least 18 weeks.

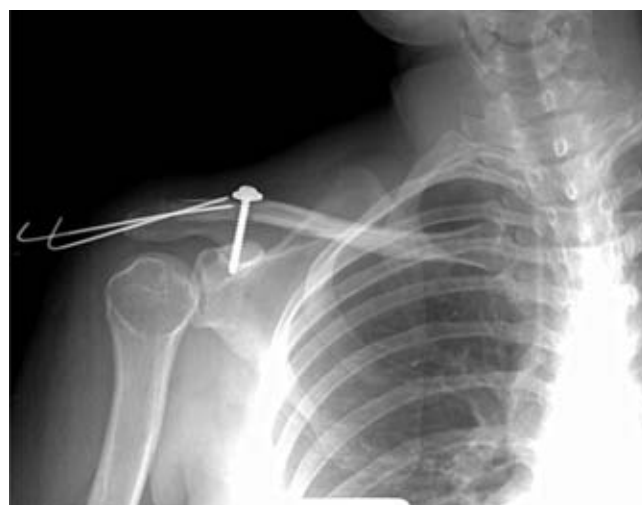The age range was 18-52 years; mean age was 34.6 and the SD was 11.54. The main mechanism of injury was fall from one's own height with direct contusion of the shoulder in 61.9% of cases ( $n = 26/42$ ). Other mechanisms included fall from a height in 30.9% ( $n = 13/42$ ) and head-to-head crash in 7.1% ( $n = 3/42$ ) of cases.

Forty-two of the patients who underwent surgery were blue-collar workers ( $n = 24/42$ ), 19% were students ( $n = 8/42$ ), 4.7% were housewives ( $n = 2/42$ ), 11.9% had an unspecified job ( $n = 5/42$ ), and 4.7% were unemployed ( $n = 2/42$ ). Patients with a relevant medical history (substance abuse or chronic degenerative conditions) accounted for 30.9% ( $n = 13/42$ ).

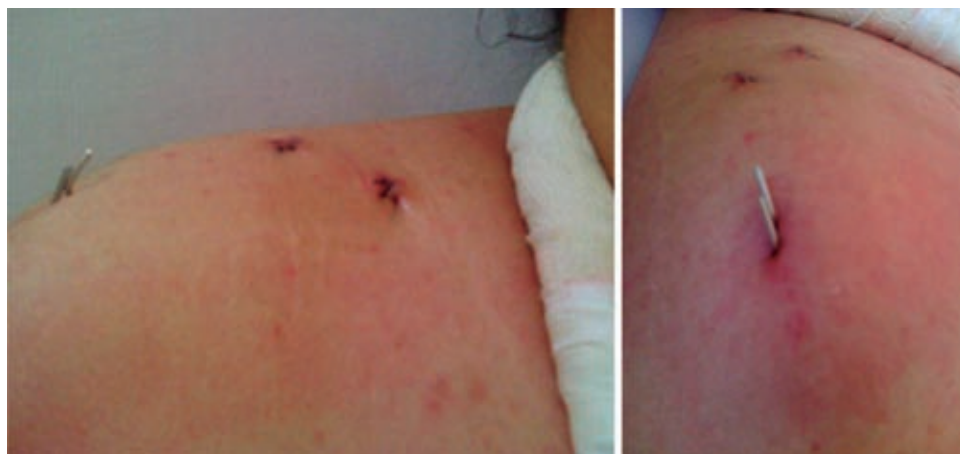The predominant side of injury was the right side, which accounted for 66.6% ( $n = 28/42$ ) of the cases. No added lesions were seen upon admission in 71.4% ( $n = 30/42$ ); 14.2% ( $n = 6/42$ ) had head trauma; 11.9% ( $n = 5/42$ ) had a fracture elsewhere in the body, and, finally, one patient, or 2.3% ( $n = 1/42$ ), had a mixed injury characterized by grade



**Figure 3.** Approaches in the MIS technique.



**Figure 4.** Radiologic result with the MIS technique.



**Figure 5.** Patient at postoperative day 2.



II head trauma plus fracture of the contralateral scapula.

The surgical procedure was performed under balanced general anesthesia, with a mean anesthetic time of 117 minutes, a mean operative time of 81 minutes, a mean bleeding of 83 cc, and a fluoroscopy time of 8 seconds. The mean length of stay was 2.6 days. Two patients had a longer hospital stay due to the complications that occurred since their admission (one with grade II head trauma + right parietal laminar epidural hematoma, and the second one with grade II head trauma + Fisher III + costal fractures + pneumothorax + compression fractures at T12-L1).

The preoperative pain assessment result with the VAS showed moderate pain with a mean score of 6, and the postoperative result was mild pain with a mean score of 3.4.

A 4.5 mm cortical screw was placed in all cases, with a mean length of 38 mm. The intraoperative complications consisted of injury of the subclavian artery with successful repair in one patient, rupture of a drill bit and poor placement of the cortical screw.

The postoperative complications observed before week 8 were as follows: dislodgement of the 4.5 mm cortical screw in 9.5% (n = 4/42), and nail displacement in 38% (n = 16/42).

Nail displacement was subdivided into displacement of one nail and displacement of both nails, accounting for 75% (n = 12/16) and 25% (n = 4/16), respectively.

After postoperative week 8, patients were seen again to remove the screw and the metal washer in the outpatient setting. Of the 42 patients, 3 (7%) had problems at the time of removal, and 2 patients underwent the procedure in the operating room because they chose to be sedated during the procedure.

During the assessment of ranges of motion at week 10 the mean values were: flexion  $61^\circ \pm 17$ , extension  $27^\circ \pm 9.6$ , abduction  $80^\circ \pm 31$ , adduction  $29^\circ \pm 8.5$  lateral rotation  $32^\circ \pm 8.6$ , medial rotation  $27^\circ \pm 10.7$ .

The ranges of motion were assessed again at week 14 and the following values were found: flexion  $81^\circ \pm 13$ , extension  $40^\circ \pm 5.7$ , abduction  $150^\circ \pm 31$ , adduction  $41^\circ \pm 3.3$ , medial rotation  $44^\circ \pm 7.3$ , lateral rotation  $39^\circ \pm 4.11$  (*Figure 6*).

At week 18 the outcomes were assessed using the UCLA test, with the following results (*Table 1*).

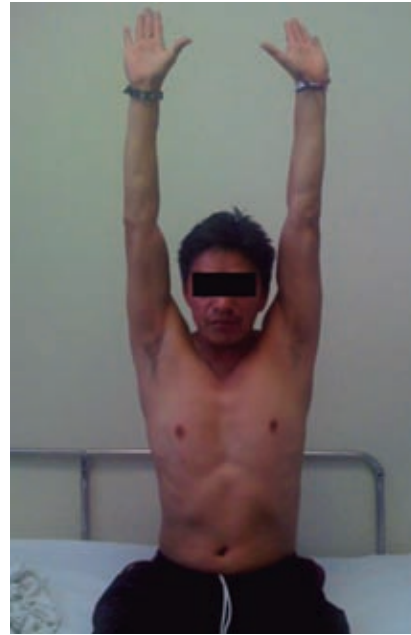Of the 42 patients, 57.14% had excellent results (n = 24/42), 28.57% good results (n = 12/42), 9.52% partial results (n = 4/42), and 4.76% had poor results (n = 2/42) (*Chart 1*).

The results of the DASH test performed at 18 weeks were: 70% with no difficulty, 10% with mild difficulty, 11% moderate, 7% severe, and 2% were unable to perform regular physical activity (*Chart 2*).

## Discussion

We know that the acromioclavicular joint represents a surgical conflict due to its multiple motion axes and its big lever arm. These are the reasons why many acromioclavicular fixation methods fail.

There are tens of procedures, modifications and approaches, as well as techniques for the reconstruction of an injured AC joint. The wealth of surgical options reflects the difficulties involved in the successful restoration of the very complex balance of forces that pass through the joint.



**Figure 6.** Patient assessed at 14 weeks.

**Table 1. Results of the UCLA scale (Modified)**

Maintenance of reduction		
4 Reduced	26	61.90%
2 Subluxated	15	35.71%
0 Dislocated	1	2.38%
Range of motion		
2 Complete	32	76.19%
1 Preoperative improvement	9	21.42%
0 No preoperative improvement	1	2.38%
Strength		
2 Normal	36	85.71%
1 Preoperative improvement	6	14.28%
0 No preoperative improvement	–	–
Weakness		
2 None	27	64.28%
1 With extreme activity	14	33.33%
0 All the time	1	2.38%
Pain		
4 None	14	33.33%
3 With extreme activity	23	54.76%
2 With moderate activity	1	9.52%
1 With minimal activity	1	2.38%
0 All the time	–	–
Change in occupation		
2 Some or more intensive	40	95.23%
0 Less intensive	2	4.76%
Patient satisfaction		
2 Yes	38	90.47%
0 No	4	9.52%
Complications		
2 None	21	50.00%
1 Minor/solved	19	45.23%
0 Major/affected the results	2	4.76%

The failure of the fixation system, to the extent of causing a high complication rate, may lead to challenge the need for or the indication of a certain surgical technique, especially when the conservative treatment of the injury has produced good results. The current techniques are overshadowed by complications such as: infection, anesthetic risk, hematomas, non-cosmetic scars, recurrence of the deformity, rupture, material migration or loosening, erosion or fracture of the distal wall of the clavicle, pain and postoperative limitation of motion, a second procedure needed to remove the fixation, late acromioclavicular arthrosis, and soft tissue calcification.<sup>5-11</sup>

Minimally invasive surgery has evolved through the years as a medical or surgical procedure aimed at decreasing the degree of invasion of the body or, in other words, avoiding the unnecessary harm resulting from the approaches that stem from the incision itself. Traditionally, an important number of orthopedic surgical procedures were performed openly. The incisions were of a considerable size to dissect the different structures of each joint and repair them if necessary.

It is easy to understand that the approach to the joint itself led to harming healthy structures, and that the incision size and the abruptness in tissue management led to longer recovery times, postoperative pain and complications. The current aim of the orthopedic treatment is to preserve circulation, early mobility, and patient satisfaction with minimal

aggression. Thus the need to improve the above described treatments is invaluable. That is why the MIS technique was used for acromioclavicular dislocations. This technique is characterized by providing treatment of acute injuries with a combination of different techniques, such as the direct resection of the fibrocartilaginous tissue (meniscectomy) which, according to Goss et al., should be removed to avoid chronic or recurrent pain.<sup>11</sup> It includes the placement of a 4.5 mm cortical screw with an 11 mm metal washer (modified Bosworth technique), and the placement of Kirschner nails (Phemister technique) for reduction in the transverse plain, axial projection and fixation of the passive stabilizers.

The mechanism of injury in 61.9% of our patients was direct contusion due to fall from one's own height; 88% of them were working males (59.5% were blue-collar workers), so this condition represented a socioeconomic problem. The results presented by Stephan Pauly et al. include a 5:1 male:female ratio, and a large proportion of young and active patients (43% in their thirties) injured while performing sports activities (25-50%).<sup>2</sup>

Intraoperative complications resulted from the technical difficulty and the limited experience of the surgeons with the surgical procedure. Despite the fact that 35.71% of the patients had posterior dislocation of the material, this made no difference in the recovery of the ranges of motion, since as much as 76.19% of them had complete ranges of motion, 85.71% had normal muscle strength, and 64.28% did not have weakness at postoperative week.<sup>18</sup>

Having pain with extreme activities (54.76%) was not a factor leading to a change in occupation in 95.23% of patients. Functionality and the cosmetic result were factors leading to a 90.4% patient satisfaction rate.

Of the 7 patients with head trauma at the time of admission, 42.8% had screw dislodgement. It is important to underscore that patients with moderate to severe neurologic impairment are not eligible for this technique due to lack of postoperative care, as well as to the difficulty to control involuntary movements.

Unlike other techniques, the treatment-related complication rate for the MIS technique used for the treatment of acromioclavicular dislocation was 4.76%. No infections, hematomas, noncosmetic scars, osteolysis of the distal clavicle or paresthesias of the surgical site were observed.

Another complication is the need for a second intervention under local anesthesia to remove the coracoclavicular screw. This surgical procedure undoubtedly increases the costs and patient discomfort, and may put the cosmetic scar at risk if there is the need to broaden the surgical area due to difficulties for the removal. The biodegradable screw will be an option once its cost starts coming down. For patients treated at the Mexican Red Cross, the 4.5 mm cortical screw is affordable and functional. Another measure to improve the technique's results is the use of threaded-tip nails providing a better bone anchoring; this would be an excellent choice to minimize the complications described herein.

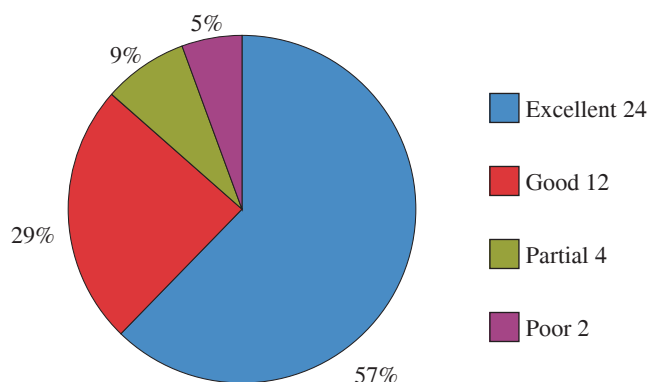


Chart 1. Results of the UCLA test.

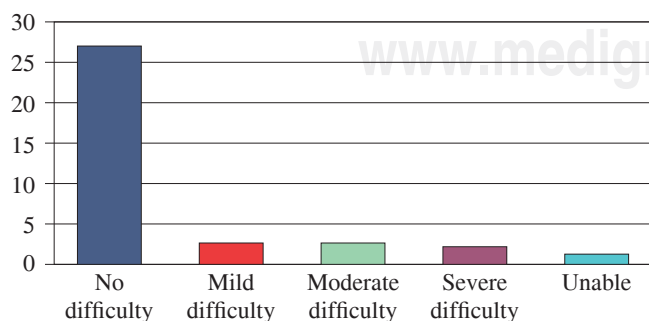


Chart 2. Results of the DASH test.

As the techniques are developed and improved, we will better know what once used to be unforeseen and unexpected. We have to perfect the management of this small but complex joint.

## Conclusions

MIS is a good treatment for the management of acromioclavicular dislocation in patients with acute traumatic injury, with long-term results based on the UCLA test and the DASH questionnaire. It provides a new treatment option when surgery of the AC joint is being considered. However, the results are not statistically significant so as to consider it as an exceptional technique. Better results will be obtained as we have better staff trained to perform the technique. More research is needed as well as long-term results that support these preliminary results.

## Acknowledgements

Thanks to Dr. Diana Sancho Flores, for her facilities and collaboration. Thanks to Dr. Gerardo Espinoza Lira for his support in the conduction of this work.

## References

1. Rockwood and Greens: Fracturas en el adulto. 5ª edición, Vol 1. Philadelphia JB. Lippincott 1984: 1210.
2. Mendoza-Gutiérrez I, Arzate-Delgado E. Evaluación funcional en el tratamiento quirúrgico de la luxación acromioclavicular crónica. *Acta Ortop Mex* 2004; 18(2): 41-3.
3. Harris TG, Lynch MD: Acromioclavicular joint separations: update, diagnosis, classification and treatment. *Orthop* 2003; 14: 255-61.
4. Pauly S, Gerhardt CP, Haas N: Prevalence of concomitant intraarticular lesions in patients treated operatively for high-grade acromioclavicular joint separations. *Knee Surg Sports Traumatol Arthrosc* 2008; 7(5): 513-7.
5. Gladstone JN, Rosen AL: Disorders of the acromioclavicular joint. *Curr Opin Orthop* 1999; 10: 316-21.
6. Zalles-Auchen F, Chávez-Chuquimia D: Luxación acromioclavicular, tratamiento quirúrgico. Resección del extremo lateral de la clavícula en la luxación acromioclavicular grado III de Tossy. *Rev Bol de Orto y Trauma* 2007; 17(1): 18-21.
7. Clancy WG Jr, Meister K: Craig, Hombro; 2da edición; 2009: 213.
8. Ryhanen J, Leminen A, Jamsa T: A novel treatment of grade III acromioclavicular joint dislocations with a C hook implant. *Arch Orthop Trauma Surg* 2006; 126: 22-7.
9. Campbell: Cirugía Ortopédica, 10ª edición: 2003: 3178-84.
10. Tossy JD, Mead NC, Sigmond HM: Acromioclavicular separations: useful and practical classification for treatment. *Clin Orthop* 1963; 28: 111-9.
11. Fraser-Moodie JA, Shortt NL: Aspects of current management injuries to the acromioclavicular joint. *JBJS* 2008; 90-B(4): 697-707.
12. Logters TT, Briem D: K-wire arthrodesis and coracoclavicular augmentation of complete acromioclavicular separations: Functional and subjective results. *Eur J Trauma Emerg Surg* 2008; 1: 43-8.
13. Sim E, Schwarz N: Repair of complete acromioclavicular separations using the acromioclavicular-hook plate. *Clin Orthop and Rel Res* 1995; 314: 134-42.
14. Larsen E, Bjerg-Nielsen A, Christensen P: Conservative or surgical treatment of acromioclavicular dislocation. *JBJS Am* 1986; 68: 552-5.
15. Rolf O, Hann Von Weyhern A: Acromioclavicular dislocation Rockwood III-V: Results of early versus delayed surgical treatment. *Arch Orthop Trauma Surg* 2008; 128: 1153-7.
16. Velázquez-Pedroza VH, López-Marmolejo A: Eficacia de la cirugía mínimamente invasiva en el antepié de los niños. *Acta Ortopédica Mexicana* 2008; 22(1): 19-25.
17. Jester A, Harth A: Disabilities of the arm, shoulder and hand (Dash) questionnaire: determining functional activity profiles in patients with upper extremity disorders. *J Hand Surgery (British and European)* 2005; 30b(1): 23-8.
18. Hudak PL, Amadio PC: Development of an upper extremity outcome measure: the Dash (Disabilities of the arm, shoulder, and head). *American Journal of Industrial Medicine* 1996; 29: 602-8.