

Review article

Bone manifestations of Gaucher's disease in Mexican patients

Blass-Jaimes P*

Unidad Médica de Alta Especialidad,
«Magdalena de las Salinas» del Instituto Mexicano del Seguro Social (IMSS).

ABSTRACT. Gaucher's disease (GD) is the most common of the lysosomal storage diseases (LSDs) that have been defined so far. Its incidence rate is quite low, but its organ involvement profile is disrupting as it results in a considerable morbidity and mortality rate, as well as in high health care costs and poor quality of life. It is a recessive and autosomal genetic disease associated with the insufficiency of the enzyme glucocerebrosidase. The storage of the substrate produces considerable organ deterioration in the skeleton, liver, kidneys, lungs, spleen, brain and bone marrow. This report presents several clinical cases of Mexican patients characterized by bone damage with the purpose of disseminating among orthopedic surgeons the typical findings and course of the disease. The particularities of the patients are discussed, as well as their response to enzyme replacement therapy (ERT) and the results of their clinical follow-up with the latest therapeutic resources.

Key words: lysosomal storage diseases, bone, therapy, enzymes, Mexico.

RESUMEN. La enfermedad de Gaucher (EG) es la más común entre las enfermedades por depósito lisosomal (EDL) definidas a la fecha. Posee una tasa de incidencia bastante baja a nivel mundial, pero su perfil de afectación orgánica es perturbador ya que se traduce en una morbilidad importante, así como en elevados costos de atención y pobre calidad de vida. Es una patología genética recesiva y autosómica asociada con la insuficiencia de la enzima glucocerebrosidasa. El depósito de sustrato produce deterioro orgánico considerable en esqueleto, hígado, riñones, pulmones, bazo, cerebro y médula ósea. Este informe presenta varios casos clínicos de pacientes mexicanos, caracterizados por el daño óseo con el objetivo de difundir los hallazgos y evoluciones típicas de la enfermedad entre los ortopedistas. Se discuten las particularidades de los pacientes, así como su respuesta al tratamiento con terapia de reemplazo enzimático (TRE) y los resultados en su seguimiento clínico, con los recursos terapéuticos actualizados.

Palabras clave: enfermedades por almacenamiento lisosomal, hueso, tratamiento, enzimas, México.

Level of evidence: IV (Act Ortop Mex, 2010)

* Orthopedic Surgery. «Magdalena de las Salinas» High Specialty Medical Unit, Mexican Social Security Institute (IMSS).

Please address all correspondence to:

Dr. Paul Blass Jaimes,

Hospital San Ángel Inn Chapultepec

Av. Chapultepec Num. 489, 2° piso, Consultorio No. 210. Colonia Juárez.

C.P. 06600, México, Distrito Federal.

Phone: 1162-0200, extension 2230.

Mobile: 044 55 91 99 93 71

E-mail: paul_blass@yahoo.com.mx

Este artículo puede ser consultado en versión completa en <http://www.medigraphic.com/actaortopedica>

Introduction

Lysosomal storage diseases (LSDs) represent a group of entities with quite a low incidence rate, but with a significant organ involvement profile. This turns them into a health problem with important morbidity and mortality rates that significantly impairs the patients' quality of life and whose appropriate treatment requires considerable expenses. Gaucher's disease (GD) is the most frequent among the 41 known LSDs (aspartylglucosaminuria, metachromatic leukodystrophy, mucopolysaccharidosis, cystinosis, Pompe, Tay Sachs, Niemann Pick, Wolman, Fabry diseases

Table 1. Classification of Gaucher's Disease.^{1,2}

Clinical aspects	Type I non-neuronopathic	Type 2 acute neuronopathic	Type 3 Subacute neuronopathic
Onset	Childhood/adulthood	Early childhood	Infancy
Hepatosplenomegaly	+ a +++	+	+ a +++
Hypersplenism	+ a +++	+	+++
Bone crises/fractures	- a +++	-	++ a +++
Neurologic compromise	-	+++	++
Survival (years)	6-80	< 2	20-40
Ethnic group	Panethnic (Askenazi Jews)	Panethnic	Panethnic (polish, swedish, arabs)
Frecuencia	1/40,000 a 1/60,000	< 1/100,000	< 1/100,000

Adapted from Grabowski GA et al. *Eur J Pediatr.* 2004; 163(2): 58-66. Beutler E, Grabowski G. Gaucher Disease. In: Scriver CR, Baudet AL, Sly WS and Valle D (Eds). *The Metabolic & Molecular Bases of Inherited Disease.* 8th ed. Vol III, McGraw-Hill, New York, 2001: 3635. (Consensus for the diagnosis, treatment and follow-up of non-neuropathic Gaucher's disease in the Republic of Argentina)

or syndromes, and others), all of them characterized by the deficiency of a lysosomal protein or enzyme.

GD was originally described by Phillip Charles Ernst Gaucher in 1882, in a 32 year-old patient. Almost eighty years elapsed until, in 1965, Brady elucidated its biochemical bases and classified it into three types: *non-neuropathic* type [type I]; 2) *acute neuropathic* type [type II], and 3) *subacute neuropathic* type [type III]. This synthetic classification allows having an overall clinical parameter that is nevertheless very useful, since LSDs occur in a broad and complex spectrum of phenotypes (Table 1).^{1,2}

This congenital disease is the result of a deficiency of the enzyme acid beta-glucosidase (ABG) that results in the accumulation of the sphingolipid glucosylceramide in the macrophages and gives rise to a heterogeneous systemic involvement. Damage of the bone tissue is a core part of it and the topic of this article, since the disease also results in Central Nervous System (CNS) compromise.³

Most patients have type I GD (non neuropathic) and the symptomatic manifestations vary considerably. Usually type I GD does not compromise the CNS and in ~50% of patients the diagnosis is made during childhood. Regarding bone involvement, the problems that occur range from osteopenia and pain to fractures in pathologic areas, osteonecrosis and long-term disability.⁴ Type II or *acute neuropathic* GD is the most severe form, and type III or subacute neuropathic or juvenile GD is an intermediate variant between types I and II.⁵

Gaucher's Disease in Mexico

In our country, the first records date from 1966 and were established by the hematologists and geneticists at «La Raza» National Medical Center, IMSS. Later, in 1991, the first multidisciplinary team for the management of this disease was formed. Since the number of cases was increasing, the first national consensus on the management of lysosomal storage diseases was held in the state of Querétaro. A general census was conducted then and it was found that the patients with GD lived in Sinaloa, Nuevo León, Michoacán,

Table 2. Statistics of the First National Consensus on Gaucher's Disease (Juriquilla, Querétaro, 2005).

Institution	Treated	Not treated	Total
IMSS	39	13	52
ISSSTE	4	1	5
PEMEX	1	1	2
SSA	0	7	7
SEDENA	0	1	1
State Institutions	0	0	0
Popular insurance	0	1	1
Total	44	24	68

Morelos, Jalisco, Puebla, Baja California Sur, Coahuila and México City. The incidence rate of GD was determined in seven healthcare facilities. A total of 68 cases were found, 52 of which corresponded to the IMSS, institution that treated 75% of them⁶ (Table 2).

In 2006 a highly-specialized center for the treatment of lysosomal storage diseases was started at «La Raza» National Medical Center, IMSS. Two years later, the registry at that hospital found that type I GD accounted for 90% of all cases, while types II and III affected 1 and 2%, respectively. Concerning the gender distribution, it is known that GD affects more than two fold female patients. Two clear examples of this are that of the ten cases reported in Monterrey City, six were females and four males; while among the seven cases reported in Mexico City, six were females and one male.

Diagnosis and treatment

The diagnosis of GD is made when there is an insufficient activity of the enzyme acid beta-glucosidase or ABG (EC 3.2.1.45). Moreover, the presence of Gaucher cells in the liver, lymph nodes and bone marrow biopsies contributes to make the diagnosis, but it is not better than the determination of enzyme levels. Despite all this, it is thanks to a research work done in Argentina (2002) that we can use dried blood spots in filter paper⁷ as a new alternative to perform enzyme counts that allows sample

delivery, retrospective diagnosis and population strategies. Thus the diagnosis should be confirmed with the leukocyte count and one should not forget that the enzyme activity levels among heterozygotes may overlap with normal ones. Therefore, enzyme determination with dried blood in filter paper may not be the best method to use among them. Likewise, it is essential to confirm the activity level of glucocerebrosidase before starting enzyme replacement therapy (ERT).¹

The glucocerebrosidase enzyme gene is a genetic factor that determines GD, since it is located in chromosome 1q21 and has 11 exons. 196 mutations have been identified, among which seven are the most frequent ones. Within the Ashkenazi Jewish population, the frequency of carriers is approximately 1/14, with 4 mutations that account for around 90% of the alterations: N370S, 84GG, L444P e IVS2+1.⁷ Among non-Jewish populations, the most common mutations are N370S, L444P, D409H, R463C and IVS2+1.¹ The detection of a single N370S allele excludes neurologic compromise, while the genotype L444P/L444P is indicative of a high risk of neuropathic disease. Thus the importance of performing molecular testing that show the presence or absence of the highest risk alleles, i.e., the L444P/L444P dyad and N370S/-, despite the fact that in the latter the other allele has not been identified.⁸ In patients with GD, activated macrophage chitotriosidase and its activity are both elevated. This is why it is the most sensitive indicator of the changes in the disease, and it is the preferred and recommended one.⁹

According to the cases recorded, it is known that the effectiveness of the imaging studies is variable and that the 100% sensitivity of magnetic resonance imaging (MRI) is preferred to the 40% provided by X-rays. Despite this, the high cost of MRI often times leads physicians and patients to use the X-ray bone series that is less expensive, readily available and allows paying for the ERT.

Both, MRI and the bone series allow determining the stage of GD and making the diagnosis. Although the most widely used radiologic criterion has been the one proposed by Herman et al. –diffuse osteoporosis, osteolysis, destruction and collapse– (1986),¹⁰ the Mexican evidence obtained from the cases studied by the author of this paper is enough to propose the following national classification (*Table 3*).

Table 3. National classification modified by Dr. Paul Blass Jaimes in 2005, IMSS.

Stage I	Medullary infiltrate
Stage II	Osteopenia
Stage III	Osteoporosis
Stage IV	Lytic areas in the medullary canal and areas of microinfarcts
Stage V	Femoral and humeral avascular necrosis, bone microinfarct in the distal femur
Stage VI	Fractures in pathologic areas (spine and long bones)

Enzyme replacement therapy (ERT)

ERT has been administered with the approval of the FDA since 1991 and it has modified the disease phenotype. However, given that this is a very complex condition with great heterogeneity among patients –even in siblings with the same genotype–, the response to ERT may vary. Its main objectives are to eliminate the bone crises; to prevent and delay osteopenia and osteoporosis; to prevent and diminish the fractures that occur in pathologic areas, and normalize the children's growth percentiles.¹¹ Therefore, given that the diagnosis during the first decades of life suggests severity and rapid progression and that patients with GD are at high risk of irreversible conditions –especially skeletal ones–,⁴ early treatment intervention with ERT may avoid the appearance of complications and may allow recovering the impaired functions when given at the right doses –continuous administration every 15 days– under medical surveillance at the hospital. Despite this, it is essential to remember that the discontinuation of therapy leads to absence of effectiveness.

Bone pathophysiology

At the bone level, GD originates in the bone marrow, site where the first Gaucher cells were observed. Its appearance increases the intramedullary mechanical pressure, an event that leads to the later development of the sequence of enzyme release, edema, ischemia, bone infarcts and fractures in pathological areas. Several systemic factors affecting osteoblasts and osteoclasts are involved in bone formation (corticosteroids, parathyroid hormone, prostaglandins, cytokines, platelet-derived growth factor) and, when affected by GD, those factors promote a bone remodeling associated with an abnormal osteoclastic function and bone infarcts.

In the case series of Mexican patients, the bone at the level of the femur and the spinal column is the most affected one (60 and 30%, respectively), with the humerus accounting for only 5%, the tibia 3%, and the hands and skull 2%. The extent of the bone damage associated with GD depends on factors like the type of GD (I, II, III), the genetic profile (1q21), the phenotype/genotype (N370S-L444P/L444P), the time of evolution prior to the diagnosis, whether the patient has been splenectomized or not, and, lastly, ERT, its dosing and the follow-up.

Likewise, the following bone variants common in patients with GD in Mexico were observed among the Mexican cases:

- Skull: microinfiltrate with density changes in the cortices in more than 60% of patients.
- Barrel chest: only in pediatric and adolescent patients: ages 7 to 15, with kyphosis and congenital scoliosis.
- Hands: signs of osteoporosis with osteopenic trabeculated bones and lytic zones in the metacarpals and phalanges.

Clinical case report

The clinical case reports of GD are often heterogeneous both in their clinical manifestations and in the diagnostic procedure and the treatment. However, in some series, like in this one, their evolution seems to be quite similar. Not all patients are fortunate enough to be timely diagnosed and referred to tertiary care centers or orthopedic specialized facilities. At these hospital facilities the case series are heterogeneous, as is the case of this report, because the information from the time of diagnosis is neither uniform nor abundant in most cases. The analysis of the following clinical cases intends to show the type of clinical management of the characteristics of each case. This will, in turn, show the disease course and its marked bone involvement, as well as its clinical management and treatment with ERT.

Comments on the clinical cases

The retrieval of these clinical cases often times shows a poor long-term follow-up of these patients in the national setting. Of the ten clinical cases presented herein, the objective record of the date of onset of GD management is available for only one case (10%), while the date of the diagnosis remains unknown in the remaining ones. This is a population composed of individuals from Monterrey City and Nuevo León (50%); the remaining 50% corresponds to patients from the Federal District.

Age and other characteristics (ERT)

The median age was recorded in 9 of the 10 patients (only 26.6 years), since most of the patients (> 70%) are in their 20's. A 15 year-old patient and a 52 year-old patient were included. The latter never received ERT and despite presenting with a normal skull, he also had very advanced bone impairment, with generalized osteopenia, avascular necrosis, osteoporosis of the proximal humerus, medullary infiltrate; the distal third of the femur with Erlenmeyer's flask deformity, with a bone infarction area and a gauchoma that ruptured the posteromedial cortex of the femur. This patient is, undoubtedly, an example of the impairment that occurs around the fifth decade of life when ERT is not administered to patients with GD. In this series, ERT was administered to 9 of the 10 patients always using the same drug (Cerezyme, Genzyme®); sometimes low doses were given. The drug used in all patients receiving active treatment in this review was the imiglucerase enzyme (± 10 U/kg every 2 weeks).

Diagnoses recorded

The diagnosis reported for these patients was Gaucher's disease; however, a couple of patients were recorded as *carriers* of GD and only two genotypes were involved: N370SS/L444P y N370SS. In some cases the diagnosis in-

cludes certain patient characteristics and the period during which they have been followed-up and received treatment for their bone complications. The symptoms reported during the bone crises (arthralgias, coxalgia, gonalgia, etc.) were also included. The basic data of this series of Mexican patients are as follows:

- Frequency by gender: 0% females/30% males.
- Findings in the skull: 50% of patients had a bone density in the thecal region showing a «salt and pepper» image; the remaining patients did not show changes in the skull.
- Findings in the hip: lateral and bilateral avascular necrosis (50%); lateral and bilateral epiphysiolisthesis (20%); coxa vara (30%).
- Findings in the femur: 90% with osteopenia and Erlenmeyer's flask deformity in the distal femur; osteoporosis (70%); bone infarct (30%); gauchroma with cortical rupture (10%), medullary infiltrate (10%).
- Findings in the spine: osteopenia (60%), transverse process/fractures in a pathological area (20%).
- Findings in the humerus: generalized osteopenia (100%); microinfarcts (30%); thickening of trabeculae (10%); osteoporosis (40%).
- Findings in the femur: osteopenia (100%), generalized osteopenia (40%), trabecular involvement in the metacarpals (80%), and microinfarcts (40%).
- Findings in the tibia and fibula: osteopenia (100%), osteoporosis (100%), subchondral sclerosis (30%), bone microinfarcts (20%), medullary infiltrate (30%).

Comments and summary of cases

Case 1

Female, 26 year-old patient with an unknown genotype, treated with low-dose ERT. Experiences bone crises two or three times per year. Skull with bone density in the thecal region showing a «salt and pepper» image (*Figure 1*), as well as the above mentioned set of symptoms. She is identified as a GD patient with severe bone damage and stage V of the national classification. A dose increase is recommended so as to revert the hematologic problems. The dose is increased to 120 units. The MRI does not show any medullary infiltrative activity (*Figure 1*).

Case 2

Male, 15 year-old patient with an unknown genotype and diagnosis of type I GD. The patient has an uncemented prosthesis in the right hip (*Figure 2*) due to avascular necrosis. There is medullary widening at the level of the tibia and fibula, with deformity of the bone edges at the metaphyseal level. This patient is stage V. The treating physician indicated continuation of ERT at 90 u/kg of body weight (*Figure 2*).

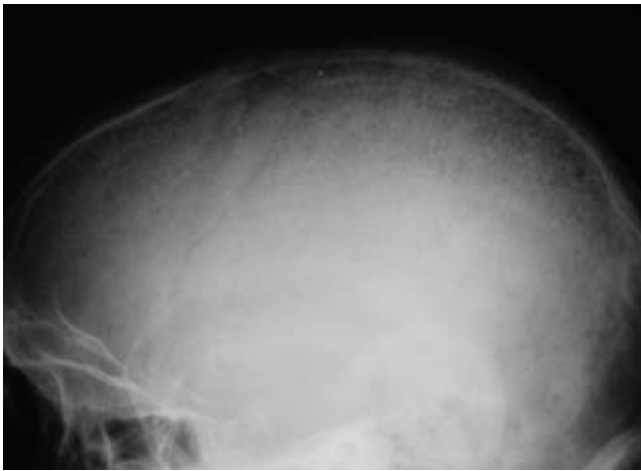


Figure 1. «Salt and pepper» changes in bone density.

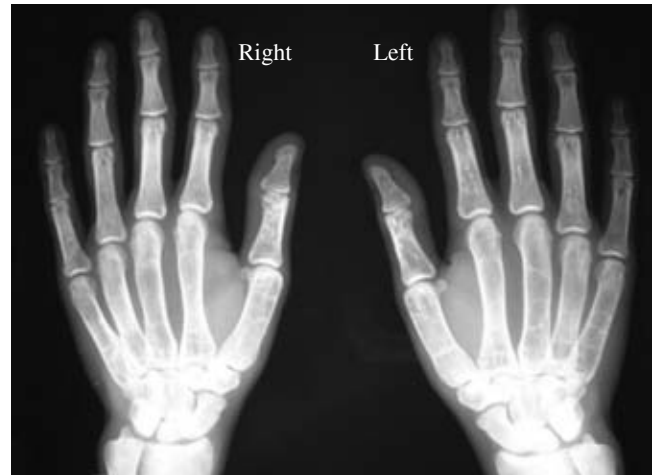


Figure 3. Bone involvement in the hands, an uncommon condition in the cases reported in the literature.

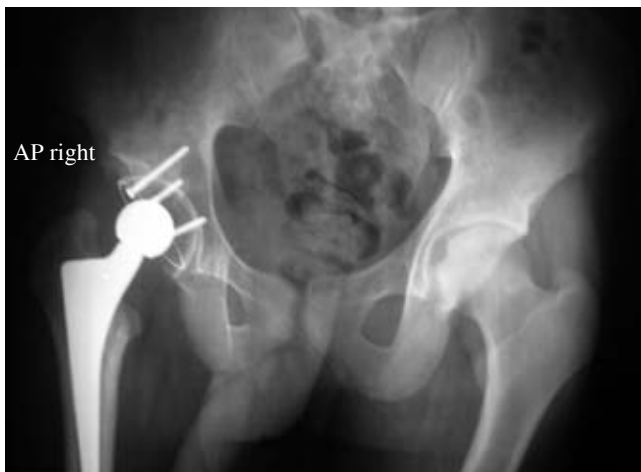

Figure 2. Uncemented right hip prosthesis due to avascular necrosis.

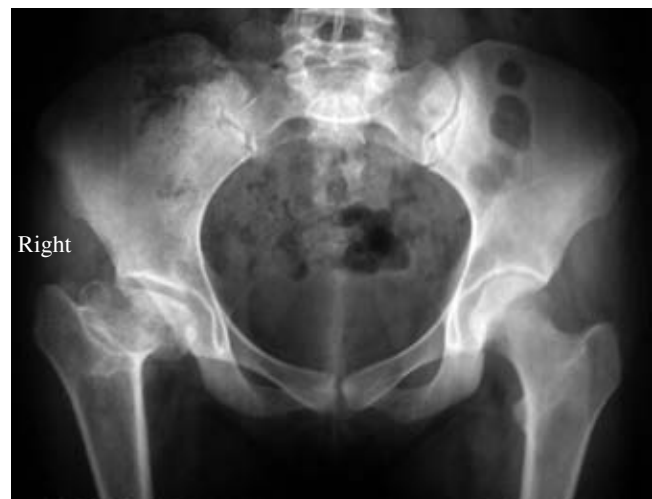

Figure 4. Right coxa vara.

Case 3

Female, 20 year-old patient with diagnosis of type I GD. She is on imiglucerase. Refers bone pain of the bone crisis type approximately twice per year with motion disability. The skull shows «salt and pepper» bone density changes. As with other patients, she has severe bone involvement in the hands (Figure 3), including bone microinfarcts and thickened trabeculae. The hip shows right femoral avascular necrosis and *coxa vara*. Also, her distal femur has the shape of an Erlenmeyer's flask - same as 100% of the patients. She is also classified as stage V. She is kept on 90 u/kg of body weight of ERT. Her course included femoral avascular necrosis with irreversible damage (Figure 3).

Case 4

Female, 24 year-old patient, with an unknown genotype. Her skull is reported as normal. Treated with imiglucerase as ERT. There is microinfiltration at the level of the femur

and the characteristics mentioned for most of the patients. The treating physician indicates continuation of 90 u/kg of body weight of imiglucerase. She has a *coxa vara* lesion on the right side (Figure 4).

Case 5

Female, 27 year-old patient, with a bone lesion due to stage I GD. Eligible for right uncemented total hip replacement. She is on imiglucerase-based ERT. Her skull is normal. There is microinfiltrate in the humerus. She has osteopenia and bilateral trabecular thickening predominantly in the metacarpals. *Coxa vara* deformity on the right side. The femur appears as in all patients with osteoporosis and Erlenmeyer's flask deformity (Figure 5), which is considered as a poor prognosis for her short term function. There are bone infarct zones in the distal femur, as well as a trend to develop a gauchoma. She

should continue with continuous infusions at minimum doses of 90 u/kg (*Figure 5*).

Case 6

Female, 24 year-old patient, with an unknown genotype. She is on ERT with imiglucerase due to the diagnosis of type I GD. She has symptomatic crises once a year with arthralgias, coxalgia and gonalgia. The skull shows a «salt and pepper» infiltrative process. Both hips show bone deformity of the femoral heads with avascular necrosis. Medullary infiltrate, osteopenia, osteoporosis with zones of microinfarcts in the distal region, changes in bone density due to bone infarcts, and subchondral sclerosis of the ankles (*Figure 6*), all of which leads to a poor prognosis of her short-term function. There are bone infarct zones in the distal femur, as well as a trend to develop a gauchoma. She should continue with continuous infusions at minimum doses of 90 u/kg.

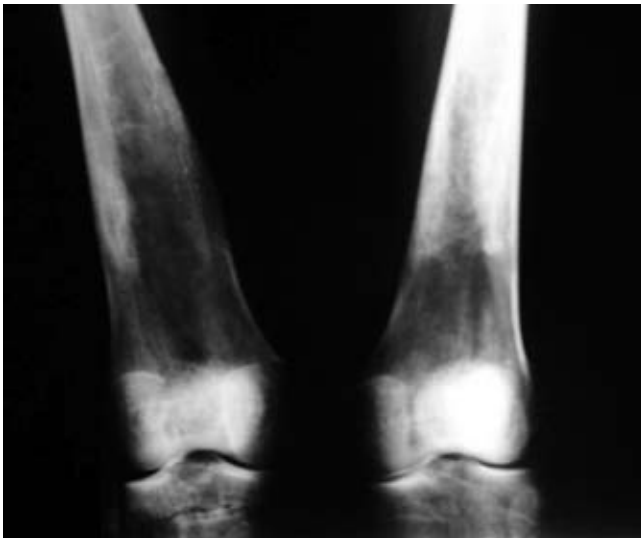


Figure 5. Bilateral Erlenmeyer's flask deformity with areas of bone microinfarct.

Case 7

Female, 20 year-old patient with minimum bone damage (type II lesions). She has been on ERT and has had osteopenia as the dominant symptom. This is the patient with the least involvement in the group, with a normal skull and without irreversible deformations. Her prognosis is very good under ERT at the standard dose (*Figure 7a and b*).

Case 8

Female, 28 year-old patient, with the N370SS/L444P genotype. She is on imiglucerase-based ERT. The skull shows «salt and pepper» bone density changes. The humerus shows microinfarcts, there are lytic zones in the humeral shaft and avascular necrosis of the left femoral head. The hip has bilateral avascular necrosis. She has sequelae of fractures in pathological areas on the greater

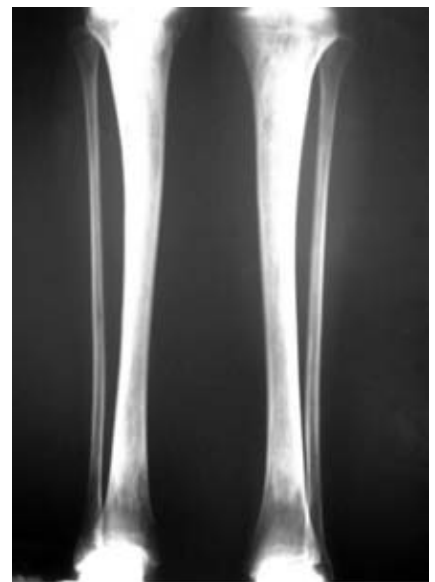

Figure 6. Changes in the distal density of the tibia with areas of bone microinfarct.

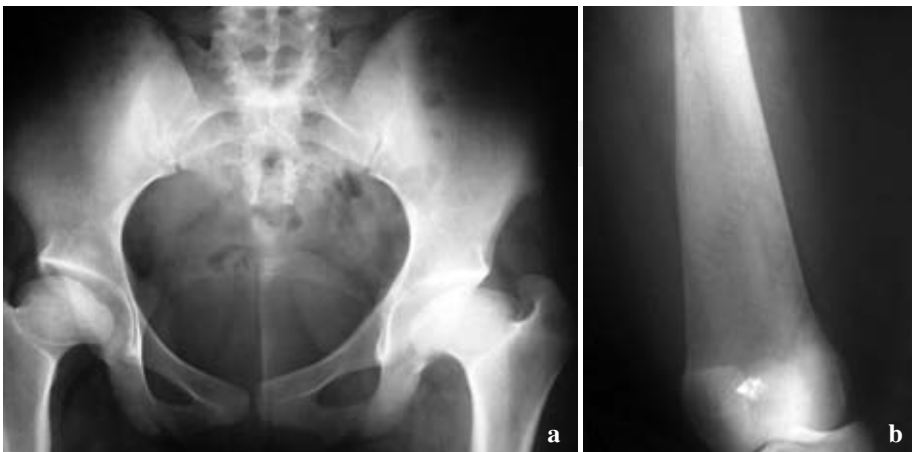

Figure 7 a. Bilateral coxa vara without avascular necrosis. **b.** Erlenmeyer's flask deformity of the femur.

trochanter in the right femur and *coxa vara* (Figure 8a). The patient's quality of life and functional prognosis are poor. She has recently received high-dose ERT, but the bone damage is already structured. She is considered as stage V (Figure 8b).

Case 9

Female, 47 year-old patient, with normal skull. She received the same ERT as the rest of the patients in the cohort. She sustained a fracture in a pathological zone of the left hip; the prosthesis placed five years ago has loosened. Bone damage is generalized, as has been reported for several areas. She was classified as bone stage V. She is being treated with the standard imiglucerase dose of 90 u/kg (Figure 9).

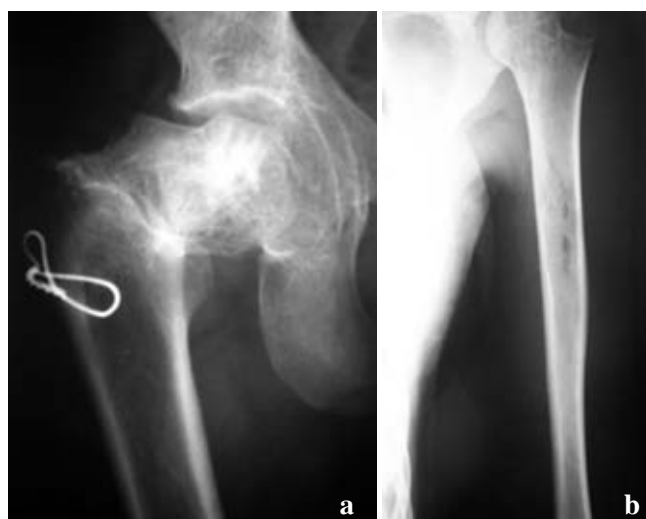

Figure 8 a. Fracture in a pathologic area, coxa vara, avascular necrosis. **b.** Small areas of bone microinfarcts, generalized osteopenia and avascular necrosis of the humeral head.

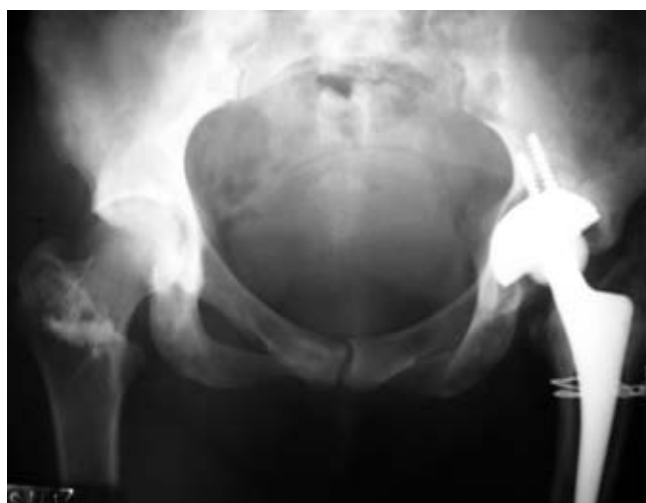

Figure 9. Right hip prosthesis with loosening.

Case 10

Male 53 year-old patient. He is genotype N370SS. He has never been treated with ERT and despite this has a normal skull. This patient has severe bone lesions with osteopenia and osteoporosis. He has a large necrotic bone infarct area in the right femur (Figure 10). His prognosis is very poor.

Discussion

So far there is relatively little knowledge among the clinicians treating the complications of lysosomal storage diseases. This is due, to a great extent, to the low incidence of these diseases, as well as to the very scarce information available about them in the literature until a decade ago. The current panorama includes biotechnologic drugs that positively modify the patients' course and quality of life. The so-called «orphan» products are medications that, thanks to public policies promoting their development and marketing, were designed to modify the course of these diseases.

This paper describes the condition of the patients affected by Gaucher's disease –specifically in the field of bone– as well as the benefit that enzyme replacement therapy represents. To the extent that the basic knowledge on these diseases is disseminated, together with the importance of a timely diagnosis and the relatively simple and very effective therapy that enzyme replacement represents, it will be possible to offer a better quality of life to these patients, diminish their complications and standardize the very unequal managements, like the ones described in this paper. Finally, we must say that one of the lags and challenges for the effective and decent treatment of lysosomal storage diseases in Mexico is the absence of a public policy for infrequent diseases in Mexico that includes the orphan drugs.

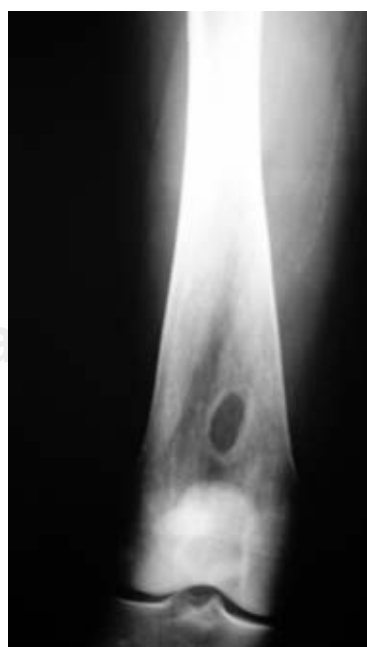


Figure 10. Erlenmeyer's flask deformity with a large area of bone infarct known as gauchoma.

References

1. Grabowski GA, Andria G, Baldellou A, Campbell PE, Charrow J, Cohen IJ, et al: Pediatric non-neuropathic Gaucher disease: presentation, diagnosis and assessment. Consensus statements. *Eur J Pediatr* 2004; 163(2): 58-66.
2. Beutler E, Grabowski G: Gaucher disease. In: Scriver CR, Baudet AL, Sly WS and Valle D (Eds). *The Metabolic & Molecular Bases of Inherited Disease*, 8th ed. Vol III, McGraw-Hill, New York, 2001: 3635.
3. Jmoudiak M, Futerman AH: Gaucher disease: pathological mechanisms and modern management. *Br J Haematol* 2005; 129(2): 178-88.
4. Charrow J, Anderson HC, Kaplan P, Kolodny EH, Mistry P, Pastores G, et al: Enzyme replacement therapy and monitoring for children with type I Gaucher disease: consensus recommendations. *J Pediatr* 2004; 144: 112-205.
5. Sidransky E, Sherer DM, Ginns E: Gaucher disease in the neonate: a distinct Gaucher phenotype is analogous to a mouse model created by targeted disruption of the glucocerebrosidase gene. *Pediatr Res* 1992; 32: 494-8.
6. Janssen-Cilag: IMSS. Consenso Nacional por Enfermedades por Depósito Lisosomal, 2005; 6-11 de Junio, Juriquilla, Querétaro, México.
7. Chamoles N, Blanco M, Gaggioli D, Casentini C: Gaucher and Niemann-Pick diseases –enzymatic diagnosis in dried blood spots on filter paper: retrospective diagnoses in newborn-screening cards. *Clin Chim Acta* 2002; 317: 191-7.
8. Barranger JA, Rice E, Sakallah SA, Sansieri C, Mifflin TE, Cooper DL. Enzymatic and molecular diagnosis of Gaucher disease. *Clin Lab Med* 1995; 15(4): 899-913.
9. Weinreb NJ, Aggio MC, Andersson HC, Andria G, Charrow J, Clarke JT, et al: International Collaborative Gaucher Group (ICGG). Gaucher disease type I: revised recommendations on evaluations and monitoring for adult patients. *Semin Hematol* 2004; 41(4 Suppl 5): 15-22.
10. Herman G, Goldblatt J, Levy RN, Goldsmith SJ, Desnick RJ, Grabowski GA: Gaucher's Disease type I: assessment of bone involvement by CT and scintigraphy. *Am J Roentgenol* 1986; 147: 943-8.
11. Charrow J, Dulisse B, Grabowski GA, Weinreb NJ: The effect of enzyme replacement therapy on bone crisis and bone pain in patients with type 1 Gaucher disease. *Clin Genet* 2007; 71: 205-11.