

Original article

Morphometric analysis of cervical pedicles in a Mexican population

Vargas-Mena R,* Dufoo-Olvera M,** García-López OF,*** López-Palacios JJ,***
 Aburto-Trejo JA,*** Carranco-Toledo GA****

Hospital General Villa, Mexico City Health Secretariat

ABSTRACT. Background: Knowledge of the morphometric anatomy of cervical pedicles is essential for the safe and accurate placement of pedicle screws during instrumentation of the cervical spine. Screw placement in the lumbar and thoracic vertebrae is considered as a safe practice, unlike the cervical vertebrae due to the risks involved. There are few reports on this technique. The little available information comes from populations different from the Mexican population. Knowing the measurements of each cervical vertebra will provide proper screw orientation and selection at the time of screw placement. **Methods:** Prospective, cross-sectional, descriptive study in subjects who presented at the outpatient and emergency services. Patient's in whom a CAT scan of the cervical spine was ordered as part of the work-up protocol, from April 1st 2010 to October 31st 2010, were included. A morphometric anatomic study was undertaken using the CAT software. In a sagittal view: a) Sagittal angle, b) Sagittal diameter. In an axial view: a) Work distance, b) Cross-sectional angle and c) Cross-sectional diameter. **Results:** The following measurements were obtained for each segment from C2 to C7: mean, standard deviation, range and minimal and maximal values. **Conclusions and clinical relevance:** Appropriate preoperative planning prior to cervical transpedicular instrumentation is essential to achieve greater accuracy during screw

RESUMEN. Antecedentes: El conocimiento de la anatomía morfométrica de los pedículos cervicales es esencial para una colocación segura y precisa de tornillos transpediculares en la instrumentación de la columna cervical. Se ha considerado una práctica segura la colocación de tornillos en las vértebras lumbares y torácicas, no así en las cervicales por los riesgos que conlleva. Existen pocos reportes de esta técnica. La escasa información disponible está dada en poblaciones disímiles a la mexicana. Conocer las mediciones de cada vértebra cervical nos permitirá la adecuada orientación y selección de tornillos al momento de su colocación. **Métodos:** Estudio prospectivo, transversal, descriptivo, en sujetos que acudieron a consulta externa y urgencias. Se incluyeron a quienes fue solicitada TAC de columna cervical como parte del protocolo de estudio, entre Abril 1 de 2010 a Octubre 31 de 2010. Se realizó un estudio anatómico morfométrico, obteniéndose mediante el software del TAC. En un corte sagital: a) Ángulo sagital y b) Diámetro sagital. En un corte axial: a) Distancia de trabajo, b) Ángulo transversal y c) Diámetro transversal. **Resultados:** Se obtuvieron cifras de media, desviación estándar y rango y valores mínimos y máximos para cada segmento de C2 a C7. **Conclusiones e importancia clínica:** Es primordial una planificación preoperatoria adecuada antes de una instrumentación transpedicular cervical para lograr mayor pre-

Level of evidence: IV (Act Ortop Mex, 2011)

* Spine surgeon. Former resident at the Mexico City Center for Spinal Cord Injured Patients (CALRM, for its acronym in Spanish).

** Head, CALRM.

*** Staff physician, CALRM.

**** Head of Rehabilitation, CALRM.

Please address all correspondence to:

Dr. Rodrigo Vargas Mena

Calle 36 Núm. 428 x33 y 35 Col. Jesús Carranza. Mérida, Yucatán. C.P. 97109

E-mail: rodrigovargasmena@hotmail.com

Este artículo puede ser consultado en versión completa en <http://www.medigraphic.com/actaortopedica>

placement. The information obtained allows performing the procedure. As a result of this, a report based on out center's experience may be disseminated thus sharing our technique with the medical community.

Key words: anatomy, vertebra, morphology, population, Mexico.

cisión al momento de la colocación de tornillos. Con base en la información obtenida se puede llevar a la práctica el procedimiento, lo que permita difundir un reporte basado en la experiencia de nuestro centro, compartiendo con la comunidad médica nuestra técnica.

Palabras clave: anatomía, vértebra, morfología, población, México.

Introduction

Knowledge of the morphometric anatomy of cervical pedicles is essential for the safe and accurate placement of pedicle screws when instrumenting the cervical spine.

Pedicle screw placement in the lumbar and thoracic vertebrae is considered as a safe practice, unlike the cervical vertebrae.

Pedicle fixation is considered biomechanically superior than instrumentation with wire, lateral mass screws and configurations with rods and hooks. An optimum knowledge of the anatomy and morphometry of cervical pedicles is necessary for the appropriate placement of cervical pedicle screws.¹

Clinical results have shown that cervical pedicle screw fixation results in better stabilization, but due to the higher risk of neurovascular injury during screw insertion, there are only a few clinical reports of this technique.²

The greater stability offered by the placement of screws in the cervical spine may be explained by the greater screw-bone interface resulting from the longer tract inside the pedicle and the vertebral body.³

The clinical application of pedicle fixation in the cervical spine is technically demanding and has a limited use. Critical structures are found nearby and there is an important variation in the morphometry of cervical pedicles.⁴

Rampersaud et al. report that in the case of the subaxial cervical spine, the cervicothoracic junction, and the upper thoracic spine there is a maximum permissible translational error <1 mm and a rotational error < 5°.

When screws are used, pedicle perforation rates, including critical and non-critical ones, range between 25 and 87.5% depending on the series.⁵

Karaikovic et al. found 17% of pedicle perforations with the funnel technique; Kasegawa et al. found complications in 17.2% of patients doing decompression followed by screws, and Ludwig et al. reported a 24% failure rate with a navigation assisted technique.⁶

It is difficult to define the critical width at which the wrong screw positioning rate becomes unacceptably high. Critical perforations have been reported in pedicles of up to 6 mm in diameter.⁷

The reported pedicle perforation incidence is lowest in C2 and highest in C4; the next highest one is observed in C7.

The vertebral artery does not occupy the entire transverse foramen area, so the pedicle screws perforating laterally will not necessarily injure that structure.

The reported neurovascular complication rate due to screw insertion in cervical pedicles is 1.7% of patients and 0.4% of the screws inserted in a different series. Complications may be reduced with sufficient preoperative images of pedicles.⁸

Material and methods

This is a prospective, cross-sectional and descriptive study conducted in patients over 18 years of age, who presented at the outpatient service and the emergency room.

The sample was determined out of convenience. All patients in whom a cervical spine CAT scan was requested as part of their work-up were included, from April 1st to October 31st, 2010.

An anatomic-morphometric study was done with axial and sagittal views, with a PHILIPS BRILLIANCE 16-slice computed axial tomography equipment. The following measurements were obtained from C2 to C7 with the equipment software:

In a sagittal view:

- Sagittal angle. Angulation of the pedicle sagittal angle and the upper border of the vertebral body.⁹
- Sagittal diameter (pedicle height). Superoinferior diameter of the narrowest portion of the pedicle isthmus (*Figure 1*).

In an axial view:

- Work distance. Distance from the pedicle point of entry to the anterior vertebral cortex.
- Cross-sectional angle. Angulation of the pedicle axis with respect to the sagittal midline.
- Cross-sectional diameter (pedicle width). Mid-lateral diameter of the narrowest portion of the pedicle isthmus (*Figure 2*).

Measurements were made by staff of the Radiology Department at the hospital, using the MxLite View DICOM




Figure 1. Measurements in the sagittal view.

Viewer by Philips, version 1.24.0, an image visualization system. The interpretation of the images was done by the Head of the Radiology Service. All data were recorded in a spreadsheet.

Inclusion criteria

1. Patients of any sex.
2. Patients over 18 years of age.
3. Patients presenting at the Imaging Diagnosis Department for a cervical spine CAT scan as part of their diagnostic protocol due to a traumatic or non-traumatic condition.

Exclusion criteria

1. Patients with a history of cervical spine pathology regardless of the etiology.
2. Patients with contraindications for a CAT scan.

Elimination criteria

1. Patients without a history of vertebral pathology in whom anatomical abnormalities of cervical pedicles are found.
2. Patients without appropriate imaging and measurements.
3. Patients without complete images of the cervical spine from C2 to C7.
4. Patients with any kind of fracture from C2 to C7.

All the data collected were entered into a spreadsheet and statistical software was used. Figures were obtained for the following: mean standard deviation and range, as well as minimum and maximum values for each vertebral segment from C2 to C7.

Results

CAT scan images were obtained in 34 patients who presented at the outpatient and emergency services with vari-

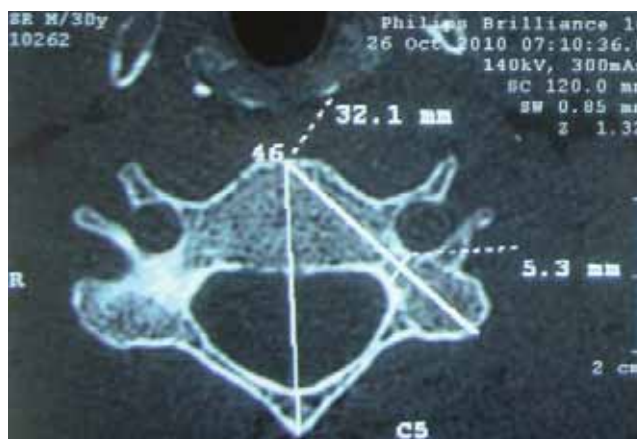


Figure 2. Measurements in the axial view.

ous presumed diagnoses and in whom bone pathology was ruled out. Only the imaging studies having complete images of the entire cervical spine, with appropriate sections, were recorded. A total of 204 vertebrae were studied.

Two patients were excluded: one with important arthrotic changes preventing proper visualization of the structures and, therefore, measurements; and a patient with hypoplastic pedicles in C2, without history of any malformation or added pathology.

Mean and standard deviation values were obtained for the cross-sectional angle, which was $43.96^\circ (\pm 2.35^\circ)$ for C2, with a minimum value of 40 and a maximum of 49, with a range of 9° . For C3 it was $42.11^\circ (\pm 2.46^\circ)$, with a minimum of 38 and a maximum of 47.3, and a range of 9.3° . For C4 it was $44.79^\circ (\pm 2.63^\circ)$, with a minimum of 41.2 and a maximum of 50.6, and a range of 9.4° . For C5 it was $44.77^\circ (\pm 1.87^\circ)$, with a minimum of 42.1 and a maximum of 48.7, and a range of 6.6° . For C6 it was $42.40^\circ (\pm 1.89^\circ)$, with a minimum of 38.8 and a maximum of 45.6, and a range of 6.8° . For C7 it was $38.02^\circ (\pm 2.46^\circ)$, with a minimum of 32 and a maximum of 40.9, and a range of 8.9° .

The measurement of the work distance yielded mean and standard deviation values: For C2 it was 29.13 mm (± 1.03 mm), with a minimum of 27.1 and a maximum of 30.9, and a range of 3.8 mm. For C3 it was 32.05 mm (± 2.2 mm), with a minimum of 28.8 and maximum of 37.4, and a range of 8.6 mm. For C4 it was 31.39 mm (± 1.39 mm), with a minimum of 29 and a maximum of 34, and a range of 5 mm. For C5 it was 32.55 mm (± 1.71 mm), with a minimum of 28.7 and a maximum of 36.7, and a range of 8 mm. For C6 it was 33.19 mm (± 1.52 mm), with a minimum of 30.1 and a maximum of 37.3, and a range of 7.2 mm. For C7 it was 35.12 mm (± 2.2 mm), with a minimum of 29.1 and a maximum of 38, and a range of 8.9 mm (Chart 2).

The mean and standard deviation values for the cross-sectional diameter were: For C2 4.9 mm (± 0.41 mm), with a minimum of 4 and a maximum of 5.9, and a range of 1.9 mm. For C3 4.27 mm (± 0.49 mm), with a minimum of 3.3 and a maximum of 5.1, and a range of 1.8 mm. For C4 4.33

mm (± 0.37 mm), with a minimum of 3.6 and a maximum of 5.1, and a range of 1.4 mm. For C5 5.03 mm (± 0.49 mm), with a minimum of 4.1 and a maximum of 5.9, and a range of 1.8 mm. For C6 5.42 mm (± 0.38 mm), with a minimum of 4.6 and a maximum of 6.2, and a range of 1.6 mm. For C7 it was 6.27 mm (± 0.54 mm), with a minimum of 5.1 and a maximum of 7.1, and a range of 2 mm (Chart 3).

Mean and standard deviation values were obtained for the sagittal angle, which was 22.25° ($\pm 1.74^\circ$) for C2, with a minimum value of 18.9 and a maximum of 25.1, with a range of 6.2° . For C3 it was 11.87° ($\pm 0.96^\circ$), with a minimum of 10.2 and a maximum of 13.9, and a range of 3.5° . For C4 it was 12.12° ($\pm 1.04^\circ$), with a minimum of 10.1 and a maximum of 13.9, and a range of 3.8° . For C5 it was 11.03° ($\pm 1.38^\circ$), with a minimum of 8.5 and a maximum of 14, and a range of 5.5° . For C6 it was 10.38° ($\pm 1.37^\circ$), with a minimum of 7 and a maximum of 12.4, and a range of 5.4° . For C7 it was 13.08° ($\pm 1.15^\circ$), with a minimum of 11.3 and a maximum of 15.4, and a range of 4.1° (Chart 4).

Mean and standard deviation values for the sagittal diameter were for C2 9.26 mm (± 1.08 mm), with a minimum value of 6.2 and a maximum of 11, and a range of 4.8 mm. For C3 it was 6.33 mm (± 0.65 mm), with a minimum of 5.7 and a maximum of 7.8, and a range of 2.1 mm. For C4 it was 6.8 mm (± 0.69 mm), with a minimum of 5.9 and a maximum of 8.1, and a range of 2.2 mm. For C5 it was 5.58 mm (± 0.36 mm), with a minimum of 4.9 and a maximum of

6.2, and a range of 1.2 mm. For C6 it was 6.11 mm (± 0.34 mm), with a minimum of 5.5 and a maximum of 6.7, and a range of 1.2 mm. For C7 it was 6.19 mm (± 0.7 mm), with a minimum of 4.9 and a maximum of 7.3, and a range of 2.4 mm (Chart 5).

Discussion

Thirty-four patients were included and 204 vertebrae were measured, which resulted in a sample larger than the reports by Karaikovic et al. (10 cadavers, 60 vertebrae),⁷ Pai et al. (30 cadavers, thoracic vertebrae),¹⁰ Ebraheim et al. (160 vertebrae from 40 cadavers),¹ Bozbuga et al. (29 cadavers, 145 vertebrae),¹¹ Datir et al. (18 cadavers, thoracic vertebrae),¹² McLain et al. (18 cadavers, thoracic vertebrae),¹³ Ludwig et al. (14 cadavers),¹⁴ Kim et al. (10 cadavers),¹⁵ and Sakamoto et al. (30 patients, 150 vertebrae).¹⁶ The largest study found is another one by Karaikovic et al., which measured 53 cadavers.

Based on the values obtained for all the vertebrae studied in the measurements performed, we observed that in order to place pedicle screws in the cervical segments there needs to be convergence of screws in the sagittal plane with respect to the midline, of a mean of 43.9° for C2, 42.1° for C3, 44.7° for C4, 44.7° for C5, 42.4° for C6, and 38° for C7. It is necessary to tilt the screw cranially or caudally, in the axial or cross-sectional plane, 22.2° for C2, 11.8° for C3, 12.1° for C4, 11° for C5, 10.3° for C6, and 13° for C7.

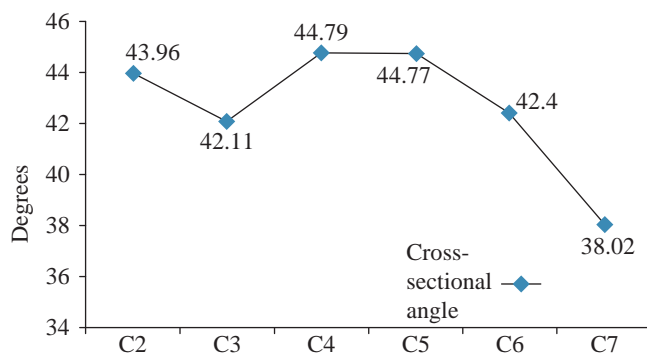


Chart 1. Mean of the cross-sectional angle values.

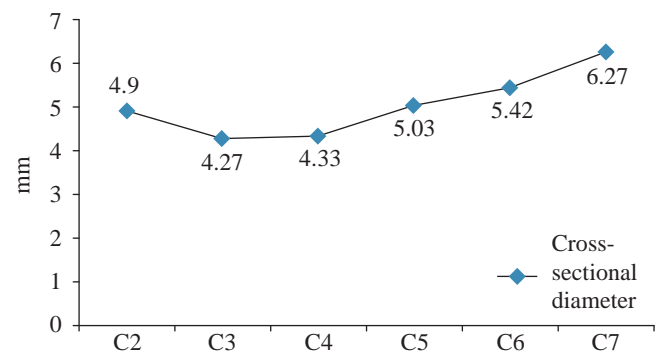


Chart 3. Mean of the cross-sectional diameter values.

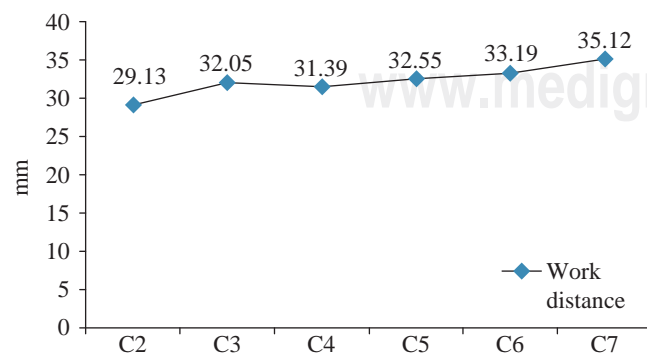


Chart 2. Mean of the work distance values.

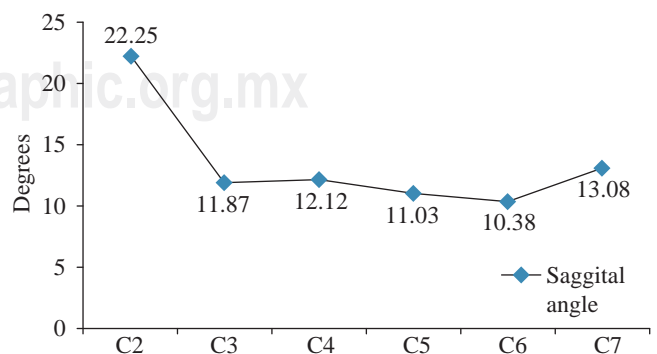


Chart 4. Mean of the sagittal angle values.

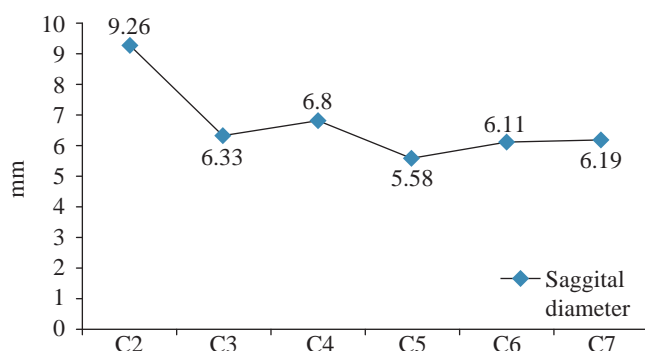


Chart 5. Mean of the sagittal diameter values. Sagittal diameter.

Concerning the screws that may be safely placed in the cervical spine, their maximum length in C2 is a mean of 29.1 mm, 32 mm for C3, 31.3 mm for C4, 32.5 mm for C5, 33.1 mm for C6, and 35.1 mm for C7. The mean maximum diameter that may be used for C2 is 4.9 mm, for C3 4.2 mm, for C4 4.3 mm, for C5 5 mm, for C6 5.4 mm, and for C7 6.2 mm.

The knowledge of the anatomy of the cervical pedicles in a living and healthy population in our country gives us a close idea of the needs regarding the material to use and the difficulties to be encountered at the time of posterior transpedicular cervical instrumentation.

The sample obtained in this study exceeds the ones used in most of the reports of similar studies, therefore, the validity of the data obtained is reliable.

Preoperative planning with appropriate images is essential before attempting transpedicular instrumentation of the cervical spine. The reduced margin of error that characterized such instrumentation results in the need for the greatest possible precision to avoid harming the sensitive and vital structures located near the pedicles.

The diameter of the screws used in the cervical spine ranges from 3.5 to 4.5 mm, which would allow us to place 4.0 mm screws for C3 and C4, and, for the remaining segments, 4.5 mm screws in general.

The placement of either transface or transpedicular screws is done freehand, relying on the surgeon's skill and precision, unless computer navigation equipment is available. However, the latter is quite expensive and unlikely to be used in our setting. Due to this, an extensive knowledge of the surgical anatomy of the cervical vertebrae and ample experience in screw placement in this region with any of the previously described techniques are recommended. It is therefore necessary to design screw placement instruments that allow for greater precision in this area. The results of this study may contribute to this.

The information obtained allows performing the procedure addressed herein. As a result of this, a report of cases based on our center's experience may be disseminated thus sharing our technique with the medical community.

References

1. Ebraheim N, Xu R, Knight T, Yeasting R: Morphometric evaluation of lower cervical pedicle and its projection. *Spine* 1997; 22: 1-6.
2. Hasegawa K, Hirano T, Shimoda H, Homma T, Morita O: Indications for cervical pedicle screw instrumentation in nontraumatic lesions. *Spine* 2008; 33: 2284-9.
3. Kothe R, R  tther W, Schneider E, Linke B: Biomechanical analysis of transpedicular screw fixation in the subaxial cervical spine. *Spine* 2004; 29: 1869-75.
4. Kowalski J, Ludwig S, Hutton W, Heller J: Cervical spine pedicle screws. A biomechanical comparison of two insertion techniques. *Spine* 2000; 25: 2865-7.
5. Kramer DL, Ludwig SC, Balderston RA, et al: Placement of pedicle screws in the cervical spine: Comparative accuracy of cervical pedicle screw placement using three techniques. *Orthop Trans* 1997; 21: 484.
6. Hasegawa K, Hirano T, Shimoda H, Homma T, Morita O: Indications for cervical pedicle screw instrumentation in nontraumatic lesions. *Spine* 2008; 33: 2284-9.
7. Karaikovic E, Yingsakmongkol W, Gaines R: Accuracy of cervical pedicle screw placement using the funnel technique. *Spine* 2001; 26: 2456-62.
8. Abumi K, Yasuhiro S, Ito M, Taneichi H, et al: Complications of pedicle screw fixation in reconstructive surgery of the cervical spine. *Spine* 2000; 25: 962-9.
9. Olsewski JM, Simmons EH, Kallen FC, et al: Morphometry of the lumbar spine: anatomical perspectives related to transpedicular fixation. *J Bone Joint Surg Am* 1990; 72: 541-9.
10. Pai BS, Gangadhara, Nirmala S, Muralimohan S, Varsha SM: Morphometric analysis of the thoracic pedicle: An anatomic-radiological study. *Neurol India* 2010; 58: 253-8.
11. Bozbuga M, Ozturk A, Ari Z, et al: Morphometric evaluation of subaxial cervical vertebrae for surgical application of transpedicular screw fixation. *Spine* 2004; 29: 1876-80.
12. Datir S, Mitra S: Morphometric study of the thoracic vertebral pedicle in an Indian population. *Spine* 2004; 29: 1174-81.
13. McLain R, Ferrara L, Kabins M: Pedicle morphometry in the upper thoracic spine—Limits to safe screw placement in older patients. *Spine* 2002; 27: 2467-71.
14. Ludwig S, Kramer D, Balderston R, Vaccaro A, et al: Placement of pedicle screws in the human cadaveric cervical spine. Comparative accuracy of three techniques. *Spine* 2000; 25: 1655-67.
15. Kim HS, Heller J, Hudgins P, Fountain J: The accuracy of computed tomography in assessing cervical pedicle screw placement. *Spine* 2003; 21: 2441-6.
16. Sakamoto T, Neo M, Nakamura T: Transpedicular screw placement evaluated by axial computed tomography of the cervical pedicle. *Spine* 2004; 29: 2510-4.
17. Rampersaud R, Simon D, Foley K: Accuracy Requirements for Image-Guided spinal pedicle screw placement. *Spine* 2001; 26: 352-9.
18. Karaikovic E, Daubs M, Madsen R, Gaines R: Morphologic characteristics of human cervical pedicles. *Spine* 1997; 22: 493-500.