

## Techniques and procedures

## Description of an arthroscopic and percutaneous technique to repair posterolateral corner knee lesions

Ayala-Mejías JD,\* García-Estrada GA,\*\* Rodríguez-Hernández C,\*\*\* del-Monte-Bello G\*\*\*

Traumatology, Orthopedic Surgery and Rehabilitation Monographic Hospital ASEPEYO.  
Lomas Verdes Orthopedics and Traumatology Hospital. IMSS

**ABSTRACT.** Posterolateral corner knee lesions are infrequent and very disabling. They usually occur with other ligament lesions, so historically different techniques have been used to reconstruct this kind of lesions. Most of them involve open surgery, with the Clancy procedure as one of the most popular ones. After thorough preoperative planning taking into account the patient's activities, we propose a new arthroscopic and percutaneous technique based on Clancy's procedure, using a calcaneal tendon or quadriceps allograft.

**Key words:** knee, arthroscopy, technique, reconstruction.

**RESUMEN.** Las lesiones de esquina posterolateral de rodilla son infrecuentes y muy incapacitantes. Normalmente se acompañan de otras lesiones ligamentarias; por lo que históricamente se han realizado distintas técnicas para reconstruir este tipo de lesiones. La mayor parte de ellas son practicadas por cirugía abierta, una de las más populares es la de Clancy, por lo que después de una detallada planificación quirúrgica y teniendo en cuenta la actividad del paciente, proponemos una nueva técnica artroscópica y percutánea basada en la de Clancy, utilizando un aloinjerto de tendón calcáneo o cuádriceps.

**Palabras clave:** rodilla, artroscopía, técnica, reconstrucción.

### Introduction

Posterolateral corner knee lesions are infrequent but very disabling. That is why a definitive procedure to treat them is necessary because, without the right initial treatment, patients may have chronic instability and severe chondral lesions.<sup>1-5,6</sup>

### Nivel de evidencia: IV (Act Ortop Mex, 2011)

\* Physician specializing in Orthopedics and Traumatology, with subspecialty in Arthroscopy. ASEPEYO. (Traumatology, Orthopedic Surgery and Rehabilitation Monographic Hospital).

\*\* 4<sup>th</sup> year resident of Orthopedics and Traumatology. Lomas Verdes Traumatology and Orthopedics Hospital, UMAE.

\*\*\* 1<sup>st</sup> year resident of Orthopedics and Traumatology.

Please address all correspondence to:

Dr. Juan Diego Ayala Mejías.

Joaquín de Cárdenas 2, C.P. 28820. Coslada, Madrid, España.

Phone(s): (+34916735011) Celular: (+34636979616).

E-mail: jayalamejias@asepeyo.es

Este artículo puede ser consultado en versión completa en <http://www.medigraphic.com/actaortopedica>

For this reason, multiple surgical techniques have been developed for the treatment of posterolateral corner knee lesions trying to correct instability, posterior translation, varus opening, and lateral tibial rotation.<sup>2,4,7,8</sup>

Following the commonly used techniques for the repair of posterolateral corner knee lesions, we developed a new arthroscopic and percutaneous technique, based on Clancy's technique,<sup>9</sup> using Achilles or quadriceps tendon allograft.<sup>1,6,9-16</sup>

### Pathogenesis

Posterolateral corner lesions are classified into 3 types: traumatic, physiologic or combined, with the latter presenting with lateral knee hyperrotation. They are usually secondary to severe knee trauma, with lateral structures being injured together with the anterior cruciate ligament (ACL), the posterior cruciate ligament (PCL) or both.<sup>17,13</sup>

### Anatomy

To maintain the stability of the posterolateral corner of the knee a complex system composed of muscles,

ligaments and tendons is required. The latter include the popliteal muscle, the femoral biceps tendon and the lateral gastrocnemius muscle, all of which are dynamic stabilizers. The lateral collateral ligament (LCL), the tibiofibular ligament (TFL), the arcuate ligament (AL), the popliteofibular ligament (PFL), and the posterolateral capsule are static stabilizers. These structures play an important role on posterolateral knee stabilization and avoid posterior translation, varus angulation and excessive lateral rotation.<sup>6,17-21</sup>

## Diagnosis

### Clinical assessment

During an acute knee injury it is very complicated to properly assess the patient, so we have to wait until the patient is doing better, as these injuries may be missed and the patient may develop complications associated with this condition. The patient usually returns to see the physician complaining of instability upon walking and pain, which warrants exploring the patient again.

The diagnosis is made by means of a neutral posterior drawer that does not decrease upon medial tibial rotation; grade III «tier» sign; lateral gap in full extension and 30° of flexion, and increase in lateral rotation of the extremity at 30° and 90° of flexion.

The reverse pivot shift maneuver is positive whenever there is the sensation of reduction in the knee when it is flexed and rotated laterally and then extended *in valgus* under stress. The posterolateral drawer maneuver in which the knee is flexed at 80° and the foot is rotated laterally at 15° assesses shift and lateral rotation of the lateral tibial plateau.<sup>13,20</sup>

### Diagnostic aids

Basic X-rays include anteroposterior (AP) and lateral knee X-rays with the patient standing up. Nuclear magnetic resonance imaging (NMRI) should be ordered to confirm the clinical diagnosis.

## Treatment

### Allograft preparation

Initially the Achilles or quadriceps tendon allograft is thoroughly assessed to detect a lesion or defect; then the tendon is measured longitudinally together with the bone chip and bent over itself to create the planned diameter. Then one end of the bone chip is cut so that it matches the already prepared allograft; at the other end #5 strong sutures are placed and pulled to provide the necessary tension to the graft, thus achieving a uniform allograft diameter. Once this is over, it is passed through a gauge thus obtaining a tendon 7-8 mm in diameter.<sup>4,11,14</sup>

## Surgical technique

With the patient in dorsal decubitus and under general anesthesia or epidural block, the injured leg is placed on a holder; after placing an ischemia cuff in the proximal thigh the blood is removed and ischemia is applied at 280-300 mmHg. Then asepsis is done and sterile drapes are put in place. Knee arthroscopy is started to find other lesions associated with the posterolateral corner lesion, particularly lesions of both cruciate ligaments or of the posterior cruciate ligament.

### Tibial tunnel

Once knee arthroscopy has been performed, the tibial tunnel is made by placing a tibial guide for the ACL at 45°. The knee is placed at 90°; then the guide is introduced through the anterolateral portal and the arthroscope is placed in the posterolateral portal to watch the proper placement of the tibial guide, approximately 20 mm below and behind the lateral tibial plateau (articular line), as well as to observe the popliteal musculotendinous complex (*Figures 1A and 1B*).

Once the proper placement of the guide has been confirmed (*Figure 1A*), perforations are made with a 2.0 Kirschner nail (*Figures 2A and 2B*), then the tibial tunnel is drilled with a 7 mm drill bit (depending on the graft thickness) (*Figures 3A and 3B*).

### Femoral tunnel

The next step is drilling the femoral bone tunnel. First, a perforation is made with a 2.0 intercondylar Kirschner nail, then the cross-sectional 8 x 30 mm tunnel is drilled blindly as well as a long 5 mm in diameter tunnel that goes through the entire femoral metaphysis (*Figures 4A and 4B*).

A subcutaneous dissection is performed from the epicondyle to the posterolateral portal for passing the graft (*Figure 5*).

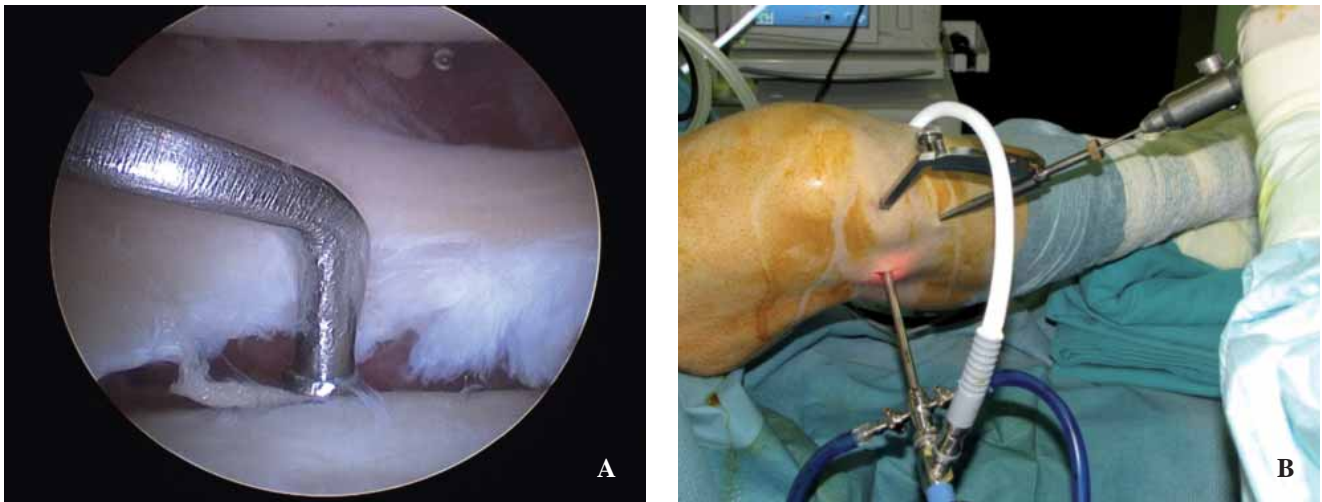
The graft is passed from the posterolateral portal to the femoral tunnel and the tibial tunnel from the back to the front leaving the allograft bone chip placed in the femoral bone tunnel (*Figures 6A and 6B*), the former is then fixed in the tunnel with a 7 x 20 mm interference screw. Distal tibial fixation is performed with a bone plug and two 6 mm Richards staples correcting the posterolateral drawer and maintaining the tension of the allograft. The right placement of the graft is observed arthroscopically, a drain is placed and the wound is closed (*Figures 7A, 7B and 7C*).

Finally, the right isometry is confirmed in flexion and extension from 0° to 90°, and a brace is placed in full extension. A final control X-ray is requested (*Figure 8*).

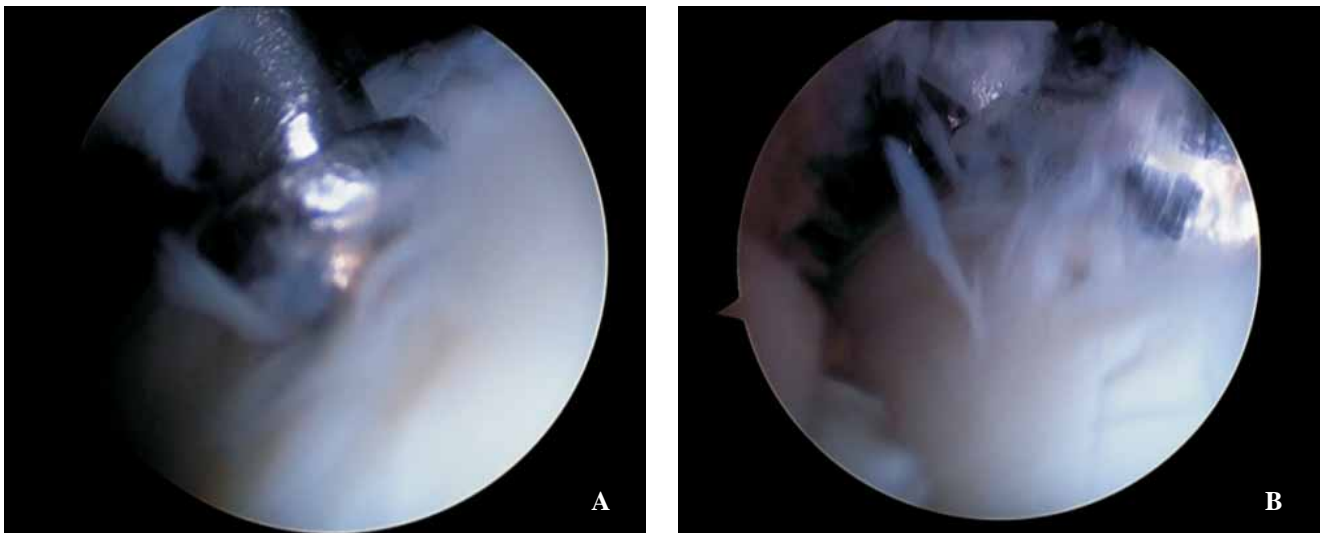
### Clinical case

Male, 50 year-old patient, machinist, from Madrid, Spain.

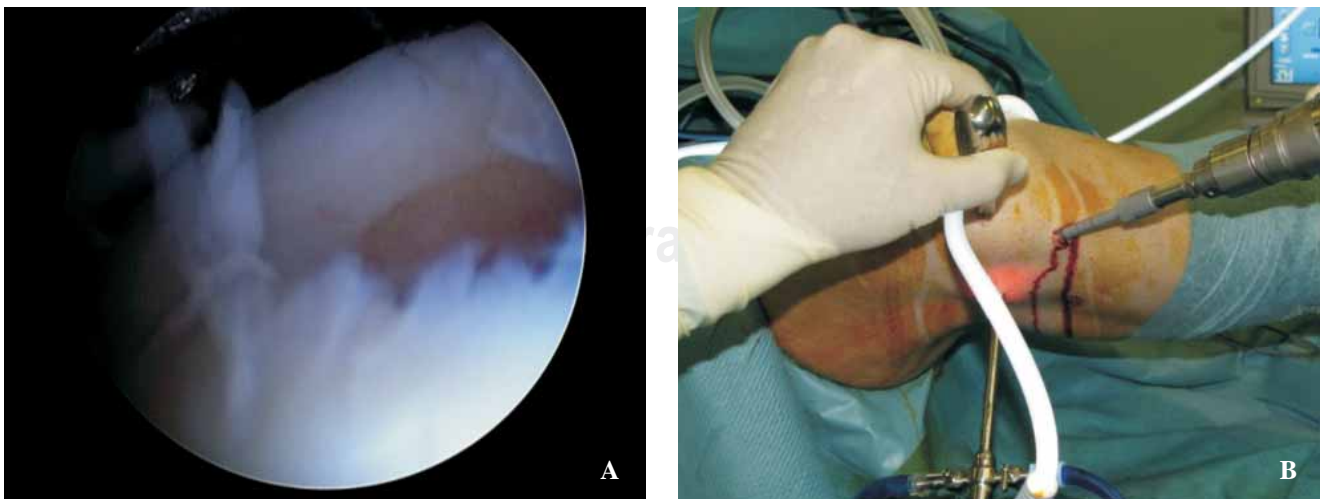
Current condition: He reported that on 07/12/2010 when he was at work doing public works he fell from a height of



**Figures 1A and B.** Placement of the cruciate guide through the anteromedial portal (arthroscopic and lateral view).

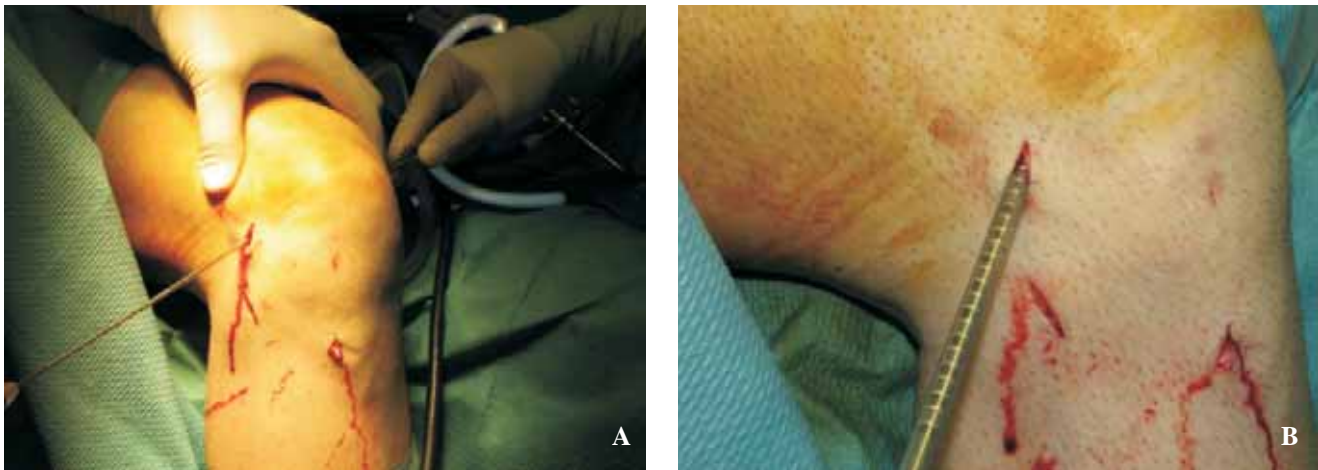


**Figure 2A.** Placement of the cruciate guide through the posterolateral portal. **B.** View of the Kirschner nail through the posterolateral portal.



**Figures 3A and B.** Tibial tunnel with drill bit (arthroscopic and lateral view).





**Figures 4A and B.** Femoral bone tunnel. Cross sectional 8 x 30 blind tunnel and long 5 mm tunnel.

more than 3 meters. He sustained direct trauma of the knee and the lateral aspect of the right pelvic limb. He went to his health care center, where he received primary care and was referred to the emergency room of ASEPEYO Hospital. During the initial physical exam performed there, dermabrasions were found in the lateral aspect of the right leg as well as tenderness of the right knee. A control X-ray was requested. No apparent bone injury was observed, so the following treatment was provided: compressive bandage, crutches, analgesics, antiinflammatories and local cold packs.

Two months later he was again referred to the outpatient service at our hospital, where he was found to have full mobility of the right knee with an anterior drawer in neutral rotation (-), posterior drawer (+/+++), lateral gap in full extension and at 30° of flexion (+++), lateral tibial hyperrotation, reverse pivot shift (+), and posterolateral drawer (+/+++).

Several visits were scheduled subsequently and complementary studies were ordered. The MRI led to the diagnosis of severe knee ligament injury with involvement of the ACL (partial tear), PCL, MCL, and posterolateral corner (*Figures 9A and 9B*). He was therefore scheduled for surgical treatment.

He was scheduled in September 2010 and the surgical technique described above was used.

During the arthroscopic surgical procedure the following was observed: laxity of the posterior cruciate ligament, varus opening of the lateral compartment, absence of the popliteal tendon, grade III patellar chondropathy, and grade II chondropathy of the left femoral condyle; the fact that the partial ACL tear was functional was proven. As this was a patient without considerable functional demand of the knee, we did not advocate PCL reconstruction; only in chronic cases with residual instability do we perform PCL ligamentoplasty.

### Postoperative treatment

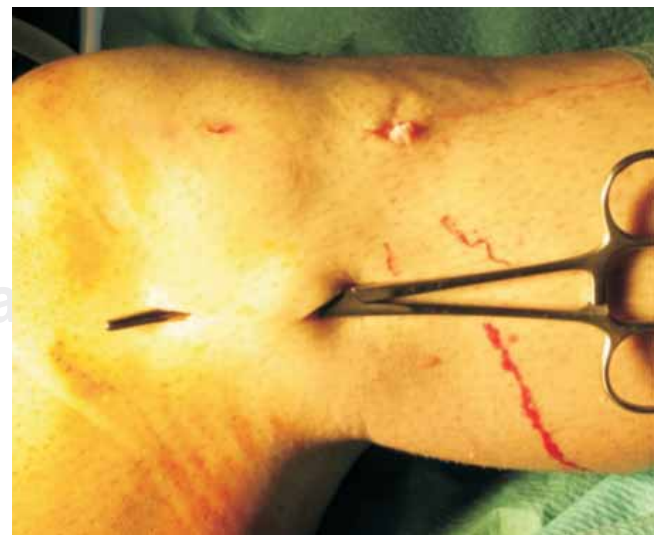During the first 3 weeks a knee guard was placed in full extension that allowed performing isometric exer-

cises, mobilizing the patella and the ankle, raising the leg in supine decubitus, and applying ice on the knee. The patient was allowed to walk without loading with canes.

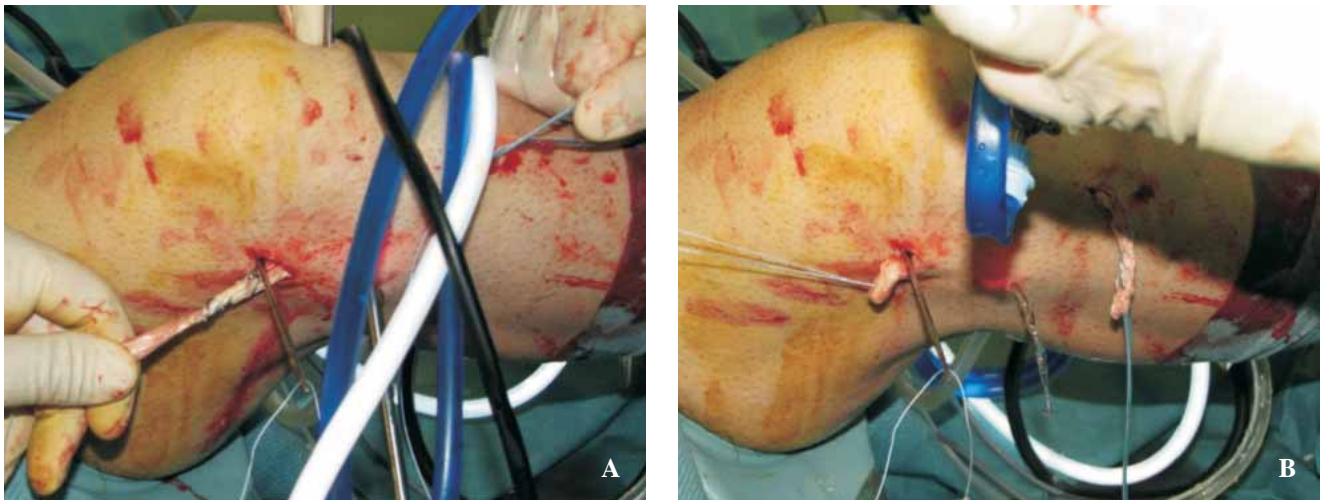
As of week 3, the lock that kept the knee guard in full extension was removed and the knee guard was placed at 0° of extension and 90° of flexion. Rehabilitation was started without forcing flexion beyond 90° and progressive weight bearing was started with crutches as soon as full passive extension was achieved.

Later, at week six, the patient continued to use the knee guard and the following exercises were indicated to achieve maximum active flexion not against gravity: stationary cycling and swimming.

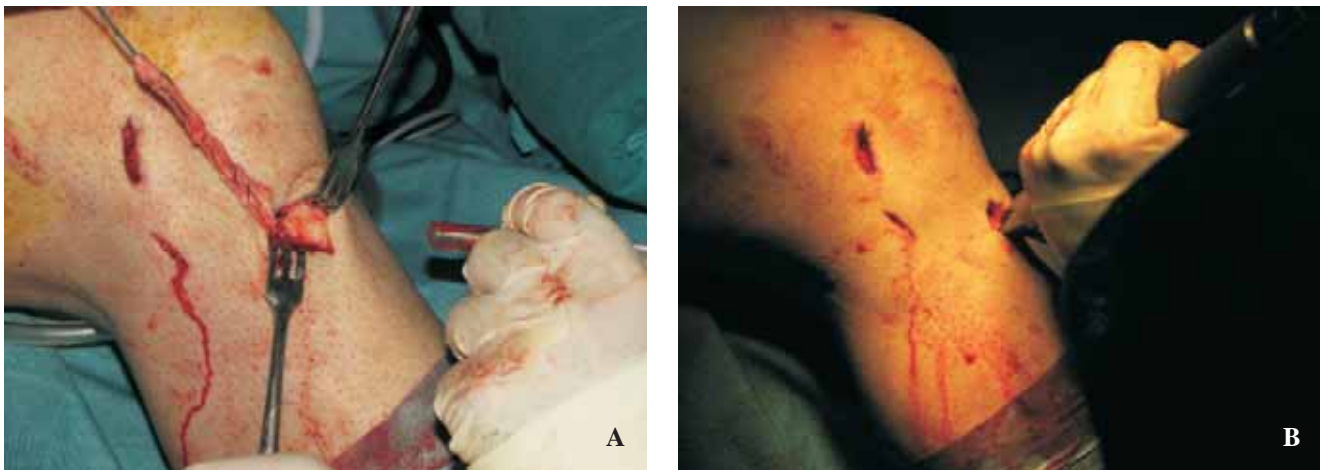
Lastly, as of week 8 the knee guard was removed and hamstring exercises were indicated against gravity and against a resistance.



**Figure 5.** Subcutaneous dissection from the epicondyle to the posterolateral portal.



**Figure 6A.** Passing of the plasty. **B.** Bone chip of the allograft in the femoral bone tunnel, fixed with an interference screw.



**Figures 7A and B.** Distal tibial fixation with a bone plug and two 6 mm Richards staples correcting the posterolateral drawer.

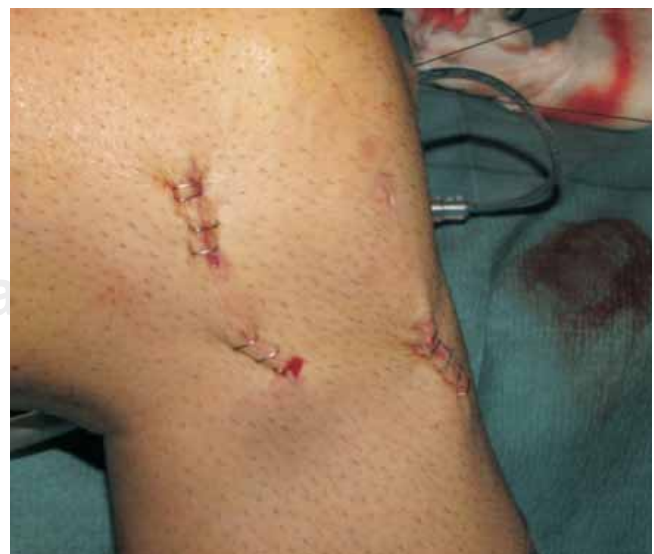## Results

At month 3, the patient could walk without crutches and had complete knee stability; all the preoperative exam signs had become negative. At month 4, he returned to his usual work activities without sequelae leading to a poor prognosis.

## Discussion

In recent years the treatment of posterolateral corner knee lesions has been of great interest, as there are various surgical techniques in the literature that attempt to correct varus instability and lateral tibial rotation.

Initially, repairing these lesions during the acute phase is most important, as this leads to a better short- and long-term prognosis. However, they may be missed since often times they occur with cruciate ligament injuries that get special attention.



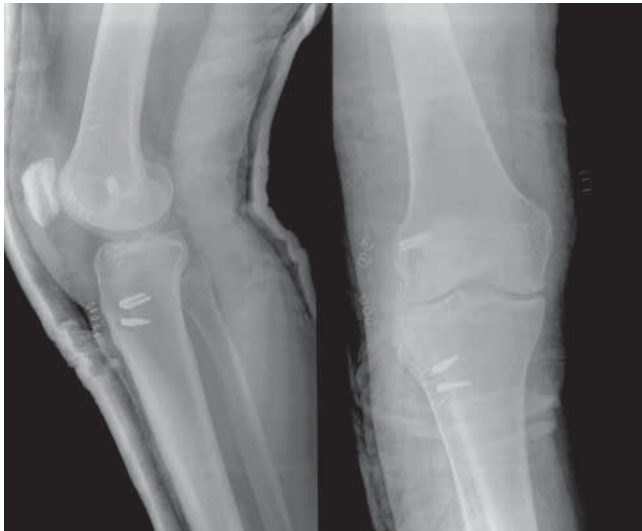
**Figure 7C.** Final view with wound closure.



Most of the techniques used currently to repair chronic lesions include aggressive treatments and therefore multiple complications such as infection or soft tissue necrosis.

After a long research and review of the literature we found only one bibliographic reference about repair of the posterolateral corner with an arthroscopic technique.

Considering all of these situations, we designed a new arthroscopic surgical technique that we consider as simpler and involving fewer steps for reconstruction of the lesion. Moreover, it has the advantage of being more anatomical, with less complications than open surgery and, in case that anterior or posterior cruciate ligament repair is required, it may be done at the same time. In fact, the novelty of performing a posterolateral portal facilitates visibility in the posterolateral area and, secondarily, it is used to pass the plasty from the femoral to the tibial tunnel more easily. Performing such portal is not a complication free task. Complications include peroneal nerve injury,<sup>22,23</sup> but the above mentioned advantages lead to recommending this portal.



**Figure 8.** Postoperative X-ray..

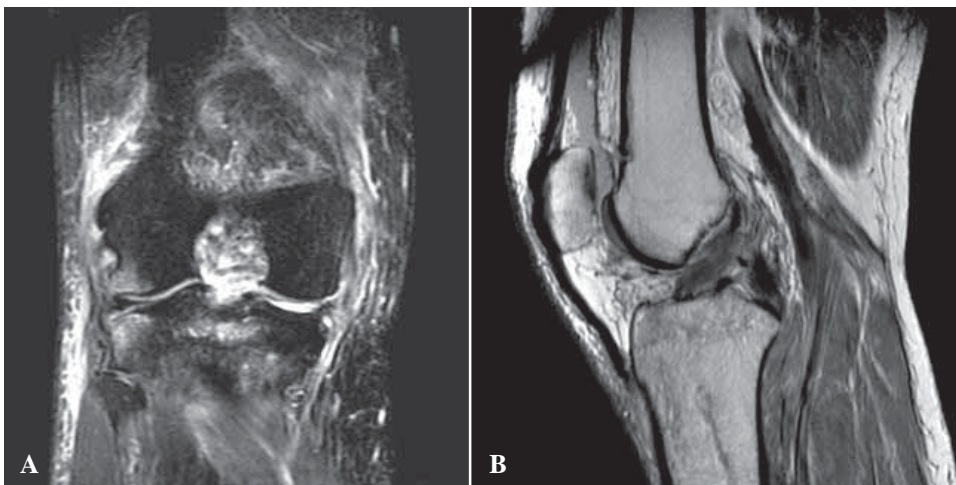
Moreover, compared with the only arthroscopic technique published, we may say that our technique, upon using an Achilles or quadriceps tendon allograft,<sup>4,11,14,24</sup> provides a stronger reconstruction technique. Fixation in the femoral epicondyle with a bone chip, in turn, reinforces both implant stability and restraint. Finally, the bone filler of the tibial tunnel provides a better biological solution to filling the tunnel.<sup>25,26,16</sup>

## Conclusions

The technique of arthroscopic posterolateral corner reconstruction is, in the hands of surgeons with experience in arthroscopy, a useful tool that avoids the major complications of conventional open surgery, provides a beneficial postoperative period due to the less surgical aggressiveness of the procedure, and leads to a good result from the perspective of function and stability.

## References

1. Feng H, Hong L: Posterolateral sling reconstruction of the popliteus tendon: an all-arthroscopic technique. *Arthroscopy* 2009; 25(7): 800-5.
2. Arciero RA: Anatomic posterolateral corner knee reconstruction. *Arthroscopy* 2005; 21(9): 1147.e1-e5.
3. Stannard JP, Brown SL: Reconstruction of the posterolateral corner of the knee. *Arthroscopy* 2005; 21(9): 1051-9.
4. Sekiya JK, Kurtz CA: Posterolateral corner reconstruction of the knee: Surgical technique utilizing a bifid achilles tendon allograft and a double femoral tunnel. *Arthroscopy* 2005; 21(11): 1400.e1-e5.
5. Ranawat A, Baker CL, Henry S: Posterolateral corner injury of the knee: Evaluation and management. *J Am Acad Orthop Surg* 2008; 16: 506-18.
6. Diamantopoulos AA, Tokis A: The posterolateral corner of the knee: evaluation under microsurgical dissection. *Arthroscopy* 2005; 21(7): 826-33.
7. Verma NN, Mithöfer K: The docking technique for posterolateral corner reconstruction. *Arthroscopy* 2005; 21(2): 238-42.
8. Adachi N, Ochi M: New hamstring fixation technique for medial collateral ligament or posterolateral corner reconstruction using the mosaic-plasty system. *Arthroscopy* 2006; 22(5): 571.e1-e3.
9. Clancy WG, Meister K, Craythorne CB: Reconstrucción ligamentosa posterolateral. En: Jackson DW: Rodilla. Ed. Marbán SL. Cirugía reconstructiva. Master en Cirugía Ortopédica 1999; 12: 143-57.



**Figures 9A and B.** Initial MRI, ligament knee injury with involvement of the ACL (broad partial tear), PCL, MCL and mild involvement of the LCL.

10. Ricchetti ET, Sennett BJ, Huffman GR: Acute and chronic management of posterolateral corner injuries of the knee. *Orthopedics* 2008; 31: 479-88.
11. Schechinger SJ, Levy BA: Achilles tendon allograft reconstruction of the fibular collateral ligament and posterolateral corner. *Arthroscopy* 2009; 25(3): 232-42.
12. McGuire DA, Wolchok JC: Posterolateral corner reconstruction. *Arthroscopy* 2007; 19(7): 790-3.
13. Jackson DW: Rodilla. Cirugía reconstructiva. Ed. Marbán, Madrid, España, 1999: 143-59.
14. Kocabey Y, Nawab A: Posterolateral corner reconstruction using a hamstring allograft and a bioabsorbable tenodesis screw: description of a new surgical technique. *Arthroscopy* 2004; 20(6): 159-63.
15. Radice FD, Gutiérrez VB, Haberle CT, Yáñez RD, González FF, Coda E: Inestabilidad posterolateral de rodilla: Evaluación clínica de tres técnicas quirúrgica. *Rev Lat Artr* 2005; 15: 52-8.
16. Ayala MJD: «Estudio de los túneles femoral y tibial en la ligamentoplastia del LCA mediante TAC y su repercusión clínica a largo plazo». Tesis Doctoral. Universidad de Alcalá de Henares. Tesis 2009.
17. Feeley BT, Muller MS. Comparison of posterolateral corner reconstructions using computer-assisted navigation. *Arthroscopy* 2010; 26(8): 1088-95.
18. Markolf KL, Graves BR, Sigward SM: Popliteus bypass and popliteofibular ligament reconstructions reduce posterior tibial translations and forces in a posterior cruciate ligament graft. *Arthroscopy* 2007; 23: 482-7.
19. Fanelli GC, Larson RV: Practical management of posterolateral instability of the knee. *Arthroscopy* 2002; 18: 1-8.
20. Berumen NE, Paz GM: Lesiones multiligamentarias de rodilla. *Orthotips* 2009; 5(1): 49-58.
21. Gollehon DL, Torzilli PA, Warren RF: The role of the posterolateral and cruciate ligaments in the stability of the human knee. A biomechanical study. *J Bone Joint Surg Am* 1987; 69: 233-42.
22. Johnson ME, Foster L: Neurologic and vascular injuries associated with knee ligament injuries. *Am J Sports Med* 2008; 36(12): 2448-62.
23. Pace JL, Wahl CJ: Arthroscopy of the posterior knee compartments: neurovascular anatomic relationships during arthroscopic transverse capsulotomy. *Arthroscopy* 2010; 26(5): 637-42.
24. Fanelli GC, Orcutt DR, Edson CJ: The multiple-ligament injured knee: evaluation, treatment, and results. *Arthroscopy* 2005; 21(4): 471-86.
25. Shaffer B, Gow W, Tibone JE: Graft-tunnel mismatch in endoscopic anterior cruciate ligament reconstruction: a new technique of intraarticular measurement and modified graft harvesting. *Arthroscopy* 1993; 9(6): 633-46.
26. Tomita F, Yasuda K, Mikami S, Sakai T, Yamazaki S, Tohyama H: Comparisons of intraosseous graft healing between the doubled flexor tendon graft and the bone-patellar tendon-bone graft in a anterior cruciate ligament reconstruction. *Arthroscopy* 2001; 17(5): 461-76.