

Clinical case

Continuous pain and swelling after humerus fracture in an 86-years-old woman

Herrera-Pérez M,^{*,**} Boluda-Mengod J,^{*} Muñoz-Ortus R,^{*} Gutiérrez-Morales MJ,^{*} Pais-Brito J^{*,**}

University Hospital of Canary Islands

ABSTRACT. Metastases to bone are the most frequent cause of destructive lesions to the skeleton in adults. The tumours that are most likely to metastasize to bone are prostate (32%), breast (22%), kidney (16%), lung and thyroid. The typical distribution of metastatic lesions are to the spine, ribs, pelvis, and proximal limb girdles. The humerus is the second most common site for long bone metastases, behind only the femur in its frequency of involvement. It represents the 20% of all bony metastases. We present a clinical case of an 86 yo woman with a previous diagnosis of myofibroblastic sarcoma of the maxillaris who suffers a pathological fracture of the humeral shaft secondary to metastasis and was misdiagnosed and treated for a typical humeral fracture using and intramedullary pinning (Hackethal technique), producing the progression of the disease within the humeral shaft. Due to the end state of the disease (multiple metastases), we decided to perform a palliative treatment with radiotherapy. This particular case report does confirm that is very important to rule out a malignancy in cases of osteolytic or poorly marginated lesions, particularly in patients older than 40 years of age. Therefore, it is imperative that the treating physician has a rational and effective approach to the diagnostic evaluation and treatment of these patients in order to avoid a malpractice.

Key words: Pain, metastatic, bone, humerus, fracture.

RESUMEN. Las metástasis del hueso son la causa más frecuente de lesiones destructivas del esqueleto en adultos. Los tumores que tienen más probabilidades de metastatizar a los huesos son próstata (32%), mama (22%), riñón (16%), pulmón y tiroides. La distribución típica de las lesiones metastásicas es a la columna vertebral, las costillas, la pelvis y las cinturas escapular y pélvica. El húmero es el segundo sitio más común para metástasis en huesos largos, sólo detrás del fémur en su frecuencia, representando el 20% de todas las metástasis óseas. Se presenta un caso clínico de una mujer de 86 años con diagnóstico previo de sarcoma miofibroblástico de mandíbula que sufre una fractura patológica de la diáfisis humeral secundaria a metástasis, se diagnosticó erróneamente y se trató como si fuera una fractura normal utilizando pinning intramedular (técnica de Hackethal), produciendo la progresión de la enfermedad dentro de la diáfisis humeral. Debido al estadio final de la enfermedad (metástasis múltiples), decidimos realizar un tratamiento paliativo con radioterapia. Este caso en particular confirma que es muy importante descartar una neoplasia maligna en casos de lesiones osteolíticas o mal delimitadas, particularmente en pacientes mayores de 40 años de edad. Por lo tanto, es imprescindible que el médico tratante tenga un enfoque racional y efectivo para la evaluación diagnóstica y el tratamiento de estos pacientes con el fin de evitar una mala práctica.

Palabras clave: Dolor, metastásico, hueso, húmero, fractura.

* Orthopaedic Department, University Hospital of Canary Islands, Tenerife, Canary Islands, Spain.

** Department of Surgery, School of Medicine, Universidad de La Laguna, Tenerife, Spain.

Mailing address:

E-mail: herrera42@gmail.com

Introduction

The clinical evaluation of a patient aged > 40 years who presents with a destructive bone lesion includes a detailed patient history, physical examination, imaging workup, biopsy strategy, and final staging. The differential diagnosis includes metastatic bone disease, multiple myeloma, lymphoma, primary malignant bone lesion, and non neoplastic conditions. Metastatic bone disease is the most common diagnosis of a destructive bone lesion in patients aged > 40 years.¹

Clinical case

An 86-year-old woman, referred by her family doctor to our centre, presented with a 3-month history of persistent swelling and pain in her left arm. She was treated for myofibroblastic sarcoma of the maxilla a year before (surgical excision and radiotherapy). Three months before the beginning of the symptoms, she suffered a diaphyseal humerus fracture after a minor trauma, which was surgically treated in another centre (*Figure 1*). She did not have symptoms of a recent fever, chills or night sweats, but her family reported weight loss of more than 10 kg in the last 3 months.

Upon physical examination, the left arm was swollen and painful when palpated. There was no overlying skin abnormality such as erythema, ecchymosis or warmth. Pulses were palpable and the sensation was normal. There was a surgical scar in the posterior distal aspect of the arm.

The laboratory results, including complete blood count, erythrocyte sedimentation rate (ESR), C-reactive protein (CRP), electrolytes and coagulation studies were completely normal.

X-ray at presentation showed a complete and angulated fracture of the humeral diaphysis within a poorly margined

lesion, which is a typical feature of a pathologic fracture (*Figure 1*). The second radiograph performed three months later, showed a complete destruction of almost all the left humeral diaphysis (*Figure 2*), with intramedullary pins inside the bone, and soft tissue enlargement.

Computed tomography (CT) scans of the chest, abdomen and pelvis were obtained showing two nodules in the left lung likely consistent with metastatic disease.

Scintigraphy showed increased uptake in the third and eighth left ribs and the whole left humerus, consistent with bone metastases. At this point, the main clinical entities included in the differential diagnosis are:

- Multiple myeloma
- Lymphoma
- Primary bone sarcoma
- Non-neoplastic conditions such as osteomyelitis or brown tumor from hyperparathyroidism.
- Metastatic bone disease

We decided to perform a core needle biopsy under X-ray control which was insufficient, so, we performed an open biopsy.

Histology interpretation

Macroscopically, the lesion was approximately 1.5 cm in diameter, grey-white, hard and fibrous. There was no necrosis. Microscopically, a bone involvement by spindle-shaped tumour with herringbone growth pattern was

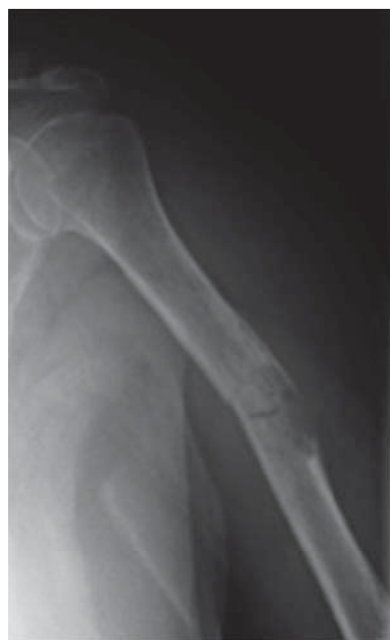

Figure 1.

AP radiograph of the humerus showing a pathological fracture of the shaft of the humerus.

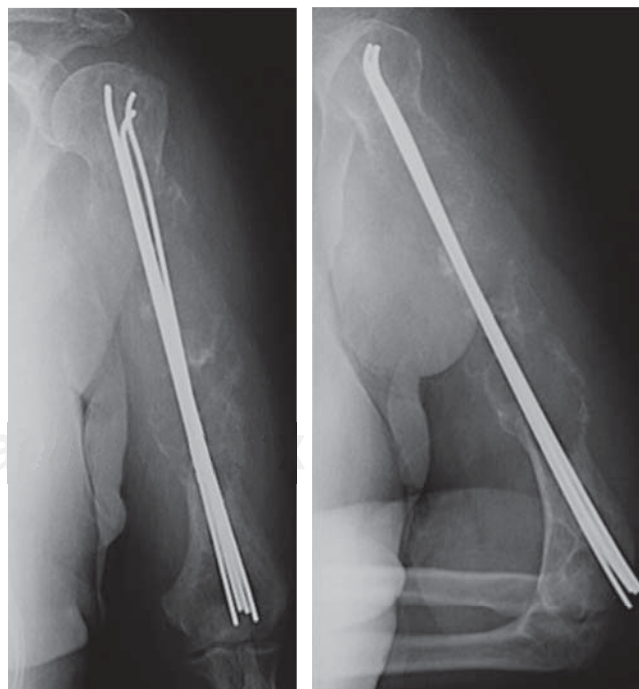


Figure 2. AP radiograph of the humerus which shows intramedullary pinning and gross bone destruction.

observed. Tumour cells have a pale or pink cytoplasm and fusiform nuclei with small nucleoli (H-E stain) (*Figure 3A*). Most tumour cells showed low-grade atypia. The mitotic index was low ($< 5/10$ HPF). Tumour cells stained positively for smooth-muscle actin (*Figure 3B*). The final diagnosis was metastatic low-grade myofibroblastic sarcoma of the maxilla.

Evolution

Our patient was misdiagnosed at the time of the humeral fracture, and was treated for a typical humeral fracture using and intramedullary pinning (Hackethal technique), producing the progression of the disease within the humeral shaft. Due to the end state of the disease (multiple metastases), we decided to perform a palliative treatment with local radiotherapy and we put an arm brace after removal of the hardware. At nine months follow-up the patient showed an improvement of symptoms, with less pain. The radiological exam showed a good response to radiotherapy, with ossification of most of the humerus,

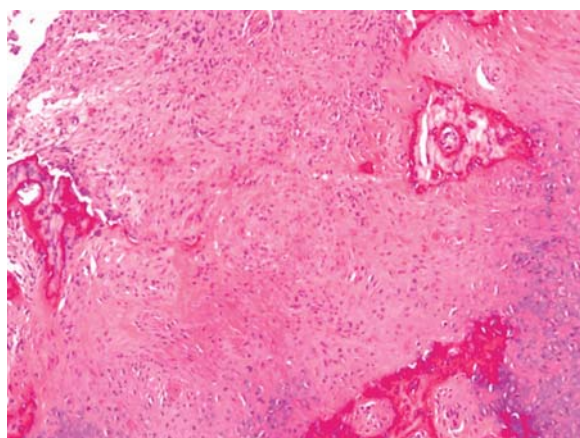


Figure 3A. Bone involvement by spindle-shaped tumor with herringbone growth pattern. Tumor cells have pale cytoplasm and fusiform nuclei with small nucleoli. H-E.

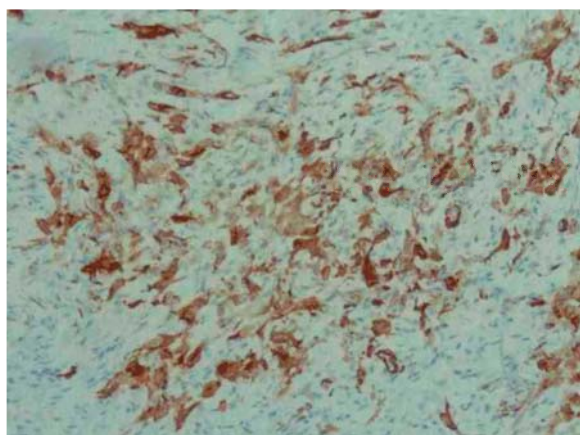


Figure 3B. Tumor cell stain positively for smooth-muscle actin.

although several fractures were observed as well as a shortening of the humerus (*Figure 4*).

Discussion

The initial presentation of a pathologic fracture may be misconstrued as a benign process,^{2,3,4} delaying a diagnosis of malignancy. After the initial radiographs, multiple imaging techniques such as CT and MRI, should be used for further evaluation.

Multiple myeloma (MM) is a systemic disease that affects the bone marrow. Occasionally, patients have solitary lesions without marrow involvement, called plasmacytomas. The bone lesions in myeloma are identified by skeletal survey and present as round, punched-out osteolytic areas in the extremities, pelvis, and spine. Laboratory studies including serum and urine electrophoresis with immunofixation confirm the diagnosis. Moreover, patients present with anaemia and elevated beta 2 microglobulin and lactate dehydrogenase levels.¹ However, our patient's lab results were strictly normal. A technetium Tc-99m total body scan is helpful in identifying additional bony sites of disease, but it may indicate a false negative result in the patient with multiple myeloma because this study detects only osteoblastic activity, so, although multiple myeloma is typically occult on bone scan, some lesions can have uptake.

Lymphoma in bone can manifest as (1) metastases from systemic lymphoma or as (2) primary lymphoma of bone which is more uncommon and by definition should not have systemic disease. The metastatic form is usually radiographically occult; however, the B cell subtype of primary lymphoma often has extensive bone destruction and a large soft tissue component

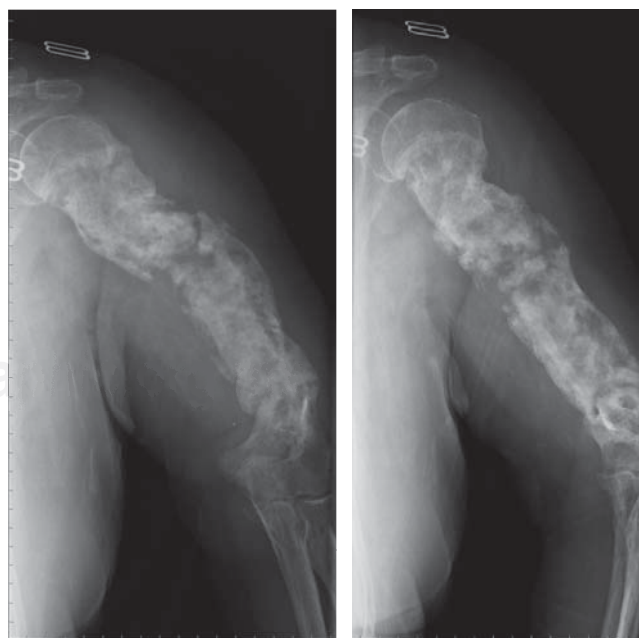


Figure 4. Reossification of the humerus after radiotherapy.

similar to the lesion in this case. In a typical scenario, the patient presents extensive lymphadenopathy and a soft tissue mass.^{1,5,6} In contrast, our patient had no lymphadenopathies and the bone lesion was unique.

Primary malignant bone tumours, such as chondrosarcoma, osteosarcoma and malignant fibrous histiocytoma can occur in the patient aged > 40 years. All these tumours have unique characteristics depending on the specific diagnosis.^{5,7}

Much further down the list are destructive benign bone lesions, that can also occur in adults but more often in younger patients than our case.

Non neoplastic conditions, including hyperparathyroidism, osteoporosis, osteomyelitis, metabolic bone disease, and Gorham vanishing bone disease, can cause osteolytic lesions or pathologic fractures. Determination of erythrocyte sedimentation rate and C-reactive protein level may be helpful when osteomyelitis is included in the differential diagnosis.¹

Metastases to bone are the most frequent cause of destructive lesions to the skeleton in adults.⁷ The tumours that are most likely to metastasize to bone are mainly carcinomas of prostate (32%), breast (22%), kidney (16%), lung and thyroid.⁶ The typical distributions of metastatic lesions are to the spine, ribs, pelvis, and proximal limb girdles.¹ The humerus is the second most common site for long bone metastases, behind only the femur in its frequency of involvement.^{5,7,8} It represents 20% of all bony metastases.

Metastatic bone sarcomas are very uncommon. Unlike carcinomas, bone sarcomas disseminate almost exclusively through the blood. Hematogenous spread of extremity sarcomas is manifested by pulmonary involvement in the early stages (up to 20% of the cases) and by bony involvement in later stages.⁹ Low-grade soft-tissue sarcomas have a low (< 15%) rate of subsequent metastasis while high-grade lesions have a significantly higher (> 15%) rate of metastasis. Metastases from sarcomas to regional lymph nodes are infrequent; the condition is observed in only 13% of patients with soft-tissue sarcomas and 7% of bone sarcomas at initial presentation. The prognosis associated with such an event is similar to that of distant metastasis.^{10,11}

Metastases to the long bones usually reflect an advanced disease state. It has been recommended that the majority of patients with metastatic bone tumours receive multidisciplinary care from a team including orthopaedic oncologists, radiotherapists, and oncologists.^{7,12,13}

Diagnosis of metastatic humeral bone lesions and alternatives for treatment vary depending on whether the patient has a large impending lesion or complete fracture, which region of the bone is affected, the extent of the overall disease, the histologic diagnosis, and the nature of prior treatment.⁷ Intramedullary stabilization is a reliable method for fixation of pathologic fractures of the humerus for patients in the advanced stage of metastatic disease.¹⁴ Postoperative external beam irradiation is necessary to prevent progressive bone destruction and subsequent loss of fixation.¹⁵

Tumours of the jawbone are among the most uncommon of all types of neoplasms and represent a distinct group of lesions from the conventional type commonly occurring in long bones. Nonetheless, our present knowledge of this tumour allows us to affirm that its clinical behaviour and pathologic features differ markedly from those of its homologous in the long bones.^{15,16,17} Low-grade myofibroblastic sarcoma represents a rare entity, which mostly develops in the soft tissues of the head and neck.¹⁵ Within the oral cavity lingual lesions are the most common and they tend to recur locally rather than to metastasise. When this tumour spreads to the bones it produces a well-demarcated osteolytic lesion with no periosteal reaction.¹⁶ Diagnostic methods include immunohistochemistry and molecular investigations. We would like to emphasize the uncommon location of this tumour type (within the maxilla) and its aggressive evolution (metastasis) though the low-grade histopathologic pattern; Guillou, et al tried to predict the likelihood metastasis of low-grade myofibroblastic sarcomas:¹³ a high malignancy grade (high mitotic index), a tumour size of > 10 cm and a deep location increase the tendency for metastasis.

The prognosis for patients with metastatic disease of a myofibroblastic sarcoma appears to be determined largely by the site(s), the number of metastasis, as well as the surgical resectability of the metastatic disease.^{2,8,13,14}

Conclusion

This particular clinical case does confirm that is very important to rule out a malignancy in cases of fractures after minor trauma or in cases of osteolytic or poorly marginated lesions, particularly in patients older than 40 years of age. Therefore, it is imperative that the treating physician has a rational and effective approach to the diagnostic evaluation and treatment of these patients in order to avoid a misdiagnosis.

Conflict of interest

The authors declare that there is no conflict of interests regarding the publication of this paper.

Acknowledgements

We thank Lily Korman for helping us translating this article.

Ethical approval: Written informed consent was obtained from the patient for publication of this case report and accompanying images. A copy of the written consent is available for review by the Editor-in-Chief of this journal on request.

Author contributions: All authors have made substantial contributions to the publication of this case report.

References

1. Weber KL: Evaluation of the adult patient (aged > 40 years) with a destructive bone lesion. *J Am Acad Surg.* 2010; 18(3): 169-79.
2. Bertuna G, Famà P, Lo Nigro L, Russo-Mancuso G, Di Cataldo A: Marked osteoporosis and spontaneous vertebral fractures in children: don't forget, it could be leukemia. *Med Pediatr Oncol.* 2003; 41(5): 450-1.
3. Fayad LM, Kawamoto S, Kamel IR, Bluemke DA, Eng J, Frassica FJ, et al: Distinction of long bone stress fractures from pathologic fractures on cross-sectional imaging: how successful are we? *AJR Am J Roentgenol.* 2005; 185(4): 915-24.
4. Pauleit D, Sommer T, Textor J, Flacke S, Hasan C, Steuer K, et al: MRI diagnosis in longitudinal stress fractures: differential diagnosis of Ewing sarcoma. *Rofo.* 1999; 170(1): 28-34.
5. Capanna R, Campanacci DA: The treatment of metastases in the appendicular skeleton. *J Bone Joint Surg Br.* 2001; 83(4): 471-81.
6. Harrington KD: Orthopaedic management of extremity and pelvic lesions. *Clin Orthop Relat Res.* 1995; (312): 136-47.
7. Frassica FJ, Frassica DA: Metastatic bone disease of the humerus. *J Am Acad Orthop Surg.* 2003; 11(4): 282-8.
8. Frassica FJ, Frassica DA: Evaluation and treatment of metastases to the humerus. *Clin Orthop Relat Res.* 2003; (415 Suppl): S212-8.
9. Hauben EI, Hogendoorn PCW: *Epidemiology of primary bone tumors and economical aspects of bone metastases.* In: Heymann D (ed.): Bone cancer. Progression and therapeutic approaches. London: Academic Press; 2009: 3-8.
10. Fletcher CDM, Unni KK, Mertens F: *WHO classification of tumours. Pathology and genetics of tumours of soft tissue and bone.* Lyon: IARC Press; 2002.
11. Hansen MF, Seton M, Merchant A: Osteosarcoma in Paget's disease of bone. *J Bone Miner Res.* 2006; 21 Suppl 2: P58-63.
12. Dijkstra S, Stapert J, Boxma H, Wiggers T: Treatment of pathological fractures of the humeral shaft due to bone metastases: a comparison of intramedullary locking nail and plate osteosynthesis with adjunctive bone cement. *Eur J Surg Oncol.* 1996; 22(6): 621-6.
13. Guillou L, Coindre JM, Bonichon F, Nguyen BB, Terrier P, Collin F, et al: Comparative study of the National Cancer Institute and French Federation of Cancer Centers Sarcoma Group grading systems in a population of 410 adult patients with soft tissue sarcoma. *J Clin Oncol.* 1997; 15(1): 350-62.
14. Sarahrudi K, Wolf H, Funovics P, Pajenda G, Hausmann JT, Vécsei V: Surgical treatment of pathological fractures of the shaft of the humerus. *J Trauma.* 2009; 66(3): 789-94.
15. Watanabe K, Ogura G, Tajino T, Hoshi N, Suzuki T: Myofibrosarcoma of the bone: a clinicopathologic study. *Am J Surg Pathol.* 2002; 26: 393-4.
16. Mentzel T, Dry S, Katenkamp D, Fletcher CD: Low-grade myofibroblastic sarcoma: analysis of 18 cases in the spectrum of myofibroblastic tumors. *Am J Surg Pathol.* 1998; 22(10): 1228-38.
17. Niedzielska I, Janic T, Mrowiec B: Low-grade myofibroblastic sarcoma of the mandible: a case report. *J Med Case Rep.* 2009; 3: 8458.