

Clinical case

Atypical femoral fracture, case report and literature review

Cleto-Zepeda G,* Durán-Martínez N,** Tena-Sanabria ME***

Hospital General Xoco

ABSTRACT. Introduction: Bisphosphonates have been the gold standard in the management of osteoporosis. Its antiresorptive effect has reduced the incidence of fractures due to bone fragility, as well as its impact on public health. We present the clinical case of a patient in prolonged treatment with bisphosphonates and atypical bilateral femur fracture. *Case report:* A 65-year-old female who presented a fall from her own height, on treatment with risedronate for seven years, and a history of systemic arterial hypertension and hypercholesterolemia, both with medical treatment. Diagnosed with bilateral atypical femoral fracture, treated with closed reduction internal fixation (CRIF) with intramedullary nailing, application of calcium citrate and teriparatide. *Discussion:* Multiple studies indicate that the benefit of using bisphosphonates for osteoporosis is higher than the risk of presenting atypical fractures.

Key words: Atypical fractures, osteoporosis, bisphosphonates, teriparatide, nail.

RESUMEN. Introducción: Los bifosfonatos han sido de gran utilidad en el manejo de la osteoporosis. Su efecto antirresortivo ha disminuido la incidencia de fracturas por fragilidad ósea, así como, su impacto en salud pública. Presentamos el caso clínico de una usuaria en tratamiento prolongado con bifosfonatos y fractura atípica de fémur bilateral. *Caso clínico:* Femenino de 65 años, presenta caída de su plano de sustentación, en tratamiento con risedronato desde hace siete años y antecedente de hipertensión arterial sistémica e hipercolesterolemia, ambas con manejo médico. Diagnosticada con fractura bilateral de fémur, tratada con enclavado centro-medular, citrato de calcio y teriparatida. *Discusión:* Múltiples estudios refieren que el beneficio del uso de bifosfonatos en la prevención del riesgo de fracturas es mayor, aunque exista la posibilidad de presentar fracturas atípicas.

Palabras clave: Fracturas atípicas, osteoporosis, bifosfonatos, teripartida, clavo.

Introduction

Osteoporosis is a progressive systemic skeletal disorder characterized by a decrease in bone mass and microarchitectural deterioration of bone tissue leading to bone fragility and increased susceptibility to hip, spine and wrist fractures.¹

Atypical fractures are characterized by presenting after a minimal contusion, or in the absence of trauma; with periosteal or endosteal localization, in the lateral cortex, complete or incomplete, with transverse tracing and minimal comminution.² Atypical femoral fractures are associated with the use of bisphosphonates, a rare adverse reaction associated to prolonged treatment with these drugs.³

* Orthopedics fourth-year Resident of the Hospital General Xoco.

** Orthopedics and Traumatology Department of the Centro Medico Dalinde.

*** Chief of the Orthopedics Department of the Pediatric Hospital, UMAE Centro Medico Nacional Siglo XXI, IMSS.

Corresponding author:

Gisela Cleto-Zepeda

Av. México Coyoacán, Col. General Anaya, CP 03340, Alcaldía Benito Juárez, Mexico City, Mexico.

E-mail: gcletoz@gmail.com

Este artículo puede ser consultado en versión completa en <http://www.medigraphic.com/actaortopedica>

Case report

A 65 years old female, that on March 13, 2016, mentioned having a fall from her own height. With a medical record of osteoporosis, seven years of diagnosis in treatment with risedronate 35 mg and calcitriol 0.25 µg; systemic arterial hypertension five years of diagnosis, treated with candesartan 8 mg and amlodipine 5 mg; hypercholesterolemia treated with simvastatin 20 mg.

Anteroposterior and lateral radiographic studies of the right femur show a continuity solution at femoral diaphysis

with oblique tract, dislodged, without comminution, and cortical thickening. It was treated with CRIF with an antegrade locked intramedullary nailing (*Figure 1*). She is discharged 48 hours postoperatively with adequate evolution. Upon discharge, she is treated with teriparatide 250 µg/day, calcium citrate 2 g/day, etoricoxib 90 mg/day and assisted walking with walker at eight weeks with partial weight bearing.

Two months later, she had a central densitometry, its reports: column L2-L4 BMD of 0.930 g/cm² T-score -2.3, Z-score -0.7; in total BMD of 0.959, T-score -0.4, Z-score 0.8; X-ray examination of the contralateral femur show proximal lateral periosteal thickening (*Figure 2*).

On June 15, 2016 she was on full weight bearing without assistance, hip and knee with complete range of motion without instability.

On September 28, 2016, she had radiographic control of the right femur, with parcial bone healing (*Figure 3*), on the left femur presented with decreased lateral thickening

(*Figure 4*), accordingly an atypical femoral fracture secondary to bisphosphonate intake was diagnosed.

Discussion

Bisphosphonates (BFs) are the initial therapy for osteoporosis, analogues of inorganic pyrophosphate, inhibits osteoclast activity and bone resorption.⁴ Two types of BFs: nitrogenated and non-nitrogenated. Non-nitrogenated: clodronate, etidronate and tiludronate. The nitrogenated: alendronate, ibandronate, risedronate, pamidronate and zoledronate.⁵

BFs have adverse bone effects: musculoskeletal pain, oversuppression of bone remodeling, atypical fractures, maxillary osteonecrosis; and extra-osseous: gastroesophageal, ophthalmic, renal, hypocalcemia and atrial fibrillation.³

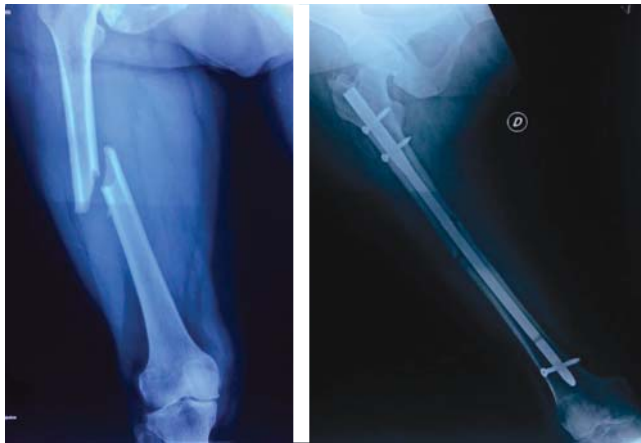


Figure 1: Initial radiograph (left side), continuity solution at femoral diaphysis is observed with oblique tract, dislodged, without comminution, and cortical thickening. One day after (right side) closed reduction internal fixation with antegrade locked intramedullary nailing.

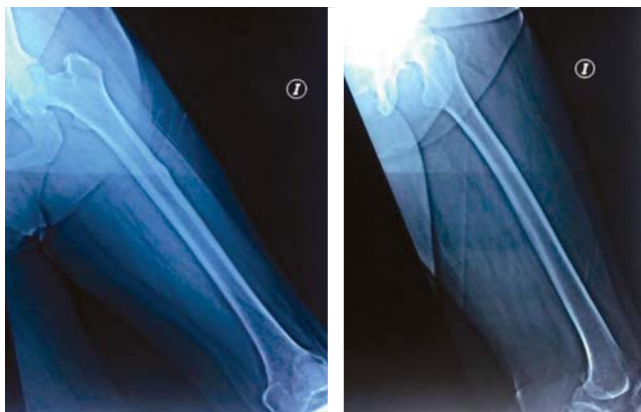

Figure 2: Anteroposterior and lateral radiograph of the left femur, showing incomplete atypical fracture with proximal lateral cortical thickening.

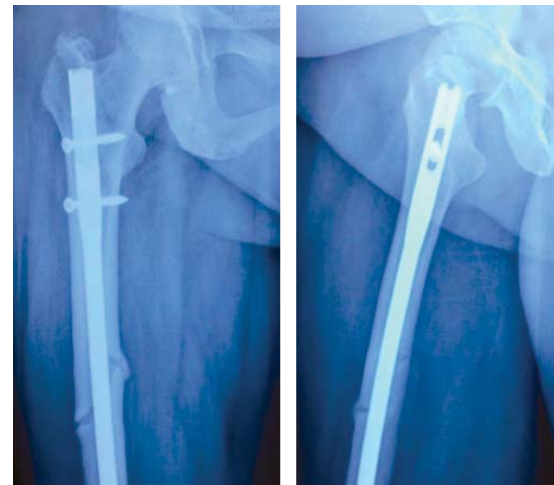


Figure 3: Anteroposterior and lateral radiograph of the right femur with partial bone healing.

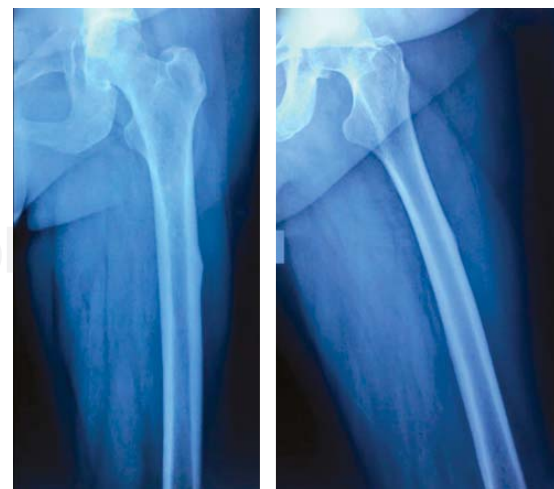

Figure 4: Anteroposterior and lateral radiograph of left femur, showing decrease of proximal lateral cortical thickening.

Atypical femoral fractures (AFFs): A stress fracture is due to an abnormal load in a normal bone, while one due to insufficiency is due to the normal load in an abnormal bone.² The American Society of Bones and Minerals (ASBMR) concluded that AFFs are fractures of effort or insufficiency that progress over time.² When a complete fracture occurs, the endochondral ossification is activated, the BFs interfere with the remodeling phase, delay the remodeling of callus from calcified cartilage to mature bone. With this suppression, intracortical repair of developing fatigue fractures decreases and microfractures can grow to a critical size.²

They are more common in the lower limbs because of the increased load and the geometry of the proximal femur, correlating with the deviation between the anatomical axis and the mechanical axis,² producing a lateral transverse rupture, characteristic of a brittle material.⁶

The pathophysiology of AFFs is unknown, a series of mechanisms are suspected: microcracks accumulation, increase and reduction of bone mineralization heterogeneity, reduction of vascularity and antiangiogenic effects, accumulation of advanced glycation, reticular alteration, generating alterations in bone remodeling.⁷

The first report was given in 2005 with Odvina et al.⁸ In 2013 the ASBMR published the definition of AFFs, four major features are required, that may or may not be accompanied by minor features:⁹

Major features: Fracture associated with minimal trauma; transverse orientation, can become oblique; complete or incomplete fractures that only affect the lateral cortex; the fractures are minimally with or without comminution; In fracture site with periosteal or lateral endosteal thickening.

Minor features: Increased cortical thickness of the femoral shaft; pain in the groin or thigh; fractures of incomplete or complete femoral shaft; delayed healing; localization along the femoral shaft.

The overall incidence could be estimated at 7.8/100,000 person-years for patients over 60 years of age. A recent study has shown that this incidence increases with the time of exposure to the drug, from 2/100,000 cases/year for every two years of use of bisphosphonates to 78 per 100,000 cases/year for every eight years of use of these drugs.¹⁰

The usual treatment in these fractures was immediate suppression of the antiresorptive and a correct initial reduction of the fracture.¹⁰ In the case of incomplete atypical subtrochanteric or femoral diaphyseal fracture with thigh pain, prophylactic intramedullary nailing is recommended. A prior conservative treatment period may be chosen, keeping the patient under limited load with the aid of a walking stick. If clinical and radiological improvement is

not achieved after two to three months with this treatment, prophylactic intramedullary nailing is recommended.¹⁰

The ASBMR suggests for those women who do not have a high risk of fractures after 3-5 years of treatment, to stop using BFs for a period of two to three years with periodic reevaluation.¹¹ Teriparatide (TPTD), a recombinant form of parathyroid hormone (PTH) and an anti-osteoporotic agent with potent bone formation effects, improves bone healing with a great positive effect in curing this type of fracture.¹² In our clinical case, the association between the prolonged use of bisphosphonates and atypical fracture of the femur is demonstrated once again, as well as its adequate evolution with medical management, intramedullary nailing, and rehabilitation.

References

1. Iqbal MM. Osteoporosis: epidemiology, diagnosis, and treatment. *South Med J*. 2000; 93(1): 2-18.
2. Im GI, Jeong SH. Pathogenesis, management and prevention of atypical femoral fractures. *J Bone Metab*. 2015; 22(1): 1-8.
3. Edwards BJ, Bunta AD, Lane J, Odvina C, Rao DS, Raisch DW, et al. Bisphosphonates and nonhealing femoral fractures: analysis of the FDA Adverse Event Reporting System (FAERS) and international safety efforts: a systematic review from the Research on Adverse Drug Events And Reports (RADAR) project. *J Bone Joint Surg Am*. 2013; 95(4): 297-307.
4. Bubbear JS. Atypical femur fractures in patients treated with bisphosphonates: identification, management, and prevention. *Rambam Maimonides Med J*. 2016; 7(4). doi: 10.5041/RMMJ.10259.
5. Geissler JR, Bajaj D, Fritton JC. American Society of Biomechanics Journal of Biomechanics Award 2013: cortical bone tissue mechanical quality and biological mechanisms possibly underlying atypical fractures. *J Biomech*. 2015; 48(6): 883-94.
6. Shane E, Burr D, Abrahamsen B, Adler RA, Brown TD, Cheung AM, et al. Atypical subtrochanteric and diaphyseal femoral fractures: second report of a task force of the American Society for Bone and Mineral Research. *J Bone Miner Res*. 2014; 29(1): 1-23.
7. Takemoto RC, McLaurin TM, Tejwani N, Egol KA. Evolution of atypical femur fractures and the association with bisphosphonates. *Bull Hosp Jt Dis (2013)*. 2014; 72(1): 104-9.
8. Odvina CV, Zerwekh JE, Rao DS, Maalouf N, Gottschalk FA, Pak CY. Severely suppressed bone turnover: a potential complication of alendronate therapy. *J Clin Endocrinol Metab*. 2005; 90(3): 1294-301.
9. Saita Y, Ishijima M, Kaneko K. Atypical femoral fractures and bisphosphonate use: current evidence and clinical implications. *Ther Adv Chronic Dis*. 2015; 6(4): 185-93.
10. Caeiro-Rey JR, Etxebarria-Foronda I, Mesa-Ramos M. Fracturas atípicas relacionadas con el uso prolongado de bifosfonatos. Estado de la situación. *Rev Esp Cir Ortop Traumatol*. 2011; 55(5): 392-404.
11. Adler RA, El-Hajj Fuleihan G, Bauer DC, Camacho PM, Clarke BL, Clines GA, et al. Managing osteoporosis in patients on long-term bisphosphonate treatment: report of a task force of the American Society for Bone and Mineral Research. *J Bone Miner Res*. 2016; 31(1): 16-35.
12. Im GI, Lee SH. Effect of teriparatide on healing of atypical femoral fractures: a systemic review. *J Bone Metab*. 2015; 22(4): 183-9.