

Case report

Incisional hernia, a rare complication of the anterolateral transpsoas approach

Hernia incisional, una complicación poco frecuente del abordaje transpsoas anterolateral

Reyes-Sánchez A,* Valenzuela-González J,† Valle-Valdez MA,§ García-Ramos C‡

National Institute of Rehabilitation «Luis Guillermo Ibarra Ibarra», Mexico.

ABSTRACT. Introduction: Anterolateral transpsoas approach is considered as safe access to the retroperitoneum with low risk of complications. The most frequent described complications due to this approach were nerve, bowel, urethral and kidney injury. An incisional hernia is a rare complication in anterolateral approach, as a result of a nonhealing surgical wound or late disruption of the fascia; it occurs in 1% of the incisions after primary closure. **Case description:** We report a 75-year-old woman who underwent spinal surgery with a double approach, consisting of an anterolateral transpsoas approach and posterior lumbar approach. Two months post-surgery, the patient developed a lateral abdominal tumor at the surgical site. **Conclusion:** To prevent incisional hernia, a meticulous dissection must be performed to avoid muscle denervation and weakening of the abdominal wall, as well as proper repair of the fascia its critical to ensure an adequate closure of the wound.

Keywords: Incisional hernia, postoperative hernia, lumbar vertebrae, spinal fusion.

RESUMEN. Introducción: El Abordaje anterolateral transpsoas se considera como un acceso seguro al retroperitoneo con bajo riesgo de complicaciones. Las complicaciones descritas más frecuentes debido a este abordaje fueron lesiones nerviosas, intestinales, uretrales y renales. Una hernia incisional es una complicación poco frecuente en el abordaje anterolateral, como resultado de una herida quirúrgica no cicatrizada o una ruptura tardía de la fascia; ocurre en 1% de las incisiones después del cierre primario. **Caso clínico:** Informamos de una mujer de 75 años que se sometió a una cirugía de columna vertebral con un doble abordaje quirúrgico, que consiste en un abordaje anterolateral transpsoas y un abordaje lumbar posterior. Dos meses después de la cirugía, el paciente desarrolló un tumor abdominal lateral en el sitio quirúrgico. **Conclusión:** Para prevenir la hernia incisional, se debe realizar una disección meticulosa para evitar la denervación muscular y el debilitamiento de la pared abdominal, así como la correcta reparación de la fascia es crítico para asegurar un cierre adecuado de la herida.

Palabras clave: Hernia Incisional, hernia postoperatoria, vértebras lumbares, fusión espinal.

* Head of Special Surgery Division.

† Spine Surgeon.

§ Medical investigation Intern.

National Institute of Rehabilitation «Luis Guillermo Ibarra Ibarra», Mexico.

Address corresponding:

Carla García-Ramos, M.D.

National Institute of Rehabilitation «Luis Guillermo Ibarra Ibarra», Mexico.

México-Xochimilco road, Num. 289, Coapa, Col. Arenal Tepepan, Alcaldía Tlalpan, CP. 14389, CDMX.

Phone: 55 5999 1000, (12206) and (12209)

<https://dx.doi.org/10.35366/95329>

doi: 10.35366/95329



Introduction

The lumbar interbody fusion represents an effective surgical intervention for patients with lumbar degenerative diseases, spondylolisthesis, disc herniation, pseudoarthrosis and spinal deformities.¹ This surgery can be made by different approaches, one is the anterolateral transpsoas approach (ALPA) initially described by Bertagnoli & Vazquez in 2003.² The ALPA allows access to the lumbar disc space and vertebral body without extensive muscle dissection. The surgeon accesses retroperitoneum through a lateral incision and bluntly dissects through the abdominal wall and psoas muscle to access the lumbar spine.³

Through this transpsoas approach, many of the severe complications associated with other approaches may be



avoided. Specifically, early investigations have suggested that rates of iatrogenic nerve root injury, epidural fibrosis, bowel injury, blood loss, postoperative pain, and iatrogenic spinal instability may potentially decrease when compared with other approaches.⁴

Although ALPA is a safe approach; a variety of complications have been described, such as injury to the nerves passing through psoas muscle (lateral cutaneous nerve, genitofemoral nerve, lumbosacral plexus), which can be transient or permanent, psoas or quadriceps palsy and bowel, urethral and kidney injuries have been reported in the literature.⁵

An incisional hernia is «Any abdominal wall gap with or without a bulge in the area of a postoperative scar perceptible or palpable by clinical examination or imaging».⁶ It is common after abdominal surgery and anterior spine surgeries including anterior lumbar interbody fusion (ALIF); however,

it is rare with ALPA, with only a few cases reported by the literature.⁵ Galan et al.³ reported the first case of incisional hernia following a minimal invasive transposas approach in a 74-year-old female. In other literature, the incisional hernia was described after procedures for aortic, urologic/kidney disease with an incidence of 1%.^{7,8}

In 2009, the European Hernia Society (EHS) defined flank hernia as primarily located 3 cm above and below the umbilicus, lateral to the rectus sheath, but with possible extension into the neighboring regions.⁹ The flank region was considered by the EHS to be a subclass of the lateral abdominal wall hernia class; the other subclasses of lateral hernia were denoted as lumbar, subcostal, and iliac.⁹

Publication with the keywords: «flank hernia» «OLIF» «XLIF» «incisional hernia» and «complications». «Oblique lateral interbody fusion» «xtreme lateral interbody fusion»,

Figure 1:

A) X-Ray AP projection, an image of degenerative scoliosis with right concavity and right hip prosthesis.

B) X-Ray lateral projection, revealing spondylolisthesis Meyerdin I L4-L5.

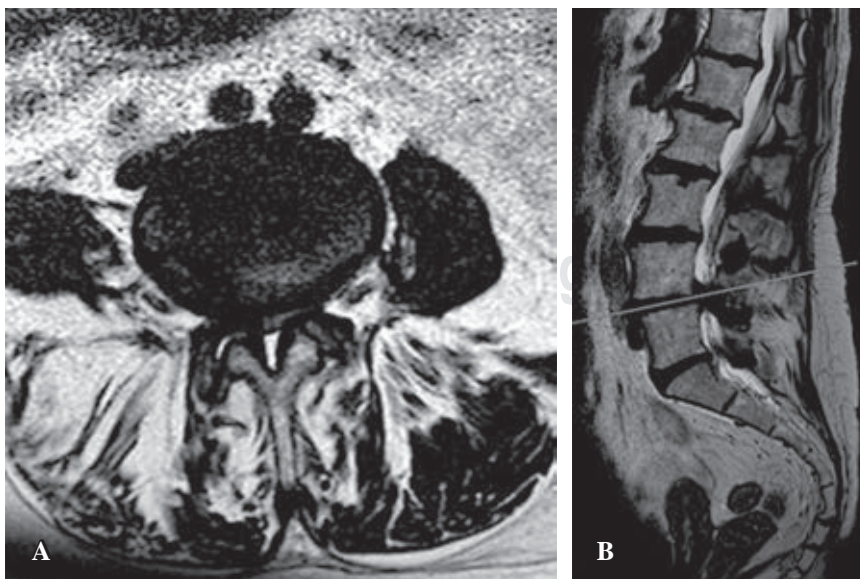
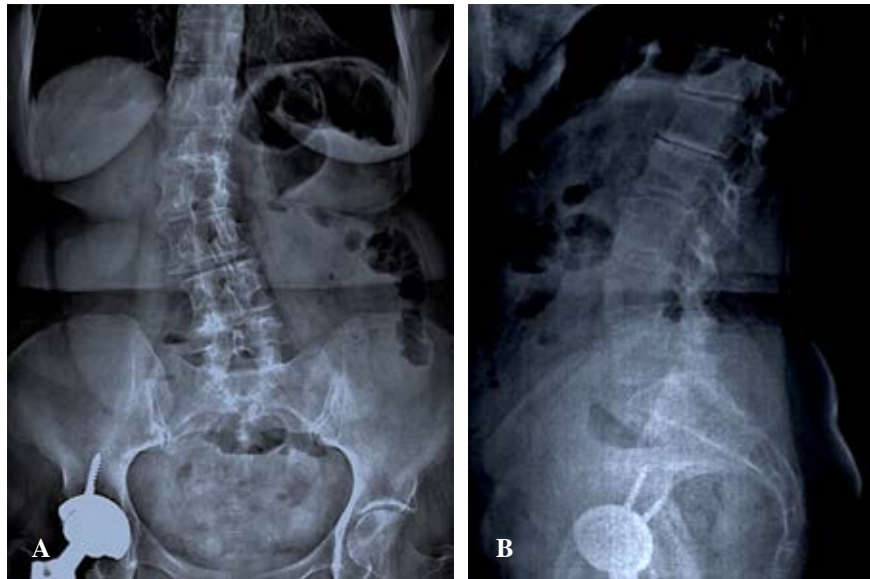
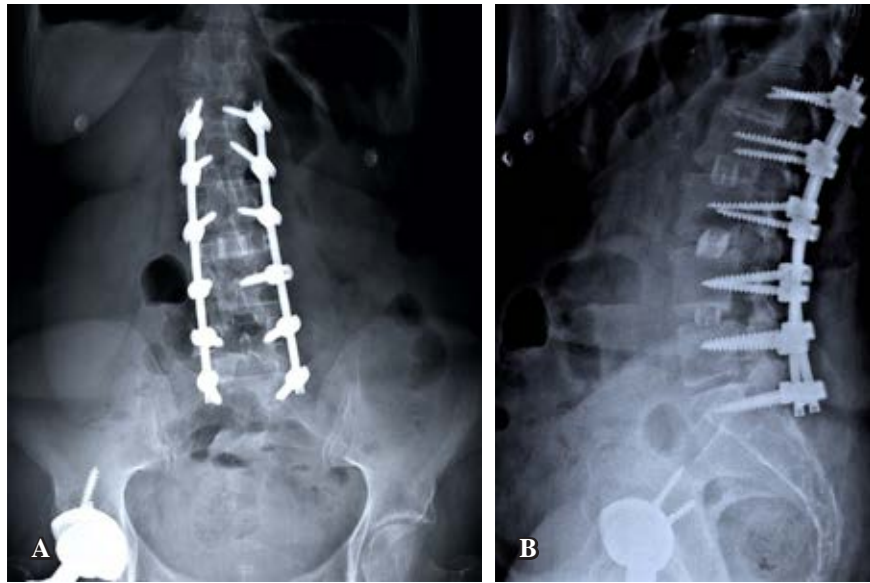


Figure 2:

A) Magnetic resonance imaging T2 sequence, axial projection; with facet hypertrophy and spinal cord compression due to intervertebral disc herniation. **B)** Magnetic resonance imaging T2 sequence, Sagittal projection; showing spondylolisthesis Meyerdin I L4-L5, with spinal cord involvement.

Figure 3:

A) X-Ray AP projection, post-surgery control image showing the material used to align the spine from L1 to S1. **B)** X-Ray lateral projection, post-surgery control image showing a better view of the screw's position and the intervertebral-body cages of L2-L3, L3-L4, L4-L5.



«transposas approach» «ALPA» were searched in PubMed, OVID, ScienceDirect, MEDLINE, from 2000 until 2018, a total of two articles were retrieved, most of the reports and series from retroperitoneum approaches were secondary to urologic/kidney and vascular diseases, which were not included.

Case report

A 75-year-old female with one year low-back-ache with insidious onset, left leg irradiation, neurogenic claudication within 25 meters and feeling of numbness and paresthesias since 2017, she referred multiple treatments including Non-steroidal anti-inflammatory drug (NSAID), spine rehabilitation, acupuncture, and other alternative therapies, without improvement of the symptomatology. As medical antecedents she reported hypothyroidism; surgical history of cholecystectomy in 1993 and right hip fracture treated with total hip replacement in 2017.

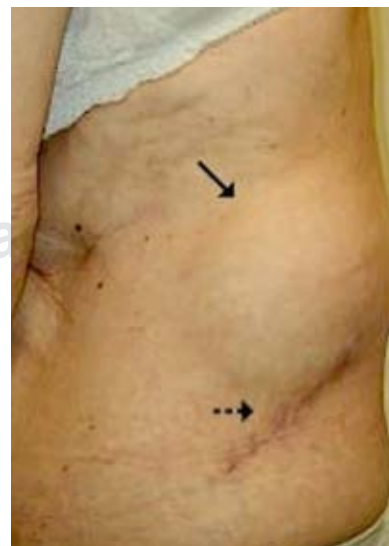Detailed systemic and neurological examination revealed coronal deformity presented with low back pain Numerical Analog Scale (NAS) 7/10.

Lumbo-sacral spine imaging studies revealed spondylolisthesis L4-L5 (Meyerding's grade I), degenerative scoliosis (Figure 1 A and B) (AEBI's grade I) with right concavity of 14° (Cobb's angle) and lumbar spinal stenosis from L2 to S1 (Figure 2 A and B).

Operative procedure. The patient underwent spine surgery with a double approach: ALPA, discectomy and lumbar cages placed on L2-L3, L3-L4, L4-L5 segments; and posterior approach with bilateral decompression and instrumentation with pedicular screws fixation from L1 to S1.

Surgical technique. Under general anesthesia, with neuromonitoring electrodes in place, the patient was positioned in right lateral decubitus protecting osseous prominences; using a C arm fluoroscopic device we identified the levels to intervene and marked the skin, antisepsia, and

surgical drapes were applied as protocol, the senior spine surgeon performed a lateral lumbar transposas approach. At first, 7 cm oblique incision was made over the skin, parallel to the fibers of the major oblique muscle. The major oblique, minor oblique, and the transverse muscles were anatomized following the muscles fibers direction, subsequently, retroperitoneal space was identified and dissected, the psoas muscle was exposed and cut through; the L2-L3, L3-L4 and L4-L5 segments were identified and dissected, the vertebrae platforms were prepared and the intervertebral space dilators were introduced, the interbody cages were filled with demineralized bone matrix and then placed. The adequate colocation was corroborated with image intensifier; layered suture was performed, first of all, the transversal fascia, external oblique fascia, fat tissue and dermis with 0 Vycril and outermost the skin was closed with nylon 3-0 and a film dressing was used to cover the wound (Figure 3 A and B).

**Figure 4:**

Clinical photo of the left side of the patient after surgery, evidencing the ALPA approach wound [→] and the affected area [-->].

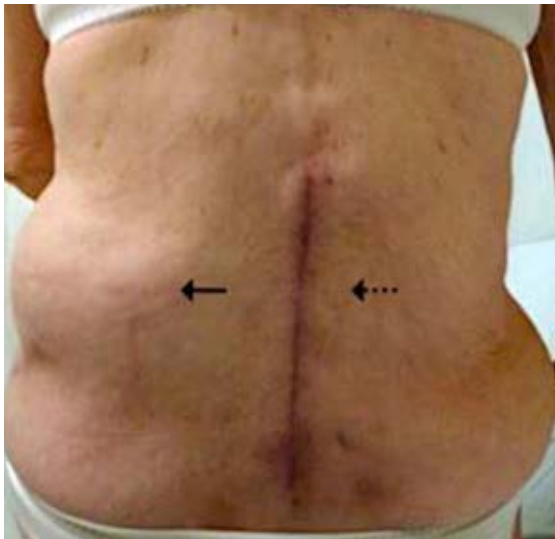

Figure 5: Clinical photo of the back of the patient after surgery, where we can observe the posterior approach wound [→], unclotting the affected area [---].

The patient presented with a painless left lateral abdominal swelling two months postoperative, clinical examination exposed an oval tumor of 8 by 13cm was found, it was movable and reducible (*Figures 4 and 5*). A computed tomography scan study revealed a lateral bulging of the abdominal wall and a delayed incisional hernia was diagnosed. She was sent to a general surgeon for evaluation and treatment (*Figure 6A and B*).

Discussion

The development of incisional hernia results from non-healing or late disruption of the fascial layers of the wound. It occurs in approximately 1% of incisions after primary closure, it is most frequently presented in abdominal, flank, and groin wounds.¹⁰

Two mechanisms are described for Lateral incisional hernias: an incisional hernia can occur through outpouching of denervated abdominal layers, these hernias are very difficult to repair due to incompetence of the entire muscular wall;¹¹ the second type is the focal herniation through a wall defect in the presence of normal abdominal muscular tone.³

The likely explanation for delayed hernia, has been described due to different etiologies, such as the muscular atrophy follow by iatrogenic denervation during the dissection of the abdominal wall muscles, even the incidental nerve section while closing the surgical wound or the use of electrocauterium.¹² The muscles lose their integrity following denervation and atrophy, and the abdominal wall allows the herniation. Hence blunt and careful dissection of muscular layers is recommended to prevent denervation and subsequent atrophy.¹³

Galan et al, described a 75-years-old female patient, who had the flank herniation onset four weeks after the surgery with palpation tenderness, also with multiple treatments due to her spinal disease, hypothyroidism, hypertension, arthritis and the antecedent of laparoscopic colectomy seven years prior differing from our patient who had laparoscopic surgery 26 years before the ALPA procedure and also with an intervention due to the right hip fracture; they recommend to place the surgical incision as posterior as possible in the thicker transversalis fascia and use of blunt dissection technique due to its importance to avoid denervation and resultant muscle atrophy.³

Dakwar et al. reported injury to motor nerves supplying the abdominal muscles caused by the direct surgical trauma during dissection of abdominal layers and retroperitoneum, producing paresis. They described 10 patients (of 568, incidence 1.8%) with abdominal paresis developed after minimally invasive lateral transpsoas spine surgery.¹¹

Additionally, direct repair of the fascia is crucial and perhaps a non-absorbable suture may provide a more durable closure.³

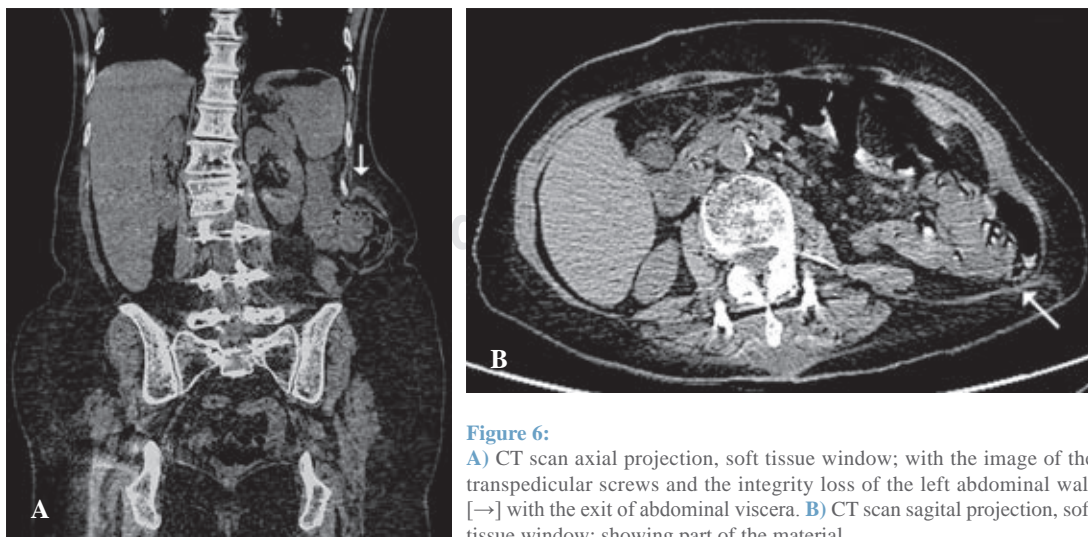


Figure 6: **A)** CT scan axial projection, soft tissue window; with the image of the transpedicular screws and the integrity loss of the left abdominal wall [→] with the exit of abdominal viscera. **B)** CT scan sagittal projection, soft tissue window; showing part of the material.

The reported case is a highly unusual complication of the transpsoas approach to the lumbar spine.

If surgeons are aware of this complication, the meticulous dissection surgery could prevent muscle denervation and weakening of the musculofascial layers, as well as the incision as posterior as possible in the thicker transversalis fascia. Adequate layered wound closure must be performed to avoid herniation.

Bibliography

1. Phan K, Maharaj M, Assem Y, Mobbs RJ. Review of early clinical results and complications associated with oblique lumbar interbody fusion (OLIF). *J Clin Neurosci*. 2016; 31: 23-9. <https://doi.org/10.1016/j.jocn.2016.02.030>.
2. Bertagnoli R, Vazquez RJ. The anterolateral transpsoatic approach (ALPA): a new technique for implanting prosthetic disc-nucleus devices. *J Spinal Disord Tech*. 2003; 16(4): 398-404. <https://doi.org/10.1097/00024720-200308000-00012>.
3. Galan TV, Mohan V, Klineberg EO, Gupta MC, Roberto RF, Ellwitz JP. Case report: Incisional hernia as a complication of extreme lateral interbody fusion. *Spine J*. 2012; 12(4): e1-e6. <https://doi.org/10.1016/j.spinee.2012.02.012>.
4. Hijji FY, Narain AS, Bohl DD, Ahn J, Long WW, DiBattista JV, Singh K. Lateral lumbar interbody fusion: a systematic review of complication rates. *Spine J*. 2017; 17(10): 1412-9. <https://doi.org/10.1016/j.spinee.2017.04.022>.
5. Gundanna M, Shah K. Delayed incisional hernia following minimally invasive trans-psoas lumbar spine surgery: report of a rare complication and management delayed incisional hernia following minimally invasive trans-psoas lumbar spine surgery : report of a rare complication and management. *Int J Spine Surg*. 2018; 12(2): 126-30. <https://doi.org/10.14444/5019>.
6. Korenkov M, Paul A, Sauerland S, Neugebauer E, Arndt M, Chevrel JP, et al. Classification and surgical treatment of incisional hernia. Results of an experts' meeting. *Langenbecks Arch Surg*. 2001; 386(1): 65-73.
7. Zieren J, Menenakos C, Taymoorian K, Müller JM. Flank hernia and bulging after open nephrectomy: Mesh repair by flank or median approach? Report of a novel technique. *Int Urol Nephrol*. 2007; 39(4): 989-93. <https://doi.org/10.1007/s11255-007-9186-x>.
8. Edwards C, Geiger T, Bartow K, Ramaswamy A, Fearing N, Thaler K, et al. Laparoscopic transperitoneal repair of flank hernias: A retrospective review of 27 patients. *Surg Endosc*. 2009; 23(12): 2692-6. <https://doi.org/10.1007/s00464-009-0477-4>.
9. Muysoms FE, Miserez M, Berrevoet F, Campanelli G, Champault GG, Chelala E, et al. Classification of primary and incisional abdominal wall hernias. *Hernia*. 2009; 13(4): 407-14. <https://doi.org/10.1007/s10029-009-0518-x>.
10. Zieren J, Menenakos C, Taymoorian K, Müller JM. Flank hernia and bulging after open nephrectomy: Mesh repair by flank or median approach? Report of a novel technique. *Int Urol Nephrol*. 2007; 39(4): 989-93. <https://doi.org/10.1007/s11255-007-9186-x>.
11. Focus N. Abdominal wall paresis as a complication of minimally invasive lateral transpsoas interbody fusion. *Neurosurg Focus*. 2011; 31(4): E18. <https://doi.org/10.3171/2011.7.FOCUS11164>.
12. Alonso F, Graham R, Rustagi T, Drazin D, Loukas M, Oskouian RJ, et al. The subcostal nerve during lateral approaches to the lumbar spine: an anatomical study with relevance for injury avoidance and postoperative complications such as abdominal wall hernia. *World Neurosurg*. 2017; 104: 669-73. Available from: <http://dx.doi.org/10.1016/j.wneu.2017.05.055>.
13. Yamada M, Maruta K, Shiojiri Y, Takeuchi S. Atrophy of the abdominal wall muscles after extraperitoneal approach to the aorta. *J Vasc Surg*. 2003; 38(2): P346-53. [https://doi.org/10.1016/S0741-5214\(03\)00119-8](https://doi.org/10.1016/S0741-5214(03)00119-8).

Conflict of interest: All the authors have no potential conflict of interest.