

## ***Post mortem* features of prevention and treatment of postburn scars by ozonotherapy method**

II Shevelev,<sup>\*,\*\*</sup> PI Koshelev,<sup>\*\*</sup> IV Yushin<sup>\*\*</sup>

### **INTRODUCTION**

The problem of prevention and treatment of keloid and hypertrophic scars is of current importance.

Intensity of scars may depend on numerous factors: depth of skin lesion, character of wound healing, method of treatment and prescription of injury, localization and disorder of regeneration.

The majority of researchers consider that mechanism of forming of pathologic scars is connected with disorder of correlation between synthesis and destruction of collagen. Others believe that disorder in relations between fibroblast and macrophage has the leading role in this process. According to the literature data the reason of their onset is chronic inflammation, hypoxia, immunologic shifts. Treatment of this pathology is accompanied by solving of number of problems which is proved by applied of numerous methods, techniques and means. The latest researches prove the possibilities of correction of trophic disorders in the zone of pathologic changes, normalization of ratio of metabolic processes and also antiinflammation and immunomodulatory effect of ozonotherapy. These researches let us suppose about the influence of ozone upon forming of healing tissue of skin.

### **MATERIAL AND METHODS**

We have researched and treated 179 patients with deep skin burns. It was aimed at the detection of histological characteristics of structure of pathological scars (hypertrophic

and keloid) and their changes during the treatment. The samples of normal skin were taken from the patients having been operated and without postburn scars (59 patients at the age from 18 to 56). The samples of healing tissue were taken by bioptic sampling and also by surgical excision of hypertrophic (128) and keloid (51) scars from the patients at the age from 18 to 60. The age of scars was varied from 2 to 18 months. Area of the scar was from 3% to 40% from the total area of the coverlet. Indications "hypertrophic" and "keloid" scar are given on the basis of clinical research according the commonly used criterion.

The age and sex of the patients are represented in the *table 1*.

Biopsy material was fixed in 10% neutral formalin, the material was embed in paraffin, then sections 7-10 mkm thick were prepared, which were stained by hematoxylin-eosin and picrofuchsin according Van-Gizon. Observation of biopsy material was conducted with microscope LEICA DMLS, being equipped with video camera JVC and connected up with personal computer.

All the patients were divided into 2 groups. The first control group had 88 patients, which were treated traditionally – by electrophoresis with lidase. The second basic group had 91 patients with pathologic scars and was treated with medical ozone.

The patients of both groups had prophylactic therapy in 1.5-3 months after the beginning of scar forming.

Then the patients were given 2 courses of ozone therapy. The first course is in 6-8 month after epithelization, the second is in 12-18 months after epithelization.

---

\* Candidate of Medical Science.

\*\* Burn Department Regional Clinical Hospital No. 1, Russia, Voronezh.

#### **Correspondence:**

Shevelev Igor Ivanovich

Russia. Voronezh. Moskovski Avenue 100-155. Tel. (4732) 75-63-31 Postal Code 394068

**Table I.**

Nature of injury	18-40		Age 49-59		60 and upwards		Sum total		
	m	f	m	f	m	f	abs.	%	
Postburn scars	39	40	21	23	2	3	128	71.6	
Postoperative scars	13	14	11	11	1	1	51	28.4	
Total	abs.	52	54	32	34	3	3	179	100
	%	29.0	30.1	17.8	18.9	1.6	2.23		

During the prophylactic treatment when the pathologic scar was not formed the concentration of ozone-oxygen mixture was 15 mg/L. The procedures were conducted every day. The course included 10 procedures.

Applying ozone in treatment we used its lower concentration (10 mg/L) and did it every other day. The ozone-oxygen mixture was injected into the scar depth with syringe with insulinic needle on the basis of 1 mL of gas mixture to about 1 cm of healing tissue.

During the morphological investigation of healing tissue there are the following histological changes.

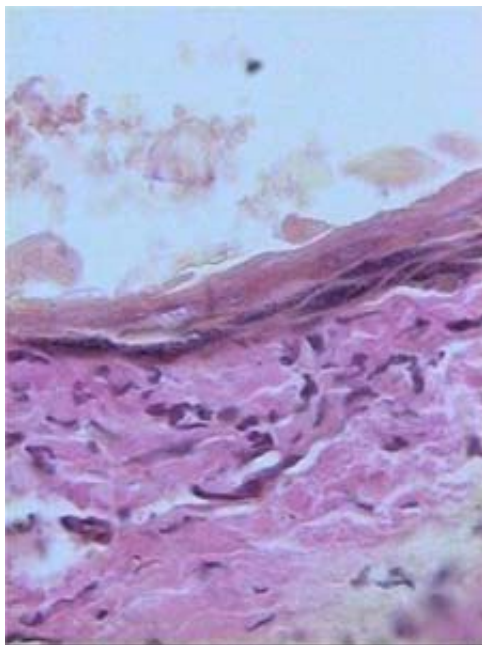
Epidermis has got thin, splitting has got broken, there was little melanin in the basal layer or it was absent, statum

papillare of derma was smoothed or it was absent here and there, appendages of skin (hair, sebaceous and sudoriferous glands) in the area of the scar was not discovered (Figure 1).

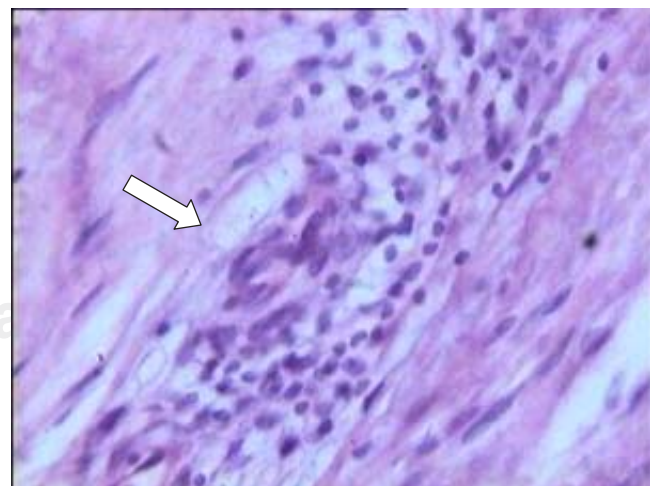
In subepidermal layer there was edema and nonspecific chronic inflammation (Figure 2).

In derma there were thickened, confusedly situated collagen fibers with focuses of dystrophic changes. The numerous vessels (up to 10 in the range of vision at 400) are distributed to the scar depth more or less evenly, there is a clear area of edema with inflammation reaction of different intensity around the vessels, capillary endothelium is succulent and turgid (Figure 3).

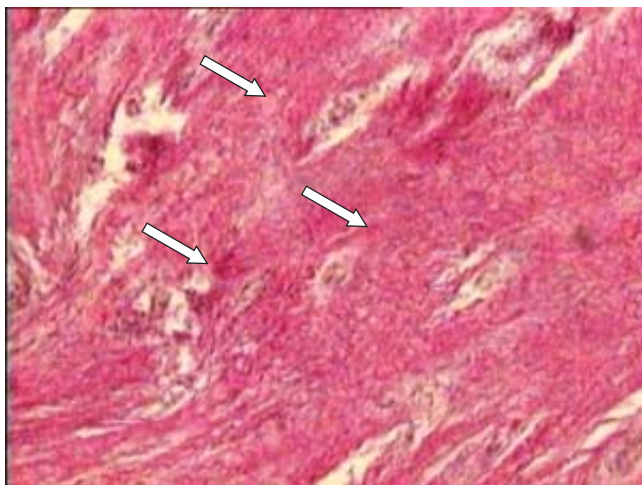
During studying biopsy materials of healing tissue, obtained after prevention treatment of the basic group, there were positive structure functional changes of the skin, epidermis has become thicker in the area of the scar, statum papillare has been restored greatly, there was clear divi-



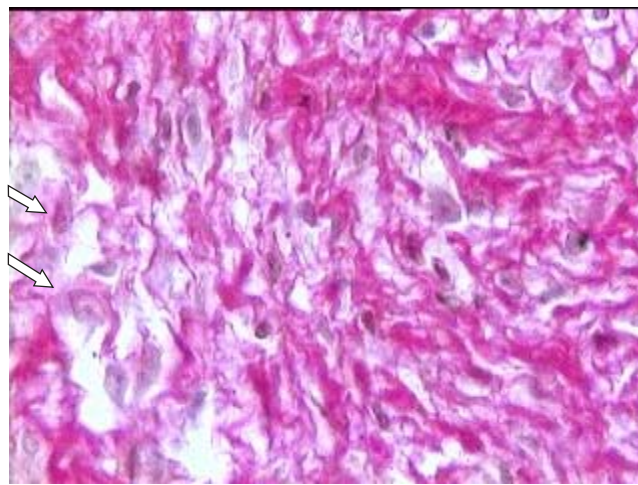
**Figure 1.** Pathological scar microslide of patient D (epidermis is thin with marked dystrophic changes, splitting is broken, melanin in the basal layer is not accumulated, statum papillare and appendages of skin are absent). Hematoxylin and eosin stain, ×400.



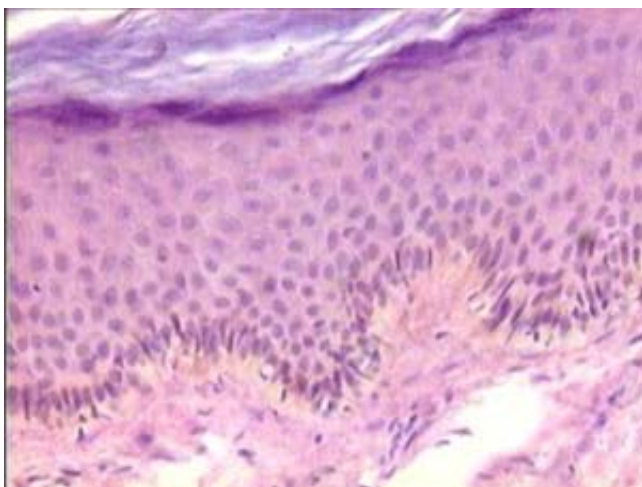
**Figure 2.** Subepidermal layer microslide of pathological scar of patient T. (inflammatory infiltration and edema around the capillary – pointed by the arrow). Hematoxylin and eosin stain, ×400.



**Figure 3.** Derma microslide of pathological scar of patient C. (chaotic location of thick fiber bundles stained in cardinal colour; among them there are vessels with clear edema around them –pointed by arrows). Picrofuchsin stain according Van-Gizon,  $\times 200$ .



**Figure 5.** Derma microslide of pathological scar of patient B (thinning and fragmentation of collagen fibers –pointed by the arrow, inflammation infiltration is absent). Picrofuchsin stain according Van-Gizon,  $\times 200$ .

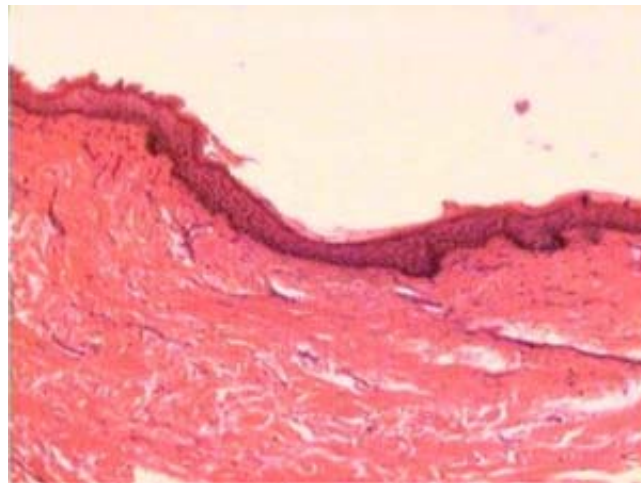


**Figure 4.** Microslide of pathological scar of patient T. (incomplete restoration of derma staturum papillare with melanin accumulation in melanophores of basal layer - pointed by the arrow). Hematoxylin and eosin stain,  $\times 400$ .

sion of epidermis into the layers with accumulation of melanin in the basal layer (Figure 4).

Edema of subepidermal layer has disappeared almost completely, there was clear resorption of thickened collagen fibers in derma (Figure 5).

In the control group with pathologic scars where traditional treatment took place after prophylactic treatment epidermis stayed thin, staturum papillare has restored incompletely, melanin began to accumulate slightly (Figure 6).



**Figure 6.** Derma microslide of pathological scar of patient T. (epidermis is thin, corneal layer is not desquamating, staturum papillare has restored slightly). Hematoxylin and eosin stain,  $\times 100$ .

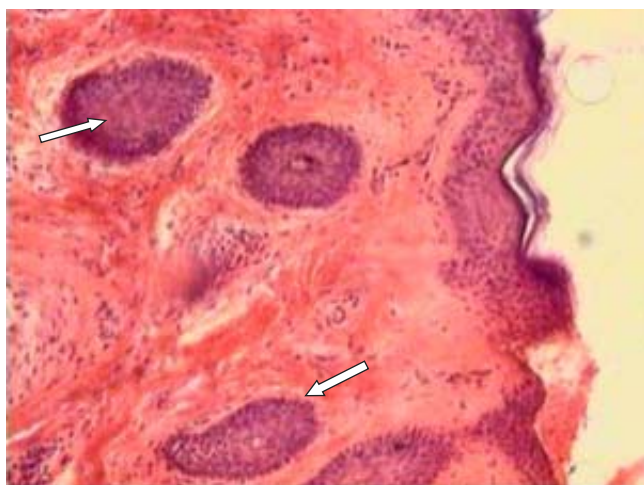After the first treatment course in the basic group the structure of skin has not restored completely, but has approximated to norma, there was derma splitting, melanin accumulation in cells of basal layer approximated to norma, staturum papillare has almost restored, appendages of skin (sebaceous and sudoriferous glands, hair follicles) have restored incompletely, location of collagen fibers in derma has regulated greatly, but they were not corresponding to standard structure (Figure 7).

Capillaries in derma became narrow, as if with diminished lumen and thin endothelial wall. Friable perivascular zone with

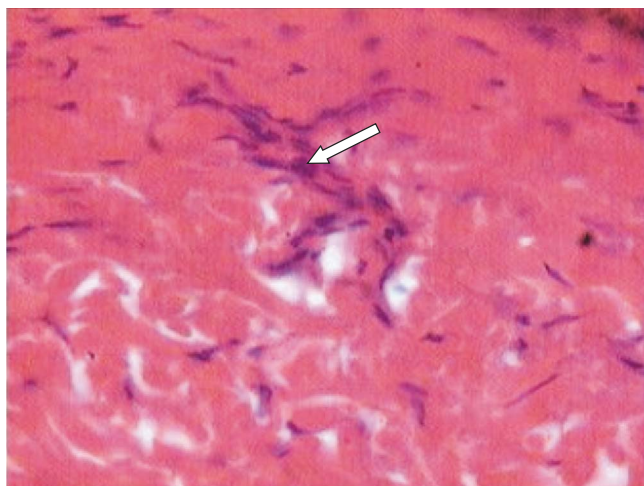
mononuclear infiltration in such vessels was absent (Figure 8).

The patients of the control group had no considerable changes. Edema remained, there was perivascular inflammation nidus.

Repeated biopsy after the second treatment course were conducted to the basic group of patients with pathological scars which were treated with medical ozone. Morphologic changes were less expressed than after the first course: there was more clear splitting of epidermis, statum papillare was near normal, but relatively chaotic location of collagen fibers in derma remained (Figure 9).

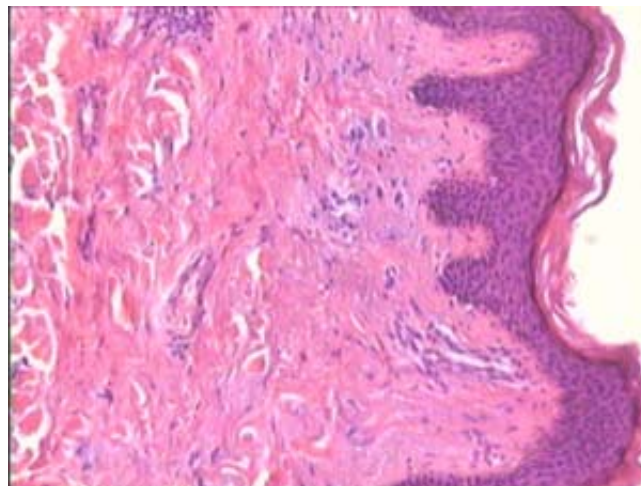


**Figure 7.** Derma microslide of pathological scar of patient T. (appearance of hair follicles in the scar area – pointed by the arrow). Hematoxylin and eosin stain,  $\times 100$ .

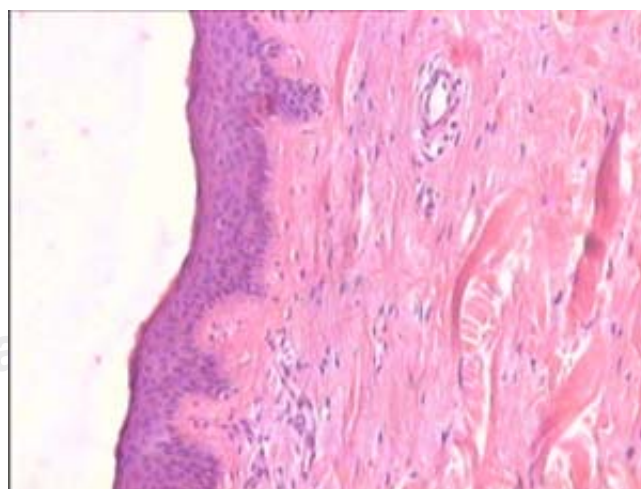


**Figure 8.** Derma microslide of pathological scar of patient B. (diminished capillary without perivascular infiltration and edema is pointed by the arrow). Hematoxylin and eosin stain,  $\times 100$ .

Patients of control group had slight morphologic changes: epidermis remained thin, statum papillare was partly restored. Collagen fibers remained thickened, chaotic located, without clear fragmentation and thinning. Edema and nidus of nonspecific inflammation remained here and there, number of vessels was invariable. In some cases keloid area began to spread outside affection zone, which was clinically accompanied by increase of keloid scar (Figure 10).



**Figure 9.** Derma microslide of pathological scar of patient E. (epidermis with layer division, clear statum papillare with slight subepidermal edema, chaotic location of collagen fibers in derma). Hematoxylin and eosin stain,  $\times 100$ .



**Figure 10.** Derma microslide of pathological scar of patient T. (epidermis is thin, corneal layer is faintly expressed, statum papillare has restored slightly, there was edema and nonspecific inflammation). Hematoxylin and eosin stain,  $\times 100$ .

## CONCLUSION

Conducted morphologic investigation made it clear that treatment with ozonotherapy at first 6-8 months after the injury led to resorption of healing tissue, took away edema and nonspecific inflammation, improved microcirculation and greatly decreased the probability of keloid scars forming in comparison with the patients of control group. Ozo-

notherapy was less effective in later period, resorption of healing tissue passed slowly, though edema and nonspecific inflammation partly stopped, and epidermis structure was near to normal.

On the basis of conducted morphologic data one can make a conclusion about the preference of prevention and treatment of pathological scars in early period to 6-8 months from the time of their formation.

## BIBLIOGRAPHY

1. Alyohina SP. The effectiveness of ozonotherapy in arteriosclerosis obliterans of lower extremities arteries. Abstract of Ph.D. thesis, candidate of medical science. SP Alyo hina – N Novgorod 1999: 26.
2. Bolgov VF. Ozone therapy in arteriosclerosis obliterans of lower extremities arteries. VF Bologov, IA Gribkova, OV Maslennikov. Thesis papers of IV All-Russian scientific-practical conference "Ozone and methods of efferential therapy in medicine". - N Novgorod, 2000: 87-88.
3. Bolshakova VF. Complex treatment of keloid scars. VF Bolshakova, SP Pahomov, OD Kinyapina. Interinstitute conference of inventors and rationalizers in medicine. Gorki, 1974: 14-15.
4. Bolhovitnikova LA. Keloid scars. LA Bolhovitnikova, MN Pavlova. – M., 1977.
5. Belyanin II. Biological and medical properties of ozone: Authorized analytical review. I/I/ Belyanin. – M.: TOO "Firm Block", 1998: 16.
6. Gorbunov SN. Modern treatment of foot trophic ulcer using complex ozonotherapy. SN Gorbunov, VP Dmitriev, AG Vinyarski, VI Baranovski, AN Bychkov. Thesis papers of IV All-Russian scientific-practical conference "Ozone and methods of efferential therapy in medicine". N Novgorod, 2000: 99-100.
7. Kontorshchikova KN. Lipid peroxidation in hypoxia and its correction with ozone. KN Kontorshchikova. Thesis papers and reports of international conference "Free radical processes: ecological, pharmacological and clinical aspects". – St. Petersburg, 1999: 772.
8. Mishakova TV. Potential of compression therapy in complex rehabilitation of postburn pathological scars of children thermal injury. TV Mishakova, VI Ostapenko, VI Chadov, LI Budkevich, YA Savelieva. Thesis papers "Combustiology in the border of centuries". M, 2000: 180-181.
9. Ozerskaya OS. Keloid scars. OS Ozerskaya. Cosmetology and medicine. -2000; 5-6: 99-103.
10. Ozerskaya OS. Modern methods of keloid scars treatment. OS Ozerskaya. In col. "All-Russian congress of dermatologist". - M., 2001; 1: 249-250.
11. Ozerskaya OS. Modern ideas of processes running in skin surface and ways of their correction. OS Ozerskaya. Magazine on dermatology and cosmetology 2001; 2: 31-35.
12. Ozerskaya OS. Modern approach to complex treatment of keloid scars of different kinds. OS Ozerskaya. Cosmetology and Medicine 2001; 3: 81-84.
13. Peretyagin SP. Experience of complex applying ozone- and aeroionotherapy of burn injuries. SP Peretyagin, VA Zhegalov, AA Struchkov, AG Polikarpova, II Ivanova. Thesis papers "Combustiology in the border of centuries". M., 2000: 126-127.
14. Fistal EY. To the problem of classification of burn injuries to their affection depth. EY Fistal. International Congress: "Combustiology in the border of centuries". – M., 2000: 63.
15. Shafranov VV. Keloid and hypertrophic scars: clinical-morphological parallel. VV Shafranov, NG Korotki, AV Taganov, EI Borhunova. Child Surgery 1998; 4: 30-34.