



# Synaptophysin is frequently expressed in megakaryocytes: a novel immunohistochemical finding of unknown significance

Roberto Ruiz-Cordero,\* Jennifer Chapman,† Francisco Vega§

## Key words:

Synaptophysin,  
megakaryocytes,  
bone marrow,  
immunohistochemistry.

## Palabras clave:

Sinaptofisina,  
megacariocitos,  
médula ósea,  
inmunohistoquímica.

\* Residente de cuarto año de Anatomía Patológica y Patología Clínica.

† Adscrita del servicio de Hematopatología y Jefa del Laboratorio de Inmunohistoquímica. Departamento de Patología de la Universidad de Miami/ Sylvester Cancer Center y del Hospital Jackson Memorial, Miami, Estados Unidos de América.

§ Jefe de la División de Hematopatología. Departamento de Patología de la Universidad de Miami/ Sylvester Cancer Center y del Hospital Jackson Memorial, Miami, Estados Unidos de América.

Correspondence:  
Roberto  
Ruiz-Cordero M.D.  
Department of  
Pathology and  
Laboratory Medicine  
University of Miami/  
Sylvester  
Comprehensive  
Cancer Center  
Building UMH,  
Pathology  
Department,

## ABSTRACT

**Introduction:** Synaptophysin is an integral membrane glycoprotein predominantly present in small synaptic vesicles in the brain. Its expression in human megakaryocytes has not been previously described. **Objective:** To determine the expression of synaptophysin in human megakaryocytes by means of immunohistochemistry. **Material and methods:** Bone marrow biopsies performed for evaluation of relapse, diagnostic or staging purposes in patients with hematologic diseases (neoplastic or non-neoplastic) were stained by immunohistochemistry with a monoclonal mouse anti-human antibody for synaptophysin and a polyclonal rabbit anti-human antibody for factor VIII (FVIII). Biopsies whose final interpretation was negative for tumor/disease were used as controls. **Results:** A total of 20 bone marrow biopsies (15 cases/5 controls) belonging to 20 patients with a median age was 52 years (2 to 83) were studied. Eleven of the 15 cases had diagnoses of hematologic malignancy and four of idiopathic/immune thrombocytopenic purpura (ITP). Cytoplasmic expression of FVIII was observed in all megakaryocytes. Synaptophysin expression was present in all controls and in 13 of 15 (90%) cases. In two of the four (50%) ITP, the megakaryocytes did not stain for synaptophysin but stained for FVIII. **Conclusions:** Synaptophysin expression was frequently detected by immunohistochemistry in megakaryocytes. However, it was not expressed in a subset of patients with ITP. Further studies are necessary to determine the clinical significance of these findings.

## RESUMEN

**Introducción:** La sinaptofisina es una glucoproteína integral de membrana localizada predominantemente en vesículas sinápticas del cerebro. Su expresión en megacariocitos humanos no ha sido previamente descrita. **Objetivo:** Determinar la expresión de sinaptofisina en megacariocitos humanos mediante inmunohistoquímica con técnica de inmunoperoxidasa. **Material y métodos:** Se tiñeron biopsias de médula ósea realizadas en pacientes con sospecha o diagnóstico de enfermedades hematológicas (neoplásicas o no neoplásicas) utilizando un anticuerpo monoclonal de ratón antisinaptofisina de humano y un anticuerpo policlonal de conejo anti-factor VIII (FVIII) humano. Se utilizaron como controles biopsias cuya interpretación final fue negativa para tumor o enfermedad. **Resultados:** Veinte biopsias de médula ósea (15 casos y cinco controles) de 20 pacientes fueron estudiadas. La mediana de edad fue 52 años (2 a 83). Once de los quince casos tuvieron diagnóstico de enfermedad hematológica neoplásica y cuatro de púrpura trombocitopénica inmune/idiopática (PTI). El FVIII fue positivo en los megacariocitos de todas las biopsias, mientras que la expresión de sinaptofisina estuvo presente en megacariocitos de los cinco controles (100%) y en 13 de los 15 (90%) casos. En dos (50%) de los cuatro casos de PTI no se observó expresión de sinaptofisina en los megacariocitos. **Conclusiones:** Los megacariocitos humanos expresan frecuentemente sinaptofisina en su citoplasma. Un subgrupo de pacientes con PTI no demostraron expresión de esta proteína. La significancia clínica de estos hallazgos es desconocida y amerita investigaciones adicionales.

## INTRODUCTION

Synaptophysin (Sy) is an integral membrane glycoprotein composed of 313 amino acids that is predominantly located in the synaptic vesicles,<sup>1,2</sup> where it plays an important role in neuron interaction by favoring neurotransmitter release.<sup>3,4</sup> Additionally, Sy expression has

also been described in synaptogenesis,<sup>5</sup> in the neurosecretory vesicles of neuroendocrine cells and their malignant counterparts,<sup>6</sup> and in rabbit platelets, where Sy might be involved in the creation of protein channels for serotonin release.<sup>7</sup> Moreover, several reports have demonstrated that molecular mechanisms that take place in the platelet exocytosis machinery

Suite 4061  
1400 NW 12th Ave,  
Miami, FL 33136  
Phone:  
(+1) 305-243-5760  
Fax:  
(+1) 305-689-5899  
E-mail: rruizcordero@  
med.miami.edu

*Recibido:*  
15/12/2014  
*Aceptado:*  
06/02/2015

are similar to those described in neurons and other cells.<sup>8-12</sup> However, the expression of Sy in human megakaryocytes (Mk) has not been previously described.

Mk are hematopoietic cells in charge of platelet production. Each Mk produces around 1000 to 3000 platelets.<sup>13-15</sup> During platelet production, the alpha granules that contain platelet-derived growth factor, platelet factor 4 and von Willebrand factor, as well as the dense granules that contain serotonin and calcium, are transferred from the cytoplasm of the Mk to the platelets before their release into the circulation, by mechanisms that are not well understood.<sup>11,13,16</sup> Platelet mass is directly proportional to Mk mass, and both masses tend to be constant throughout life.<sup>17</sup> Nevertheless, multiple studies have shown that under specific pathologic circumstances, the behavior of the Mk has a direct impact on the overall peripheral platelet population.<sup>18,19</sup> For example, diseases such as immune thrombocytopenic purpura (ITP) or myelodysplastic syndrome (MDS) display characteristic alterations in the size, number and ploidy of the Mk,<sup>20</sup> and subsequently, in the morphologic and functional characteristics of the platelets.<sup>21,22</sup>

Herein, we performed an observational study on bone marrow biopsies and report, for the first time, the expression of Sy in the cytoplasm of human Mk by immunohistochemistry using a specific antibody.

## OBJECTIVE

To determine the expression of Sy in the cytoplasm of human Mk by immunohistochemistry using a commercially available immunoperoxidase stain.

## MATERIAL AND METHODS

We collected clinical and histopathologic information from a group of bone marrow biopsies that were performed at the University of Miami Hospital/Sylvester Comprehensive Cancer Center for evaluation of relapse or for diagnostic or staging purposes in patients with hematologic malignancies (not restricted to acute leukemias). This study was approved by the Institutional Review Board

(IRB). Subsequently, we obtained 4-micron-thick unstained slides from formalin-fixed, paraffin-embedded tissue and stained them using a monoclonal antibody –anti-human Sy– (IR660, DAKO, Denmark) and a polyclonal antibody –anti-human FVIII– (IR527/IS527, DAKO, Denmark) for comparison. Bone marrow core biopsy specimens performed for staging of lymphomas, to rule out metastatic disease, or for work-up of non-neoplastic conditions whose final interpretation was negative for tumor/disease were used as controls. The expression intensity of Sy was arbitrarily scored using a progressive scale of 1 to 4 plus (+/+ +/+ +). For comparison, the expression intensity of FVIII was used as a standard (+/+ +/+ +). Subsequently, to determine a possible difference in the expression intensity of Sy, bone marrow biopsies were grouped according to diagnosis into benign or malignant. All malignant diagnoses were established following the 2008 World Health Organization guidelines for the diagnosis of hematopoietic neoplasms. To assess the difference in the intensity of the staining between the two groups, we employed a Mann-Whitney-Wilcoxon procedure using the statistical software R (R Core Team [2013], Vienna, Austria). A p-value of < 0.05 was considered significant. Results are expressed in absolute and relative values.

## RESULTS

A total of 20 bone marrow biopsies (15 cases and five controls) belonging to 11 male and nine female patients with a median age of 52 years (interval: two to 83) were stained for Sy and FVIII. *Table I* demonstrates the age, gender, clinical diagnoses, and the estimated expression of Sy and FVIII based on immunohistochemistry. In summary, the diagnoses of the cases were: ITP = 4, acute myeloid leukemia = 3, MDS = 7, and acute megakaryoblastic leukemia associated with Down's syndrome = 1. Cytoplasmic expression of Sy was observed in all (100%) the Mk of the controls and in 13 of 15 (90%) cases. In two of the four (50%) bone marrow biopsies with a diagnosis of ITP, the Mk did not stain for Sy (*Figure 1, L*). FVIII was

**Table I.** Summary of the sample. The study sample is illustrated according to gender, age in ascending order, clinical diagnosis or previous biopsy proven diagnosis in case of follow-up, and intensity of Sy and FVIII. Additionally, the diagnoses are grouped in four categories.

Gender	Age (years)	Diagnosis	Group	Sy intensity	FVIII intensity
F	2	AMKL + Down Sx	Leukemia	+++	++++
M	2	Congenital neutropenia	Control	+++	++++
F	10	Thrombocytopenia	ITP	+++	++++
M	16	Thrombocytopenia	ITP	+++	++++
M	23	Ewing's sarcoma staging	Control	+	++++
M	23	Thrombocytopenia	ITP	0	++++
F	39	AML post chemotherapy	Leukemia	+++	++++
M	41	AML Inv. 16	Leukemia	++++	++++
M	46	Pancytopenia and sepsis	Control	++	++++
F	49	MDS follow-up	MDS	++++	++++
F	55	Work-up acetabular lesion	Control	+++	++++
M	63	Rule out MDS	MDS	++++	++++
M	64	MDS transforming to AML	MDS	+++	++++
M	65	Residual MDS	MDS	++++	++++
F	66	AML Del. 5q	Leukemia	++	++++
F	66	MDS Del. 5q	MDS	++++	++++
M	68	MDS/RARS/Thrombocytosis	MDS	++++	++++
F	68	Lymphoma Staging	Control	++	++++
M	73	MDS/RA/ Del. -20q	MDS	++++	++++
F	83	Thrombocytopenia	ITP	0	++++

AMKL = Acute megakaryoblastic leukemia; Sx = Syndrome; ITP = Immune Thrombocytopenic purpura; MDS = Myelodysplastic syndrome; AML = Acute myeloid leukemia; Inv = Inversion; Del = Deletion; RARS = Refractory anemia with ringed sideroblast; RA = Refractory anemia; Sy = Synaptophysin.

positive in all Mk. The expression intensity of Sy in bone marrow biopsies grouped as benign (controls and ITP, mean = 1.8) was not significantly different from those biopsies grouped as malignant (leukemias and MDS, mean = 2.2). The Mann-Whitney-Wilcoxon test showed a median difference of 1.2 (95% CI = -4.9 to 2.0,  $p = 0.74$ ). Figure 1 illustrates the staining characteristics of selected cases.

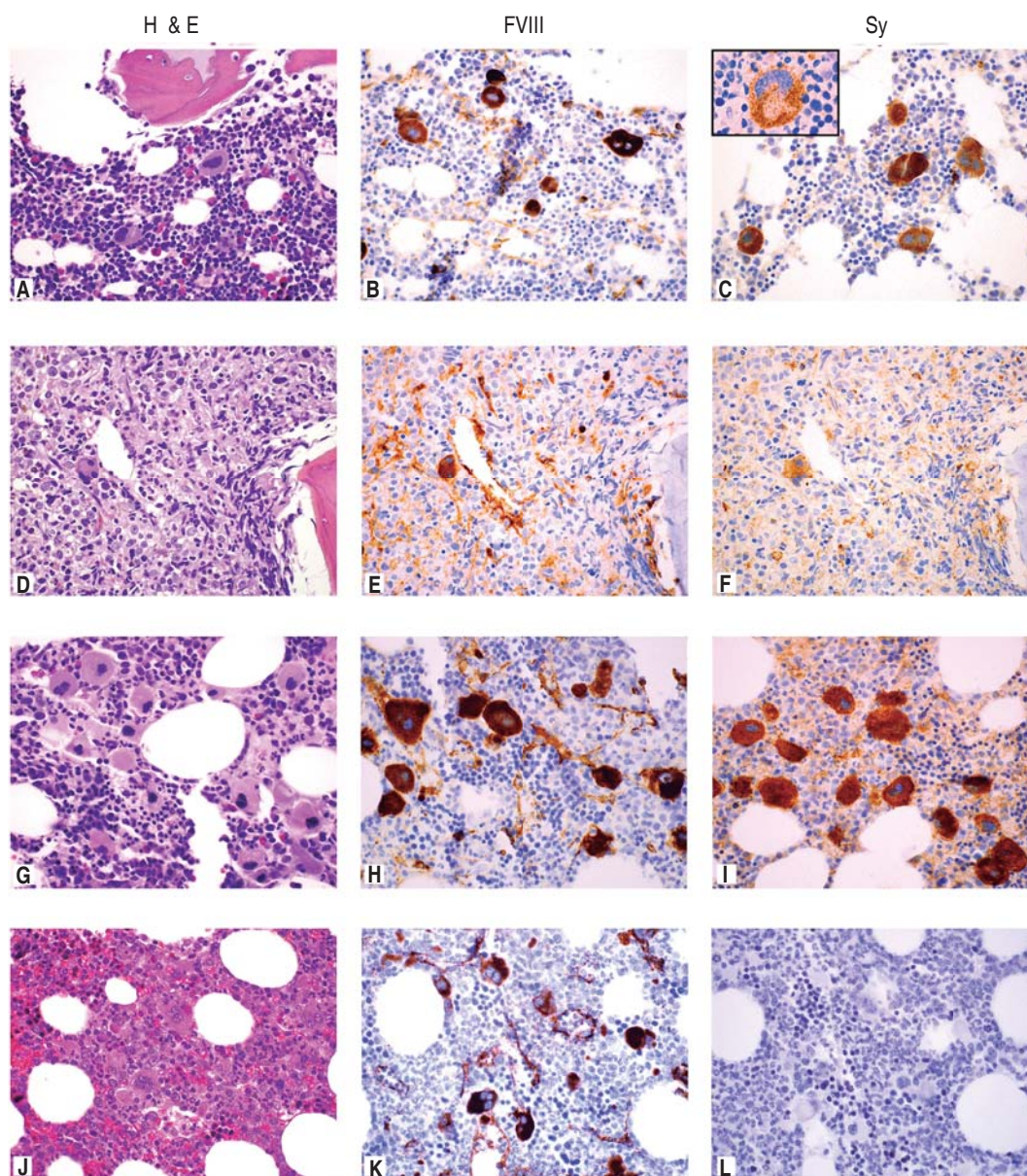
## DISCUSSION

The present study demonstrates that Sy is commonly present in the cytoplasm of human Mk. In this study, we did not observe a specific pattern of expression associated with age, sex or clinical condition. The initial impression that neoplastic bone marrows display a stronger expression of Sy did not reach statistical significance when assessed by an arbitrary grading methodology. However, more specific

patterns of expression could be determined by increasing the sample size.

It is also important to ponder that only one type of monoclonal antibody was used. Although the possibility of cross-reactivity with similar proteins of the same family, i.e., granulophysin,<sup>23,24</sup> pantophysin,<sup>25</sup> syntaxin,<sup>10</sup> synaptotagmin,<sup>26</sup> cannot be completely excluded, our findings reveal that the protein that we observed is present in human Mk and, more important, that this protein might be lost in a subset of patients with ITP, as is the case of patients with Hermansky-Pudlak syndrome, in whom the dense granule protein granulophysin is absent.<sup>12,23,24</sup> A report by Jayakumar et al.<sup>27</sup> demonstrates that low concentration of Sy and other synaptic proteins at the synapses correlates with altered neurotransmission. Similar phenomena could occur in other forms of exocytosis that employ analo-





**Figure 1.** Representative photomicrographs of the four categories of diagnoses. Rows represent an example of each diagnosis (Control, Leukemia, MDS, and ITP) and columns illustrate the type of stain (H&E: hematoxylin and eosin, 60X; FVIII: human factor VIII; Sy: synaptophysin). **A)** Bone marrow biopsy of a two-year-old boy with a clinical diagnosis of congenital neutropenia shows slight hypocellularity for age with maturing trilineage hematopoiesis. Note the normal endochondral ossification of the bone trabeculum. **B)** FVIII immunostain highlights Mk and some endothelial cells. **C)** Sy immunostain demonstrates strong cytoplasmic positivity in the Mk. The insert (100X) illustrates the granular cytoplasmic staining. **D)** Biopsy of a 66-year-old female with a diagnosis of AML and -5q deletion showing a replaced marrow by blasts and a residual Mk. **E-F)** Immunostains highlight the residual Mk. **G)** Biopsy of a 68-year-old male with a diagnosis of MDS, RARS and thrombocytosis demonstrates megakaryocytic hyperplasia with characteristic hypolobated and some small («dwarf») Mk. **H-I)** Strong positivity of FVIII and Sy is observed. **J)** Biopsy of a 23-year-old male with a diagnosis of ITP illustrates a normocellular bone marrow for age with mild compensatory megakaryocytic hyperplasia and normal morphology. **K)** FVIII highlights the presence of Mk and endothelial cells. **L)** Sy immunostain is completely negative.

gous mechanisms. Nonetheless, additional studies are necessary to confirm these hypotheses.

Additionally, our results demonstrate that the monoclonal antibody that we employed to perform this study can be used as a suitable alternative to FVIII to highlight the presence of Mk in the bone marrow.

Our study has the following limitations: 1) A small sample size that hampers more specific results. Increasing the study sample and including other hematologic diseases, predominantly those that are known to affect Mk and platelets, such as essential thrombocythemia, should allow for stronger conclusions. 2) Sy expression was assessed by immunohistochemistry with only one monoclonal antibody. The use of other commercially available antibodies would be encouraged to further confirm our findings. 3) Sy expression was graded by using an operator-dependent scoring system. More specific methodologies that could quantitate the expression of Sy would be necessary to establish a baseline concentration of Sy in normal Mk and to distinguish possible differences in other conditions.

In summary, the present study illustrates observational results that indicate that Sy is usually expressed in the cytoplasm of human Mk. Further studies are necessary to confirm these observations and to elucidate the clinical significance of such findings.

## CONCLUSIONS

Sy expression was frequently detected by immunohistochemistry in megakaryocytes regardless of disease process. However, Sy was not expressed in a subset of patients with ITP. The clinical significance of these findings and the potential role of Sy in megakaryocytes are currently unknown.

## REFERENCES

- Jahn R, Schiebler W, Ouimet C, Greengard P. A 38,000-dalton membrane protein (p38) present in synaptic vesicles. *Proc Natl Acad Sci USA*. 1985; 82 (12): 4137-4141.
- Wiedenmann B, Franke WW. Identification and localization of synaptophysin, an integral membrane glycoprotein of Mr 38,000 characteristic of presynaptic vesicles. *Cell*. 1985; 41 (3): 1017-1028.
- Valtorta F, Pennuto M, Bonanomi D, Benfenati F. Synaptophysin: leading actor or walk-on role in synaptic vesicle exocytosis? *Bioessays*. 2004; 26 (4): 445-453.
- Ozcelik T, Lafreniere RC, Archer BT 3rd, Johnston PA, Willard HF, Francke U et al. Synaptophysin: structure of the human gene and assignment to the X chromosome in man and mouse. *Am J Hum Genet*. 1990; 47 (3): 551-561.
- Knaus P, Betz H, Rehm H. Expression of synaptophysin during postnatal development of the mouse brain. *J Neurochem*. 1986; 47 (4): 1302-1304.
- Wiedenmann B, Huttner WB. Synaptophysin and chromogranins/secretogranins--widespread constituents of distinct types of neuroendocrine vesicles and new tools in tumor diagnosis. *Virchows Arch B Cell Pathol Incl Mol Pathol*. 1989; 58 (2): 95-121.
- Bähler M, Cesura AM, Fischer G, Kuhn H, Klein RL, Da Prada M. Serotonin organelles of rabbit platelets contain synaptophysin. *Eur J Biochem*. 1990; 194 (3): 825-829.
- Brunger AT. Structural insights into the molecular mechanism of calcium-dependent vesicle-membrane fusion. *Curr Opin Struct Biol*. 2001; 11 (2): 163-173.
- Brunger AT. Structure of proteins involved in synaptic vesicle fusion in neurons. *Annu Rev Biophys Biomol Struct*. 2001; 30: 157-171.
- Chen D, Lemons PP, Schraw T, Whiteheart SW. Molecular mechanisms of platelet exocytosis: role of SNAP-23 and syntaxin 2 and 4 in lysosome release. *Blood*. 2000; 96 (5): 1782-1788.
- Flaumenhaft R. Molecular basis of platelet granule secretion. *Arterioscler Thromb Vasc Biol*. 2003; 23 (7): 1152-1160.
- Lemons PP, Chen D, Bernstein AM, Bennett MK, Whiteheart SW. Regulated secretion in platelets: identification of elements of the platelet exocytosis machinery. *Blood*. 1997; 90 (4): 1490-1500.
- Deutsch VR, Tomer A. Megakaryocyte development and platelet production. *Br J Haematol*. 2006; 134 (5): 453-466.
- Wright J. The origin and nature of blood platelets. *Bost Med Surg J*. 1906; 154: 643.
- Wright J. The histogenesis of the blood platelets. *J Morphol*. 1910; 21: 263.
- Kaushansky K. Historical review: megakaryopoiesis and thrombopoiesis. *Blood*. 2008; 111 (3): 981-986.
- Brecher G, Cronkite EP. Morphology and enumeration of human blood platelets. *J Appl Physiol*. 1950; 3 (6): 365-377.
- Penington DG, Olsen TE. Megakaryocytes in states of altered platelet production: cell numbers, size and DNA content. *Br J Haematol*. 1970; 18 (4): 447-463.
- Harker LA, Finch CA. Thrombokinetics in man. *J Clin Invest*. 1969; 48 (6): 963-974.
- Kobayashi Y, Ozawa M, Maruo N, Kondo M. Megakaryocytic ploidy in myelodysplastic syndromes. *Leuk Lymphoma*. 1993; 9 (1-2): 55-61.
- Brummitt DR, Barker HF, Pujol-Moix N. A new platelet parameter, the mean platelet component, can demonstrate abnormal platelet function and structure in myelodysplasia. *Clin Lab Haematol*. 2003; 25 (1): 59-62.
- Hicsonmez G, Gumruk F, Cetin M, Ozbek N, Tuncer M, Gursel T. Bernard-Soulier-like functional platelet defect in myelodysplastic syndrome and in acute myeloblastic leukemia associated with trilineage myelodysplasia. *Turk J Pediatr*. 1995; 37 (4): 425-429.
- Gerrard JM, Lint D, Sims PJ, Wiedmer T, Fugate RD, McMillan E et al. Identification of a platelet dense granule membrane protein that is deficient in a patient with the Hermansky-Pudlak syndrome. *Blood*. 1991; 77 (1): 101-112.
- Nishibori M, Cham B, McNicol A, Shalev A, Jain N, Gerrard JM. The protein CD63 is in platelet dense granules, is deficient in a patient with Hermansky-Pudlak syndrome, and appears identical to granulophysin. *J Clin Invest*. 1993; 91 (4): 1775-1782.
- Haass NK, Kartenbeck MA, Leube RE. Pantophysin is a ubiquitously expressed synaptophysin homologue and defines constitutive transport vesicles. *J Cell Biol*. 1996; 134 (3): 731-746.
- Li C, Ullrich B, Zhang JZ, Anderson RG, Brose N, Sudhof TC. Ca(2+)-dependent and -independent activities of neural and non-neural synaptotagmins. *Nature*. 1995; 375 (6532): 594-599.
- Jayakumar AR, Tong XY, Curtis KM, Ruiz-Cordero R, Shamaladevi N, Abuzamel M et al. Decreased astrocytic thrombospondin-1 secretion after chronic ammonia treatment reduces the level of synaptic proteins: *in vitro* and *in vivo* studies. *J Neurochem*. 2014; 131 (3): 333-347.