



Fist 1,200 cases with Doppler-guided hemorrhoidal artery ligation (Follow-up of 550 patients)

JP Eitenmueller,*
A Dembek,* D Latz*

* Department of Surgery from St. Rochus-Hospital.

Address for correspondence:

JP Eitenmueller

St. Rochus-Hospital

GlückaufstraBe 10

44575 Castrop-Rauxel

Germany

Tel: (0 23 05) 294-2200

Fax: (0 23 05) 294-2269

E-mail: j.eitenmueller@rochus-hospital.de

Abstract

Introduction: Until now we treated 1,200 patients with hemorrhoids of grade II, III and IV using the Doppler-guided hemorrhoidal artery ligation. In a follow-up of 550 patients we investigated the surgical outcome, the functional recovery, and postoperative pain. **Method:** Using an analgesia and local anaesthesia in 1,200 patients under sonographic identification and suture ligation of six or more terminal branches of the superior rectal artery above the dentate line. Surgical and functional outcomes were assessed about 12 months after surgery. **Results:** There were 39.6 percent females and 60.4 percent males, the median operative time was about 20 minutes. 95 percent of the patients were treated in an outpatient surgery, only 5 percent were treated for different reasons as inpatient surgery. There was no mortality. There was only a very small percentage of urinary retention, bleeding and relapses, most patients had a complete functional, recovery by the third postoperative day. Only 4 percent of patients had a local relaps, which required rubber band ligation or other surgery. On follow-up there was no report of incontinence to gas or feces, fecal impaction, or persistent pain. **Conclusion:** Our experience indicates that Doppler guided hemorrhoidal artery ligation is safe and effective and can be performed as an outpatient procedure with a combination of an analgesedation and local anaesthesia with minimal postoperative pain and early recovery.

Key words: Hemorrhoids, piles, Doppler-guided artery ligation, surgical outcome, satisfaction rate.

Resumen

Introducción: Hasta ahora tratamos a 1,200 pacientes con hemorroides grados II, III y IV. Usando la ligadura de la arteria hemorroidal guiada por Doppler. En un seguimiento de 550 pacientes, investigamos el resultado quirúrgico, la recuperación funcional y el dolor postoperatorio. **Método:** Usando una analgesia-sedativa y anestesia local en 1,200 pacientes bajo identificación sonográfica y ligadura por sutura de seis o más ramas terminales de la arteria hemorroidal superior por encima de la línea dentada. Los resultados quirúrgicos y funcionales fueron revisados alrededor de 12 meses después de la cirugía. **Resultados:** Del total de los pacientes hubo; 36.9% de mujeres y 60.4% de hombres, el tiempo operativo medio fue alrededor de 20 minutos. El 95% de los pacientes fueron tratados en cirugía ambulatoria o pacientes externos, sólo el 5% fueron tratados por diferentes razones como cirugía hospitalaria o pacientes internos. De las complicaciones postratamiento hubo un paciente con retención urinaria, sangrado intermitente. La mayoría de los pacientes tuvieron una completa recuperación funcional. Para el tercer día postoperatorio sólo el 4% de los pacientes tuvieron recaídas locales, los cuales requirieron una ligadura con banda elástica y otro con cirugía-hemorroidectomía. En el seguimiento no hubo reportes de incontinencia a los gases o heces ni impactación fecal o dolor persistente. **Conclusiones:** Nuestra experiencia indica que la ligadura de la arteria hemorroidal guiada por Doppler es segura y efectiva y puede efectuarse como un procedimiento ambulatorio con una combinación de analgesia-sedación y anestesia local con un mínimo de dolor postoperatorio y pronta recuperación.

Palabras clave: Hemorroides, ligación arterial guiada por Doppler, resultados quirúrgicos y porcentaje de satisfacción.

INTRODUCTION

In the modern community many people suffer from hemorrhoids in their different stages. Many therapeutic options for the treatment of symptomatic hemorrhoids exist, as there are dietary and lifestyle modifications and office treatment.

As office treatments infrared coagulation, sclerotherapy, rubber band ligation and various stapling and excisional procedures are in use.¹⁻⁴ Nonoperative modalities of these treatments are applicable for most patients with hemorrhoidal symptoms, but there is only a therapeutic benefit in low grade hemorrhoids. So a lot of patients will only have a benefit from operative hemorrhoidectomy. The problems with conventional surgery consist of postoperative pain and considerable time of from work and normal daily activities as well as operative complications. These problems are well known by the patients, so a lot of them refused to get an operative treatment in the common sense. All over an operative hemorrhoidectomy may be contra-indicated in some patient, e.g. suffering from incontinence, severe heart or lung failure etc.

In this situation an alternative method which causes reduce pain and creates good results, is desirable. In 1995 Morinaga⁵ first reported an alternative method of treating hemorrhoids by transanal hemorrhoidal dearterialization using a specially designed anoscope coupled with a Doppler transducer. Dearterialization was done by a ligaturing of the arteries detected by a Doppler transducer. This minimal invasive ambulatory procedure was developed as an option for patients who were candidates for operative hemorrhoidectomy. Different authors like Sohn,⁶ Arnold,⁷ Meintjes,⁸ Jongen,⁹ applied this approach to different number of patients and considered it to be an effective alternative to operative hemorrhoidectomy and worthy of further studies and investigations.

This study was designed to assess the benefits of the Doppler guided hemorrhoidal artery ligations in terms of surgical outcome, functional recovery and postoperative pain in large patient cohort, with a one year follow-up and later follow-up of late results.

PATIENTS AND METHODS

Our investigative study was conducted as a continual running investigation on a total number of 1,200 patients until now with symptomatic grade II or III, sometimes grade IV hemorrhoids. All these hemorrhoids were operated by the first author between January 2003 until November 2007. In gaining experience within the running investigation we changed the operative procedure in doing

more ligations (of first 3 to 4, now 6 to 7) and in lifting up stage IV hemorrhoids by suture.

Exclusion criteria were only severe stages of grade IV hemorrhoids, acutely thrombosed piles or concurrent anal pathology (e.g. fissures etc). Patients suffering from grade II hemorrhoids were considered suitable for surgery because of the severity of symptoms (e.g. profuse bleeding) despite previous conventional less invasive treatments and were also scheduled for surgery at their own specific request.

The patients underwent a medical history with emphasis on hemorrhoidal symptoms, previous conservative or operative treatment or other anorectal conditions. We carried out a clinical examination, an anoscopy and rigid rectoscopy and colonoscopy if necessary to get an accurate staging of the disease and rule out other colorectal conditions. Every patient, older than 50 years, got a colonoscopy or was requested to obtain a colonoscopy a short time later.

The four outcome measures were symptomatic recurrence, postoperative pain, incidence of complications and patients' satisfaction at the follow-ups. All patients had to meet 2 appointments with the surgeon. At the first date, examinations were carried out and the patients had to sign an acceptance sheet and they received an information sheet. Operative treatment itself was done on an other date, all operative procedures were done as outpatient surgery.

OPERATIVE TREATMENT

We used a specially developed anoscope incorporating a side viewing (Hemo-Dop, Compumedics, Singen Germany *Figure 1*) for identifying and selectively ligating the submucosal terminal branches of the superior hemorrhoidal artery. This technique, as described by Morinaga,⁵ relies on the reduction of hemorrhoidal arterial flow to eliminate hemorrhoidal symptoms. The ligations are performed above the dentate line in a relatively insensitive region and this is reported to be associated with less postoperative pain, shorter hospital stay and early return to normal daily activities.

Operative procedure was performed with patient in lithotomy position. We used local anaesthesia of 15 mL of lidocaine plus 5 mL of bicarbonate, which were injected into the submucosa and the intersphincteric groove. An analgesedation was performed by intravenous administration of Novalgine, 5 mL and 5 to 10 mg of midazolam by continuous pulseoxymetric circulation surveillance.¹⁰

It is very important to have a good local anaesthesia of the sphincter in men who have a longer sphincter with a higher muscular torus in the anal canal, otherwise the insertion of the anoscope is painful.



Figure 1. Anoscopy (Hemo-Dop).

After Yylocaine jelly had been applied to both the Doppler anoscope and to the anus, the anoscope was inserted into the anorectum and the Doppler head was situated approximately 1 or 2 cm above the dentate line. The anoscope was then slowly rotated around the entire circumference, focusing on the anterior, right, right posterior, left posterior, left and left anterior position (1, 3, 5, 7, 9 and 11 o'clock) where the terminal branches of the superior hemorrhoidal artery are typically located. In all patients with arterial sound and signal were clearly audible, when the Doppler device was located directly on the hemorrhoidal artery. The common equipment does not allow to calculate the depth of the artery below the mucosa. Our equipment for research purposes gives this information about the depth of the artery. Is there an artery in the depth of 6.7 or 8 mm we did not try to ligate them because these are arteries on the outside wall of the rectum. Through the anoscope window we performed 6 to 7 "figure of eight" stitches (Vicryl with ct-2 plus needle)

dle) for each of the branches detected by the Doppler device. We used a knot pusher to position and tighten the knot. Dependign on the curved needle the suture depth was between 3 to 5 mm to reach the submucosal branches of the superior rectal artery. Important was the controlling of the protrusion of the needle tip throughout the anoscope window with regard to the surgical technique. Ligation of the vessel was confirmed by the absence of the Doppler arterial singal distal to the suture line except the artery was below the soft tissue layer more than 6 to 7 mm, see above. The second survey was made to ensure the accuracy of the procedure and to perform some more stitches in case of arterial sounds were still undetected in the tissue below the mucosa.

In cases of submucosal artery is hurt by the needle tip, which causes submucosal bleeding and swelling, the tissue is protruded into the instrument like a mushroom and the special anoscope is fixed. In these cases one should push a compress into the anoscope, pressing out the swollen soft tissue and then you can twist the instrument and continue the operative procedure. Postoperatively all patients got a rectoscopy for controlling the operative situs. Patients were discharged after two hours of observation on the ward and checking bye the physician. All patients received pain killers as tablet in medium dosis for some days.

Every patient got a call from the surgeon a day after the operation. There was no planned re-examination in the days after the operative treatment. Patients were followed up about 12 months after the operation, they were asked for their judgement of the operative procedure, post procedure pain, incidence of complications, symptomatic recurrence and patients' satisfaction. Every patient was asked to return to hospital immediately when "feeling to have a complication".

RESULTS

Until now we treated about 1,200 patients with this method. The follow-up was done about 12 months after treatment using a questionnaire with 550 patients. There were 39.6 percent females, 60.4 percent males. Distribution of age (*Figure 2*): The reported discomfort and pre-operative side findings are demonstrated in *figures 3 and 4*. The median operative time was 20 minutes and we were able to identify and ligate six to seven arteries in all patients. Most patients ($n = 98$) were treated as outpatients and were discharged from hospital about two hours after the operative procedure, 11 patients were admitted for overnight observation because of accelerated age, severe conditions of heart and lung function or there got an additional other treatment. Our results according to postoperative pain, complications

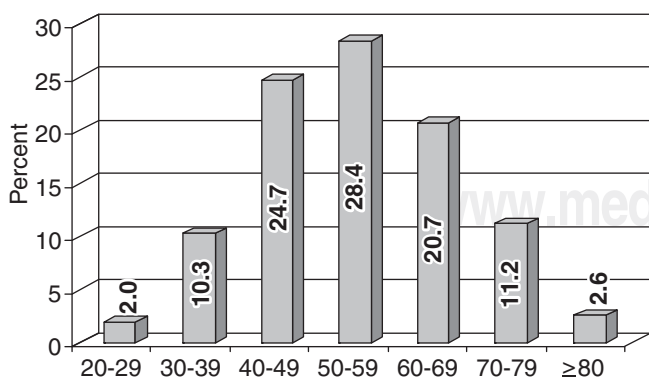


Figure 2. Distribution of age ($n=550$).

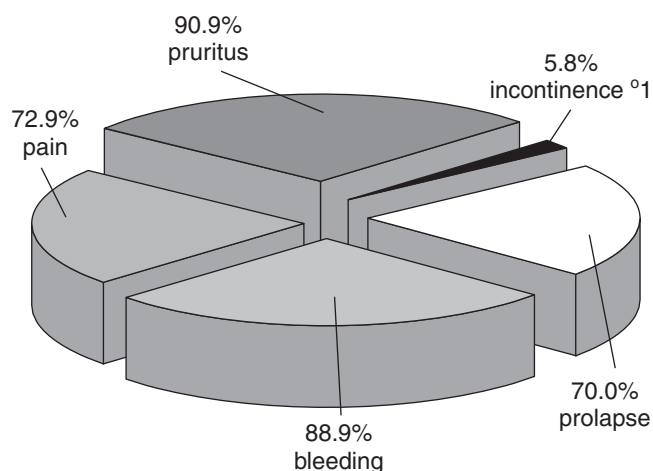


Figure 3. Preoperative discomfort (n=550).

after HAL and postoperative side findings are documented in figures 5, 6 and 7. The six patients with a postoperative bleeding required treatment and we had to do some more stitches at the point of bleeding under usual operative conditions. No patient needed a blood transfusion. Three patients with a peri-anal abscess received common surgical proctological treatment as usually in these indications. There is the question if this local infection was caused by the application of HAL method. Patients with urine retention which have been old men could be treated by urine catheter and administration of alpha blockers. The patients with postoperative side findings which did not depend on

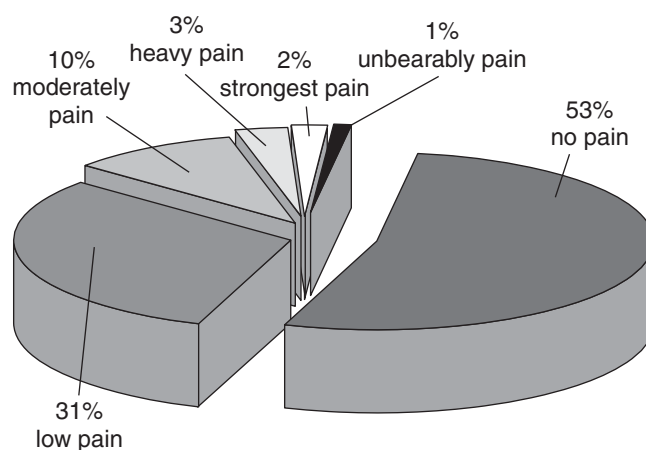


Figure 5. Postoperative pain (n=550).

the HAL procedure got the common proctological treatment. All patients with a stage III hemorrhoids reported complete functional recovery by the third or fourth postoperative day. The patients with stage IV hemorrhoid reported one week till functional recovery and relief from painful stitches below the dentate line in lifting up the severely descendent hemorrhoids.

DISCUSSION

Fist degree and second degree bleeding internal hemorrhoids should be post treated with bulk laxatives or stool softeners. In cases of recurrence office treatment such

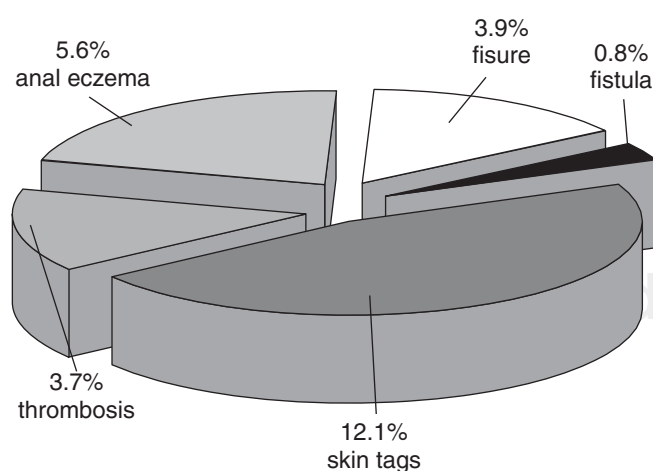


Figure 4. Preoperative sidefindings (n=550).

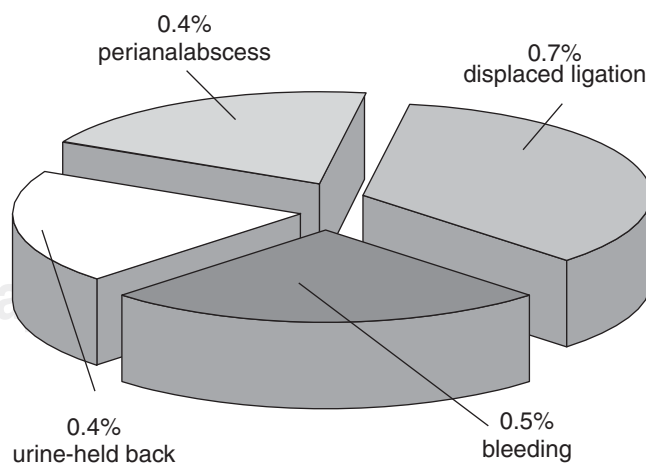


Figure 6. Complications after HAL (550).

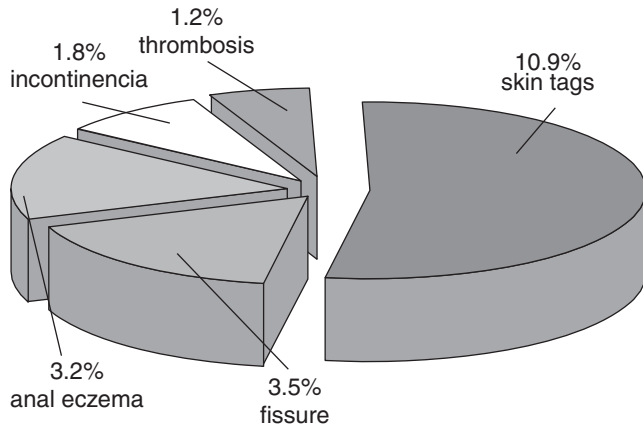


Figure 7. Postoperative sidefindings (n=550).

as sclerotherapy, rubber band ligation or infrared coagulation, may be useful and have advantage of being relatively painless, easy to use and with minimal complications. Patients who do not respond to the above mentioned procedures and for complicated cases, other methods excisional hemorrhoidectomy like Milligan Morgan or Milligan Morgan/Fergusson are usually reserved. These operative procedures are considered to be effective but may be associated with severe complications such as persisted pain, impaired anal continence, anal stenosis, rectal perforation, pelvic sepsis and also recurrence.¹²⁻¹⁵

Stapled hemorrhoidectomy introduced by Longo¹¹ by means of transanal stapled technique requires a specially designed circular stapler, which is very costly. The principle of this technique is twofold: first, the disruption of the superior rectal artery and, by that, reduction of the inflow to the hemorrhoids and, second, the restoration and fixation of internal hemorrhoids to the normal physiologic position, thereby preventing prolapses and related symptoms. The stapled anastomosis is well above the dentate line, therefore patients are reported to experience less pains compared with the traditional hemorrhoidectomy as e.g. Milligan Morgan/Fergusson. According to Kolbert¹² the outcome after stapler hemorrhoidectomy does not depend solely on the complete interruption of the arterial inflow of the hemorrhoids, flow can still be detected by Doppler ultrasound in the main branches of the superior rectal artery in as many as 80 percent of the patients. Anatomic finding were conducted by Aigner, Austria¹³ the terminal branches of the superior rectal artery solely supply the hemorrhoidal plexus. The course of the arterial branches could assign to exactly define positions in the rectal sumucosa (3', 7' and 11'), as viewed in the anatomic lithotomy position, corresponding with the

clinical appearance of the piles. The hemorrhoidal artery ligation technique interrupts these terminal branches at approximately 2-3 cm above the dentate line. The target is to reduce the blood supply to the hemorrhoidal plexus and thus to shrink the hemorrhoids. In 1995, Morinaga⁵ first described Doppler guided hemorrhoidal artery ligation and reported decreased hemorrhoidal blood flow, reduced bleeding, decreased hemorrhoidal size and a practically painless procedure. He did not use treatment of the pain. The disadvantages reported were possible damages to the prostatic urethra of vagina and obliteration of the veins with a paradoxical swelling of the hemorrhoids. None of these side effects were present in any of our 1,200 patients. Until now the optimal treatment modality of hemorrhoids may be still undetermined. Our results are promising, that the Doppler guided approach is a minimal invasive, new technique that is associated with less pain than historic controls, short recovery period and low complication rate, and is well tolerated by the patients. The pain score reported by our patients at the time of 12 months after treatment was considerable lower than those described in other series reporting the used of stapled hemorrhoidectomy or traditional operative treatment. Nearly all of our patients were operated on using an ambulatory setting and were discharged after short observation. All patients with stage II or III returned to normal daily activities by third to fourth operative day. Patients who were self employed went to work the first postoperative day. Our results are similar to the results reported by other studies that evaluated the efficacy of this technique. There is one exception: We also used the method in stage IV patients and lifted the down hanging hemorrhoids up by suturing. This caused more pain and therefore we had in the final result a higher level of reported pain.

CONCLUSION

Doppler guided hemorrhoidal artery ligation is indicated in patients with internal hemorrhoids in grades II, III and also in grade IV. It is a technique which requires experience to get good results, with a need of local anesthesia and analgesia in day care setting and it is an efficacious procedure in this population.

REFERENCES

1. Law WI, Chu KW. Triple rubber band ligation for hemorrhoids: prospective, randomized trial of use of local anesthetic injection. *Dis Colon Rectum* 1999; 42: 363-6.

2. Lentini J. Diathermy haemorrhoidectomy [letter]. *Int J Colorectal Dis* 1993; 8: 55.
3. MacRae HM, McLeod RS. Comparison of hemorrhoidal treatment modalities. A meta-analysis. *Dis Colon Rectum* 1995; 38: 687-694.
4. Ho YH, Cheong WK, Tsang C et al. Stapled hemorrhoidectomy-cost and effectiveness. Randomized, controlled trial including incontinence scoring, anorectal manometry, and endoanal ultrasound assessments at up to three months. *Dis Colon Rectum* 2000; 43: 1666-75.
5. Morinaga K, Hasuda K, Ikeda T. A novel therapy for internal hemorrhoids, ligation of the hemorrhoidal artery with a newly devised instrument (Moricorn) in conjunction with a Doppler flowmeter. *Am J Gastroenterol* 1995; 90: 610-3.
6. Sohn N, Aronoff JS, Cohen FS, Weinstein MA. Transanal hemorrhoidal dearterialization is an alternative to operative hemorrhoidectomy. *Am J Surg* 2001; 182: 515-9.
7. Arnold S, Antonietti E, Rollinger G, Scheyer M. Doppler-guided hemorrhoid artery ligation. A new treatment of hemorrhoids. *Chirurg* 2002; 73: 269-273.
8. Meintjes D. Doppler-guided haemorrhoidal artery ligation (HAL) for treatment of haemorrhoids – Results in 1,415 patients. See under: <http://www.cjmedical.com/haemorrhoids/clinicalstudies.html>
9. Jongen J, Stübinger S-H, Bock J-U, Peleikis H-G. Results (Short- and Medium-Term) after Doppler-Guided Hemorrhoid Artery Ligation (HAL). *Coloproctology* 25. 2003. Nr. 13
10. Argov S, Levandovsky O. Radical, ambulatory hemorrhoidectomy under local anesthesia. *Am J Surg* 2001; 182: 69-72.
11. Longo A. *Treatment of hemorrhoidal disease by reduction of mucosa and hemorrhoidal prolapse with circular stapling device: a new procedure*-6th World Congress of Endoscopic Surgery. Bologna: Monduzzi Editore, 1998: 777-84.
12. Kolbert GW, Raulf F. Evaluation of Longo's technique for hemorrhoidectomy by Doppler ultrasound measurement of the superior rectal artery. *Zentralbl Chir* 2002; 127: 19-21.
13. Aigner F, Bodner G, Conrad F et al. The superior rectal artery and its branching pattern with regard to its clinical influence on ligation techniques for internal hemorrhoids. *Am J Surg* 2004; 187: 102-8.