



Perineal endometrioma with anal sphincter involvement. Case report

Carlos Geovanny Torres Dugarte,*
Lourdes Rivero,*
Dina Gil,**
Pedro Salinas***

* Colorectal Surgeon. Hospital Sor Juana Inés de la Cruz. Radiology.
** Hospital Sor Juana Inés de la Cruz.
*** Colorectal Surgeon. Hospital Universitario de los Andes.

Address for correspondence:
Carlos Geovanny Torres Dugarte
Medicine Schools Faculty of Medicine. Mérida, Venezuela.
E-mail: Torrescarlos12@gmail.com
Carlostorres867@hotmail.com

Este artículo puede ser consultado en versión completa en
<http://www.medigraphic.com/coloproctologia>

Abstract

Perineal endometriosis is a disease characterized by the presence of endometrial tissue in the perineal region. Perineal endometriosis with anal sphincter involvement is an infrequent occurrence. In many cases it is confused with granuloma, abscess, lipoma, adenopathy. The best treatment to obtain satisfactory cure consists in the wide excision, but it may cause incontinence if the anal sphincter is involved. Conversely, narrow excision may result in incomplete removal, with increased recurrence rates and need of additional hormonal therapy. In this paper we describe a 45 year old patient, with diagnosis of perianal endometrioma with anal sphincter involvement. The patient went through surgery with wide excision and preserved anal sphincter. After one year follow-up there were not complications reported by fecal incontinence. In contrast, the perineal endometriosis is considered an infrequent occurrence of pelvic endometriosis.

Key words: Endometriosis, perineal endometriosis, scar episiotomy.

Resumen

La endometriosis perineal es una enfermedad caracterizada por la presencia de tejido endometrial en la región perineal. La endometriosis perineal con involucración del esfínter anal no es frecuente. En muchos casos, es confundido con granulomas, abscesos, lipoma y adenopatía. El mejor tratamiento para obtener cura satisfactoria consiste en la excisión ancha, pero puede causar incontinencia si está involucrado el esfínter anal. Al contrario, una excisión estrecha puede resultar en extracción incompleta, con el incremento de índices de recurrencia y la necesidad de terapia hormonal adicional. En este papel describimos una paciente de 45 años con diagnóstico de endometrioma perianal con involucración del esfínter anal. La paciente se sometió a cirugía con excisión ancha y preservó el esfínter anal. Después de 1 año de seguimiento, no hubo complicaciones reportadas de incontinencia fecal. En contraste, la endometriosis perianal es considerada una ocurrencia infrecuente de la endometriosis pélvica.

Palabras clave: Endometriosis, endometriosis perineal, cicatriz de episiotomía.

INTRODUCTION

Endometriosis is a disease characterized by the presence of endometrial glands and stroma outside the uterine cavity (Sydel et al. 1996). The most frequent location is the region pelvis, including ovaries, uterine ligaments, rectovaginal septum and peritoneum (Adamson 1990, Puerta et al. 1999, D' Andrea et al. 2002). Implantation may occur occasionally outside the pelvis, such as: small intestine, appendix, surgical incisions and perineum (Markham et al. 1989). The endometriosis places are most: ovaries (60-75%),

uterosacral ligaments (30-65%), uterus (4-20%), and rectosigmoid colon (3-10%). The less common places are: appendix (2%), ureter (1-2%), terminal ileum (1%), bladder (< 1%) abdominal scars (< 1%), (Snyder and Stryker 2007). The most rare implantation occurs in diaphragm, inguinal canal, liver, spleen and kidney (Snyder and Stryker 2007). Endometriosis is one of the most common conditions requiring surgery in women during their reproductive years. This disease, although not fatal, may be associated with disabling pain and intractable infertility (Beck et al. 2009). The true prevalence of endometriosis is unknown. Various

authors have estimated that up to 15% of all women of reproductive age and one-third of infertile women have endometriosis (Has son 1976, Darke and Grunert 1980). Recent studies indicates that this is due to autologous transplantation of vital endometrial cells to an open episiotomy wound during vaginal delivery especially when manual uterine exploration and postpartum curettage are performed, it seems to be the pathogenic mechanism of perianal endometriosis (Toyonaga et al. 2006). Endometrial lesions have a typical appearance of blue nodules. At the level of the ovaries, the disease is progressive, leading to form the so-called «chocolate cysts» (Sayfan et al. 1991, Puerta et al. 1999).

CASE REPORT

A 45 year old female patient, who was referred with history of severe perineal pain and tenesmus of two year of evolution associated with evacuations, correlating with her menstrual periods. The symptoms worsened during last months, resulting in functional limitation and discomfort during her sitting and daily activities, often needing the administration of several antibiotics for presumed perineal infection process. Her medical history was significant due to previous pregnancies with two vaginal delivery requiring episiotomy. At physical examination we found a patient in good general conditions. Anorectal examination was performed with the patient in the left lateral position without previous anorectal preparation. The anal region had normal appearance. At palpation we could see a hard nodule measuring 3 x 4 cm in the right anterior perineal region, irregular and very painful, was palpated in the right ischio-rectal fossa area, intimately associated to the scar of episiotomy. The patient had a good sphincter squeeze tone and a good resting tone at digital rectal examination. On physical examination she has good sphincter tone during and during contraction in the digital rectal examination. Endorectal ultrasound was performed by using a General Electric Logic Expert with a lineal rectal probe of 7.5 MHz, after fleet enema administration or anorectal preparation. The endosonography revealed a hypoechoic mass containing cystic anechoic areas in the anterior perineal intimately associated with the external anal sphincter (*Figures 1 and 2*). The examination was performed in April 2008, under spinal anesthesia and jack knife position (*Figure 3*). Radial incision, including a portion of the episiotomy scar was performed, it showed a mass in the right anterior position which included outside portion of the site of the episiotomy scar (*Figure 4*). The mass was dissected and the resection medially was completed from the ischio-rectal space was attached, incorporating a small portion of external anal sphincter. The mass had

clear and well defined borders. It was removed without injury to the anal sphincter (*Figures 5 and 6*). The divided excised specimen showed characteristic chocolate cysts (*Figures 7, 8 and 9*). Histopathological examination confirmed endometriosis with endometrial glands and typical stroma, blood and hemosiderin macrophages. The postoperative course had no complications, and the patient remained in the one day hospital. The patient is asymptomatic without evidence of any signs of recurrence after one year follow up of surgery and has excellent functional results (good resting and squeeze tone).

DISCUSSION

The first reported case of endometriosis with perineal involvement was in 1923 by Schickele. Minvielle and de la Cruz (1968) first described endometriosis in the anal canal. Endometriosis is a disease characterized by the presence of endometrial glands and stroma and hemosiderin pigments outside the uterine cavity. It is one of the most common conditions requiring surgery for women during their reproductive years.

This disease is a very common gynecological disease, because in the majority of women is associated with pelvic pain, dyspareunia and dysmenorrhea. The colorectal surgeon and gastroenterologist may encounter endometriosis involving the intestinal tract and specific perineal region. It may be asymptomatic or cause symptoms related to inflammation, obstruction or bleeding. These areas of ectopic tissue can be seen deposited in the bowel serosa, most commonly in the sigmoid and rectum, followed by the small bowel and the appendix (Macafee and Creer 1960, Puerta et al. 1999, Olive and Schwartz 1993, Williams and Pratt 1997, Beck et al. 2009).

The incidence of endometriosis occurs between 30 and 40 year old (Puerta et al. 1999), as it was in this case. The perineal endometrioma with affectation the anal sphincter appears after the episiotomy or laceration during childbirth. The scar of episiotomy is a site uncommon of occurrence of endometriosis and the affectation of anal sphincter occurs infrequently (Sayfan et al. 1991). The contact of the endometrium tissue with a episiotomy scar plays an important role in the origin of endometriomas (Puerta et al. 1999). The diagnosis may be difficult, but it is necessary a careful medical history, with symptoms correlated to the menstrual cycle. The characteristics of physical examination provide additional clues. The mass perineal and perineal body may be hard and not fluctuant, as would be associated with an abscess, and frequently is adjacent to an existing episiotomy scar. The objective is to excise the endometriomas completely, which may compromise the

anal sphincter. This may need primary sphincteroplasty to decrease the risk of fecal incontinence. Patients treated with complete wide excision and primary sphincteroplasty had no recurrences and no complications (Dougherty and Hull 2000). However, anal sphincter invasion of the endometriomas provides an interesting dilemma. When the lesion was incomplete or narrowly excised, subsequent hormonal therapy was required to avoid symptomatic recurrence. A definitive histologic diagnosis of perineal endometrioma usually requires two

of the following three features: stroma, glands and hemosiderin pigment. Correct preoperative diagnosis may be difficult (Gordon et al. 1976, Toyonaga et al. 2006). There are some complementary studies for the diagnosis. Endorectal ultrasound has evolved into an effective tool for the accurate preoperative assessment of pathologic anorectal disease (Kumar and Scholefield 2000).

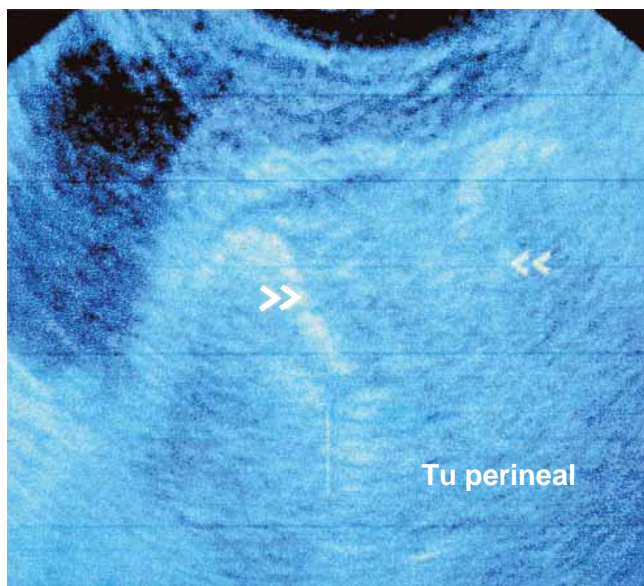


Figure 1.

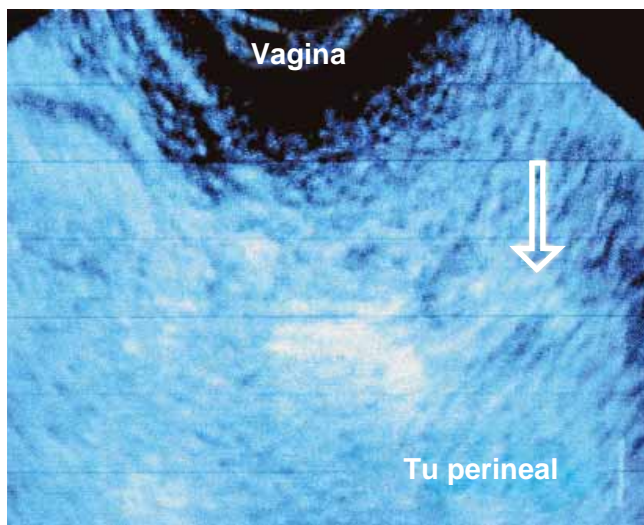


Figure 2.

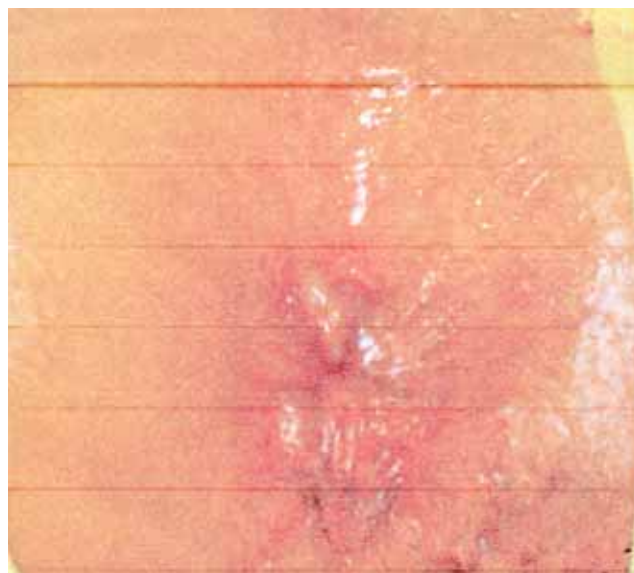

Figure 3. Jack knife position.

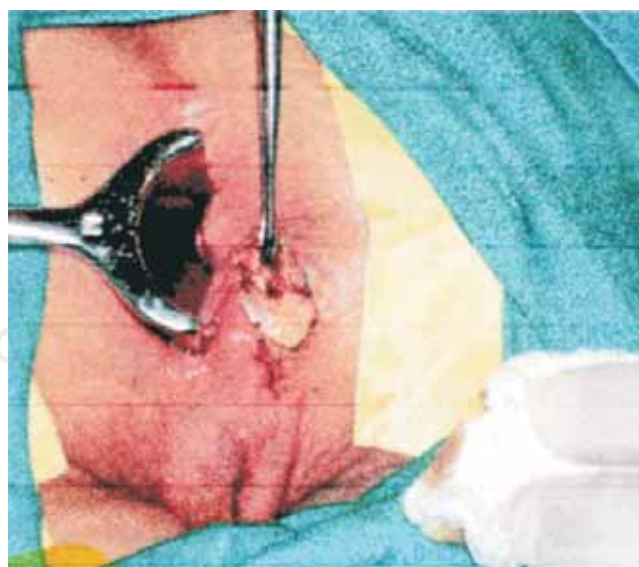

Figure 4. Radial incision longitudinal on mass. Palpable lesion in right perineal.

The endorectal ultrasound allows and makes easier an appropriate surgical procedure and provides perineal endometriosis patients with a good clinical outcome. Toyonaga et al. (2006) consider that this procedure is essential for diagnosis and operative management of perineal endometriosis. Togashi et al. (1991) affirm that

they prefer the use of magnetic resonance imaging for the diagnosis of endometrioma anal with a sensitivity of 90% and specificity of 98%. Although hormonal suppression is often the therapy of choice for extrapelvic endometriosis, surgical excision, keeping the anatomical fiber architecture of the anal sphincter, is the best treatment for perineal endometriosis (Gordon et al. 1976, Sayfan et al. 1991, Bacher et al. 1999, Toyonaga et al. 2006). Only surgery can provide the histologic specimens required to rule out the rare development of malignancy in patients with extragenital endometriosis (Todd et al.

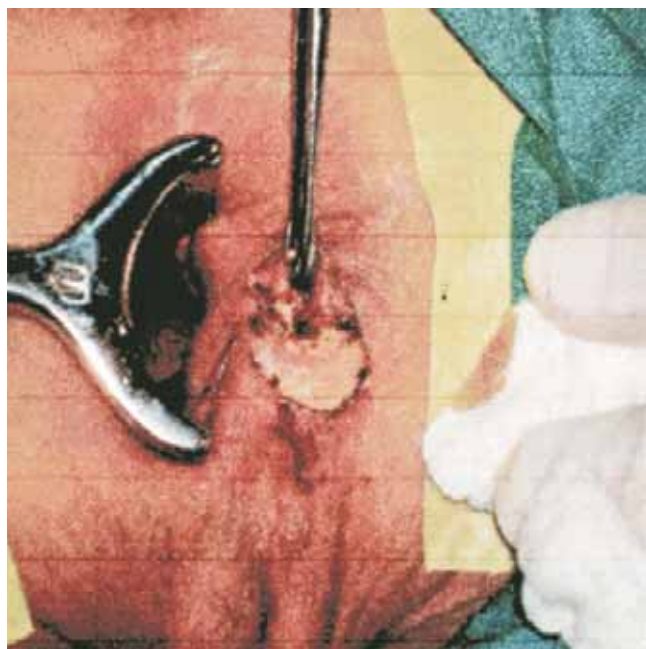


Figure 5. *Dissecting mass.*

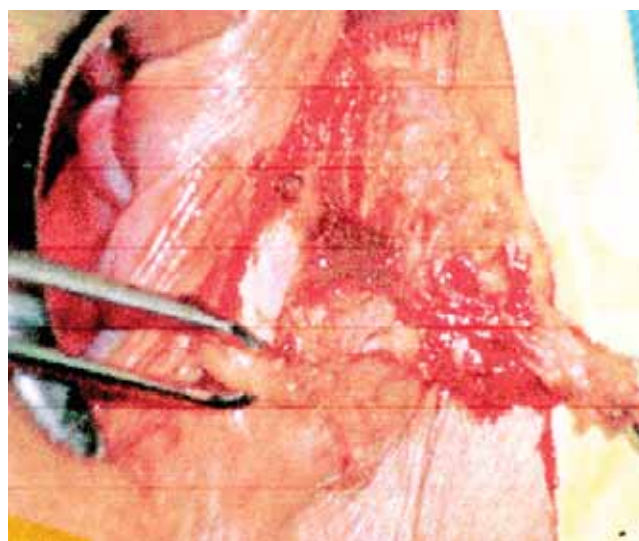


Figure 7. *Open lesion with characteristic chocolate cysts.*

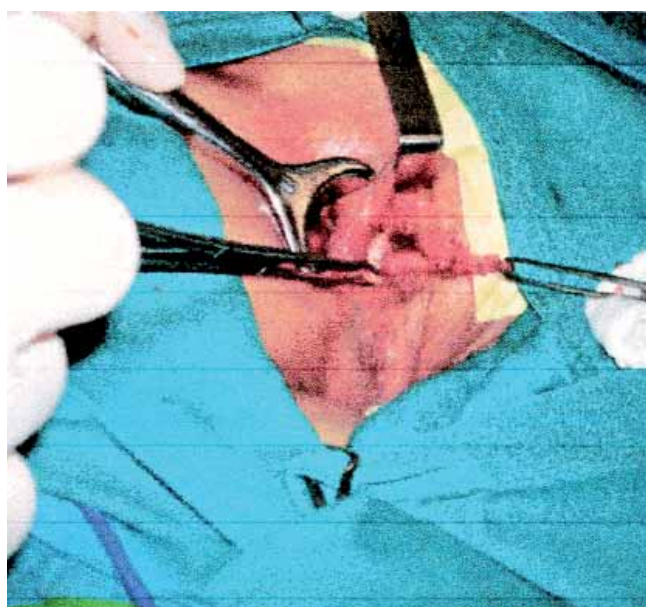


Figure 6. *Excised endometrioma.*

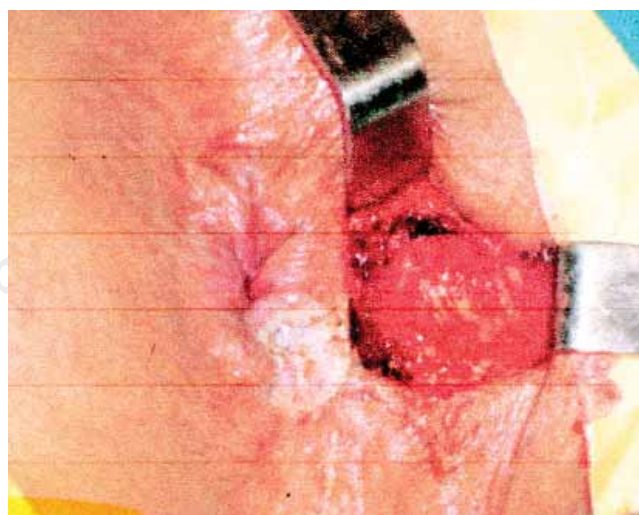


Figure 8. *Cavity posterior to extraction.*

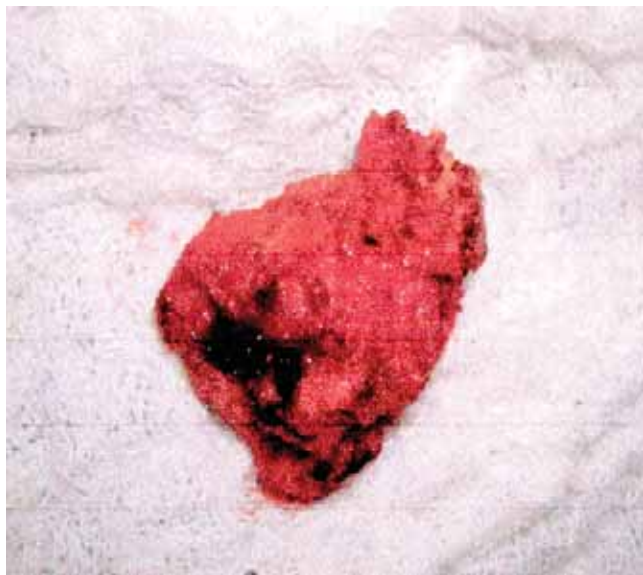


Figure 9. Excised endometrioma mass.

2000). Wide excision, in which a margin of normal tissue and muscle is excised with the mass, provides the best chance of cure but may cause incontinence (Puerta et al. 1999, Dougherty and Hull 2000), when the anal sphincter mechanism is involved (Sayfan et al. 1991). Narrow excision or a very tiny margin is removed, may result in incomplete removal, with an increased risk of recurrence and need for additional therapy. Perineal endometriosis with involvement of the anal sphincter occurs infrequently (Sayfan et al. 1991, Bacher et al. 1999, Todd et al. 2000, Dougherty and Hull 2000). This patient did not present postoperative fecal incontinence in a follow-up period of 16 months, leaving as an alternative if needed the reconstruction, with another surgery procedure, for example sphincteroplasty or more selected cases such as gracilis muscle transposition (Torres et al. 2008). The patient studied was referred to the gynecology service control and management for hormonal therapy. Tapia et al. (1995) affirmed that only three patients had partial sphincter compromise that needed resection in the follow up and had good results. The type of resection should be based on the patient's age and desire for future pregnancy, and the decision should be made only after potential outcomes according to the evolution of the patient.

BIBLIOGRAPHY

1. Seydel A, Zickel J, Warner E et al. Extrapelvic endometriosis: Diagnosis and treatment. *Am J Surg* 1996; 171: 239-41.
2. Adamson G. Diagnosis and clinical presentation of endometriosis. *Am J Obstet Gynecology* 1990; 162: 568-9.
3. Puerta JD, Castaño R, Hoyos S. Endometrioma del esfínter anal. *Rev Colombiana Cir* 1999; 14: 243-246.
4. Snyder M, Stryker S. The ASCRS Textbook of Colon and Rectal Surgery. *Springer* 2007; 21: 308-321.
5. Beck DE et al. The ASCRS Manual of Colon and Rectal Surgery. *Springer* 2009: 439.
6. Hasson HM. Incidence of endometriosis in diagnostic laparoscopy. *J Reprod Med* 1976; 16: 135-138.
7. Drake TS, Grunert GM. The unsuspected pelvic factor in the infertility evaluation. *Fertil Steril* 1980; 34: 27-31.
8. Markham S, Carpenter S, Rock J. Extrapelvic endometriosis. *Obstetric Gynecology Clin North Am* 1989; 16: 193-219.
9. Toyonaga T, Matsushima M, Tanaka Y et al. Endoanal ultrasonography in the diagnosis and operative management of perineal endometriosis: Report of two cases. *Tech Coloproctol* 2006; 10: 357-360.
10. Sayfan J, Benosh L, Segal M et al. Endometriosis in episiotomy scar with anal sphincter involvement. Report of a case. *Dis Colon Rectum* 1991; 34: 713-716.
11. Schickele M. Les pseudolipomes du ligament large. *Bull Mem Soc Anat Paris* 1923; 20: 603-605.
12. Minvielle L, de La Cruz JV. Endometriosis of the anal canal: presentation of a case. *Dis Colon Rectum* 1968; 11: 32-5.
13. Gordon PH, Schottler JL, Balcos EG et al. Perianal endometrioma: Report of five cases. *Dis Colon Rectum* 1976; 19: 260-265.
14. Olive D, Schwartz L. Endometriosis. *N Engl J Med* 1993; 328: 963-965.
15. Williams T, Pratt J. Endometriosis in 1,000 consecutive celiotomies. Incidence and management. *Am J Obstetric Gynecology* 1997; 129: 245-258.
16. Kumar A, Scholefield JH. Endosonography of the anal canal and rectum. *World J Surg* 2000; 24: 208-215.
17. Togashi K, Nishimura K, Kimura I et al. Endometrial cysts. *Diagnosis with MR imaging Radiology* 1991; 180: 73-8.
18. Bacher H, Schweiger W, Cerwenka H et al. Use of anal endosonography in diagnosis of endometriosis of the external anal sphincter: Report of a case. *Dis Colon Rectum* 1999; 42: 680-682.
19. Todd RW, Kehoe S, Gearty J. A case of clear cell carcinoma arising in extragonadal endometriosis. *Int J Gynecology Cancer* 2000; 10: 170-172.
20. Dougherty LS, Hull T. Perineal endometriosis with anal sphincter involvement: report of a case. *Dis Colon Rectum* 2000; 43: 1157-1160.
21. Tapia A, Rahmer A, Odolom A et al. Perineal endometriosis. Clinical experience with 8 patients. *Rev Med Chil* 1995; 122: 37-41.
22. Torres C, González P, Suárez L et al. Transposición del músculo Gracilis como alternativa en el tratamiento de la fístula rectovaginal persistente. Reporte de un caso y revisión de la literatura. *Revista Venezolana de Cirugía* 2008; 61: 82-86.
23. D'Andrea M, Vittorio De Prisco C et al. *Endometrioma perineal a propósito de dos casos*. Vitae. Academia Biomédica Digital. Abril/Junio no. 11. 2000.