

Frequency of Trauma by a Foreign Body in Rectum. Experience of 20 Years at the Hospital Civil of Guadalajara

Luis Bravo-Cuellar^{1,2}, Luis Andrés Medina-Padilla¹, Christopher Delgado-Sandoval¹, Enrique Daniel Martini-Corona¹, Cesar Carrillo-Padilla¹, Francisco del Socorro Preciado-Hernández¹, Shaya Betancourt-Vicencio¹, Alejandro Bravo-Hernández³, Alejandro Bravo-Cuellar^{4,5*}

¹ Servicio de Cirugía Medicina Legal, OPD Hospital Civil de Guadalajara Fray Antonio Alcalde, Guadalajara, Jalisco, México; ²Especialidad en Cirugía de Trauma, Centro Universitario de Ciencias de la Salud, de la Universidad de Guadalajara, Guadalajara, Jalisco, México; ³Universidad Autónoma de Guadalajara, Guadalajara, Jalisco, México; ⁴Centro de Investigación Biomédica de Occidente, IMSS, Guadalajara, Jal. Mx; ⁵Centro Universitario de los Altos, Universidad de Guadalajara, Tepatlán de Morelos, Jalisco, México.

RESUMEN

Introducción. La inserción de cuerpos extraños en el recto es una práctica frecuente, considerada como emergencia proctológica.

Objetivo. Se reportan 20 años de experiencia del Servicio de Cirugía de Trauma Toracoabdominal, Hospital Civil Fray Antonio Alcalde de Guadalajara, Jal., Méx.

Materiales y métodos. Estudio transversal (1999-2018), elaborado a partir de los archivos clínicos del hospital.

Resultados. Hubo un total de 194 pacientes, incluidos 169 hombres y 25 mujeres, con un rango de edad 15 a 91 años predominando el rango de 30 a 44 años con 75 casos (38 %). La incidencia fue entre 1999 y 2010 de 4.0 ± 2.1 pacientes por año, contra 15.4 ± 8.8 casos entre 2011-2018. Proctorragia fue el signo predominante (56 pacientes), seguido de sensación de cuerpo extraño (49 pacientes) y dolor abdominal (41 pacientes). El diagnóstico se basó principalmente en el examen rectal digital (100 %) y la radiografía abdominal simple (94 %). La extracción manual se realizó en el 82 % de los casos, la laparotomía en 10 casos (5 %) y la colonoscopia en 5 casos (2,5 %). La principal complicación fue el desgarro de la mucosa en 50 casos (57 %), el desgarro de la piel y la mucosa en 12 casos (14 %) y la perforación en 8 casos (9 %).

Conclusiones. La frecuencia de cuerpos extraños en el recto está aumentando y constituye un verdadero desafío para el cirujano debido a la enorme diversidad de variables.

Historial del artículo

Recibido: 4 jun 2020

Aceptado: 24 feb 2021

Disponible en línea: 1 may 2021

Palabras clave

Trauma, Cuerpo extraño, Recto

Keywords

Trauma, Foreign body, Rectum

Copyright © 2021 por autores y Revista Biomédica.

Este trabajo está licenciado bajo las atribuciones de la *Creative Commons* (CC BY).

<http://creativecommons.org/licenses/by/4.0/>

*Autor para correspondencia:

Alejandro Bravo-Cuellar, Centro de Investigación Biomédica de Occidente, IMSS, Sierra Mojada 800 Col. Independencia, CP 44340 Guadalajara, Jalisco, México. Tel (52) 3336189410. Email: abravocster@gmail.com <https://revistabiomedica.mx>.

ABSTRACT

Introduction. The insertion of foreign bodies into the rectum is a frequent practice which could lead to proctological emergencies. The practice is not an emergency *per se* but could precipitate emergencies.

Objective. This paper aims to present more than two decades of experience related to the management of rectal foreign body injuries at the Thoraco-Abdominal Trauma Surgery Service of Civil Hospital Fray Antonio Alcalde of Guadalajara, Jalisco, México.

Materials and Methods. A cross sectional study on a period of 20 years (1999-2018) was carried out based on the data recorded in the hospital's archives and included patients of both sexes with an age range between 15 and 91 years.

Results. There was a total of 194 patients (169 males and 25 females) with 75 cases (38 %) ranging between 30 and 44 years old. The incidence of foreign body induced rectal injuries was 4.0 ± 2.1 patients per year, between 1999 and 2018 and 15.4 ± 8.8 cases per year between 2011-2018. Proctorrhagia was the predominant sign (56 patients), followed by foreign-body sensation (49 patients) and abdominal pain (41 patients). Diagnosis was based mainly on digital rectal examination (100 %) and plain abdominal x-ray (94 %). Manual extraction was performed in 82 % of the cases, laparotomy in 10 cases (5 %) and colonoscopy in 5 cases (2.5 %). The main complications were mucosal tears in 50 cases (57 %), skin and mucosa tears in 12 cases (14 %), and perforation in 8 cases (9 %).

Conclusions. The frequency of foreign body related rectal injuries is increasing over the past years posing a real challenge for the surgeons due to the various complications and the distinct nature of their management and surgical repair. The on call surgeons must be familiarized with various treatment approaches from manual extraction, to endoscopic extraction, laparotomies and stoma formation. The complex nature of the surgical management and an increasing incidence of these injuries prompted the authors to share their experience on this topic.

INTRODUCTION

The insertion of foreign bodies into the anus and rectum is a relatively frequent practice with an increasing incidence over the past decade (1-3). Its requires taking into account medical,

legal, special human, and ethical factors, because the injuries and their mechanism of generation (voluntary and involuntary) are very diverse. Thus, rectal foreign bodies constitute and are considered a proctological emergency and represent a challenging and a unique type of rectal trauma (1).

Historically, the practice of inserting a foreign body into the rectum has been acknowledged from as early as the beginning of human life. Initial reports describing the management of injuries related to rectal foreign bodies insertion date from the 16th century, although the first official mentioning in a medical journal is attributed to Smiley who wrote about this topic in 1919 (4).

Based on previous reports from the literature, the mean age at presentation was 44 years (with a range of 20 to 90 years). Mostly young persons were affected, with an overwhelmingly higher proportion of males than females (17-37:1), (1, 5, 6).

The incidence varies from country-to-country or region-to-region; however, there are reports showing that nearly 20% of all rectal injuries are due to insertion of foreign bodies, sex toys being the most frequently involved objects (8). Fortunately, the majority of cases fail to cause significant anorectal injuries (7).

From the clinical point of view, the classification of the American Association for the Surgery of Trauma (AAST) continues to be employed to assess damage from rectal foreign-body injuries, as published by Moore et al. (9) and adapted by Cologne (7). Unfortunately, in our country the information is scarce, and the majority of publications comprise of reports of particular cases with few series of patients, describing a great variability of injuries caused by various objects. In addition, cultures and customs are different in each region; thus, each case is unique and probably requires special therapeutic strategies (10). Therefore, it is important for physicians to know and maintain an open mind regarding the existence of this type of human behavior and to identify the object and the manner in which the

object found its way into the rectum, in order to establish an adequate treatment.

This paper aims to describe the frequency of diagnosing rectal injuries produced by foreign bodies and to discuss the treatment options based on the experience from a tertiary-care medical facility in western Mexico.

MATERIALS AND METHODS

A cross-sectional study was carried out at the OPD Hospital Civil of Guadalajara “Fray Antonio Alcalde”, Guadalajara, Jalisco, México. The patients’ study files were selected from the Archives of the Surgery Department in Thoraco-Abdominal Trauma. All files from patients of both sexes, aged 15 years or older, with a foreign body in rectum diagnosed from January 1999 to December 2019, were included in the study, and incomplete files were excluded. Study variables included: age, sex, schooling, occupation, mechanism of rectal injury, type of object (size and shape), time from injury to presentation, diagnostic methods, treatment, and complications. Statistical analysis included central tendency measures and proportions. All data were organized and analyzed using Excel® Microsoft software (Redmond, WA, USA).

RESULTS

Sociodemographic Characteristics:

Of the 194 patients included in the study, 169 were male and 25 females, representing 87 % and 13 % of the population, respectively (Table 1). The youngest patient was 15 years old and the oldest 91. The incidence was higher in the fourth decade of life with 38 % of the patients having between 30 and 44yo, followed by 27 % between 45 and 59 years old and 22 % between 15 and 29 years old. As expected, patients in the sixth decade of life consisted of (9 %) of the cases, and only 2 % of the patients had between 75 and 91 years.

The level of education appears to play a significant role, since the highest frequency was

found within patients with lower levels of study. Thus, the Illiterate group was 11 %, primary-school group 53 % and that of the middle school 26 %. These groups together, accounted for 90 % of the total of 194 patients. The incidence decreases progressively as the academic level rises, to reach 6, 3, and 1 % for patients with high-school, professional and postgraduate studies respectively. On the other hand, marital status also revealed trends that can be easily observed; for example, the most affected group was the group of singles consisting of nearly 50 % of the population studied, followed by married patients (29 %) and couples in a common-law marriage (11 %). However, the lowest percentages were found among divorced (7 %), and widowed patients (4 %). All these results strongly suggest that there are sociocultural patterns that favor this type of practice.

Table 1. SOCIODEMOGRAPHIC CHARACTERISTICS

SEX	n/%
Male	169/87
Female	25/13
Total	194
AGE (years) / RANGE	n/%
15 to 29	44/22
30 to 44	75/38
45 to 59	52/27
60 to 64	18/9
75 to 91	5/2
SCHOOLING	(n / %)
Illiterate	21/11
Elementary	103/53
Middle school	51/26
High school	11/6
Professional	6/3
Post-graduate	2/1
MARITAL STATUS	(n / %)
Single	93/48
Married	57/29
Common-law marriage	22/11
Divorced	14/7
Widowed	8/4

In relation to frequency (Fig. 1), it can be observed that since 1999 this practice has been increasing, in such way that a mean of 2-19 patients were registered from 1999-2010, to reach high values in 2014 with 18 cases, and in 2017 with 32 cases, only to decrease in 2018 to 18 cases.

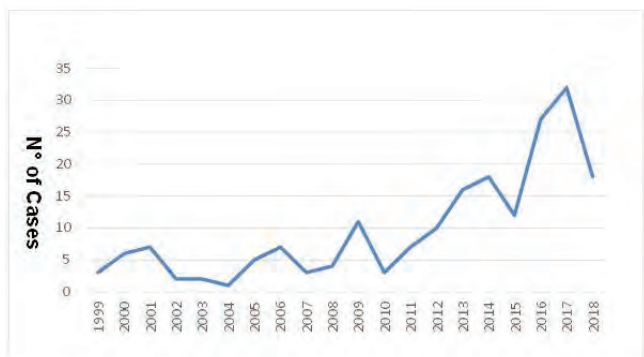


Fig. 1. Incidence of patients per year

Objects used

The main reason for presenting with a foreign body in the rectum is predominantly sexual, with 185 of the 194 cases studied (95%) related to sexual behaviors or circumstances and only 9 cases (5%) corresponding to accidents (Fig. 2). Unfortunately, in relation to groups involving a sexual behavior, voluntary and involuntary cases due to sexual aggressiveness, counted for almost the same number of events (91 and 94, respectively).

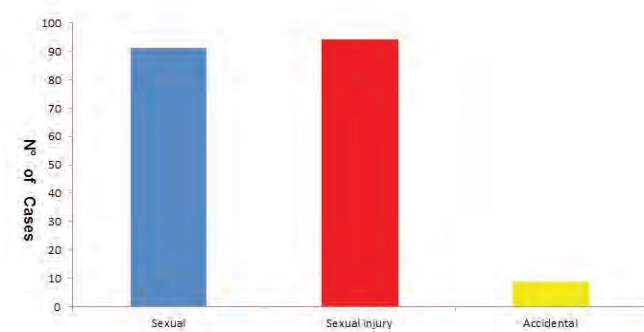


Fig 2. Reason for foreign body in the rectum

As expected, the objects found in the population studied were highly variable (Fig. 3). The

majority of the objects were phalluses (80%); different objects of glass and wooden sticks were reported in 16% of the cases, metal or plastic containers in 15% and sex toys in 12%. It is noteworthy that, in terms of all of the medical implications beyond clinical practice, drug bags were found in 8% of the cases. Finally, between 6 and 1% in decreasing order, miscellaneous objects such as fruits and vegetables, silicone objects, plastic bubbles, candles, metal rod, and tools were found. On the other hand, it is prudent to note that for phallic objects (made of various materials), average size was 37 cm for the largest and 1.5 cm for the shortest.

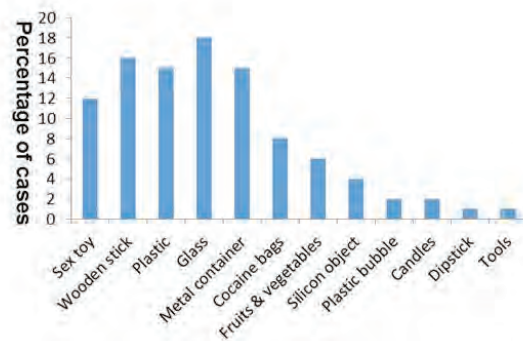


Fig 3. Type of object found in the rectum

Time of Evolution:

The hours between the event and the time of presentation vary. Presentation times can range from a few hours to 3 months, demonstrating practically 4 peaks at 4, 6, 12, and 24 hours, with 19, 17, 39, and 48 cases respectively, representing these peaks together the 48% of the whole population studied, the rest of reported times the number of patients vary of 1 to 8 cases (Fig. 4). Thus, there are definitely few patients who appear before 6 hours; the majority present at the Emergency Room 24 hours following the event, after attempting to extract these objects either manually or instrumentally with wire clothes hangers, soapy enemas, and laxatives.

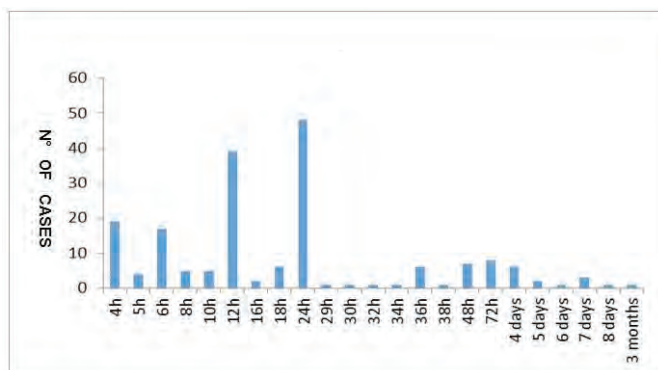


Fig 4. Time of evolution

Signs and Symptoms:

The predominant sign was proctorrhagia in 55% of the patients, followed by the presence of a foreign-body sensation, abdominal and perianal pain in 50% 45%, and 40% of cases respectively. In a smaller proportion between 10 and 20% of cases presented with abdominal distention, and acute abdomen: 1 case for rectum perforation and 2 for bowel obstruction. On the other hand, it is important to note that 18 cases were asymptomatic. Taking these results as a whole, we can suggest that the triad of the most common classic symptoms in these types of events comprises of proctorrhagia, the sensation of a foreign body, and abdominal and/or rectal pain (Fig. 5).

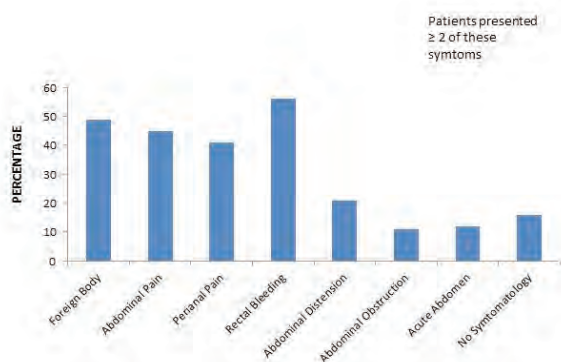


Fig 5. Symptomatology

Diagnosis:

The diagnosis included a detailed history and a digital rectal examination in 100% of the cases. Other studies included plain abdominal x-ray in 182 cases

representing 94% of all patients and computed axial tomography (CT) in 12 cases (6%). Thus, the digital rectal examination is the main diagnostic tool, along with abdominal radiography (Fig. 6).

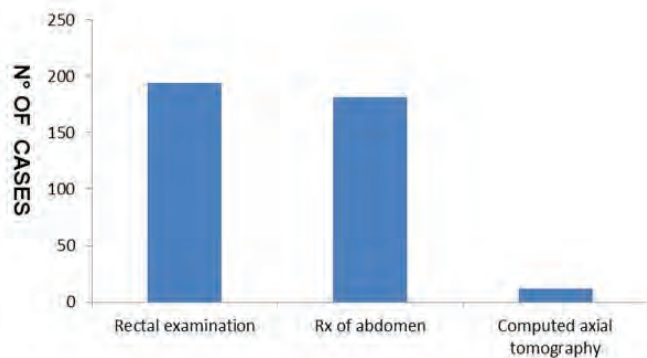


Fig 6. Diagnostic Methods

Treatment:

The results observed in Fig. 7 show that the most frequent procedure was manual extraction (82% of the cases), performed with sedation in 98 cases (51%) and without sedation in 61 (31%) cases. Less frequently employed methods for removal of the foreign body was induced evacuation in 20 of patients (10%), laparotomy in 10 patients (5%), and colonoscopy in 5 patients (2.5%).

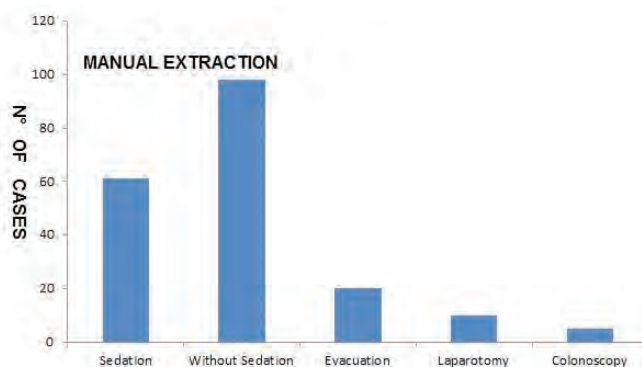


Fig 7. Treatment

Complications:

Complications can be divided into those that appeared before or after the extraction of the object. The largest number of complications occur prior to treatment, with mucosal tear being the most frequent

(50 cases) followed by a skin and mucosal tear (12 cases) and perforation (8 patients). Post-extraction complications are fewer than those observed prior to treatment, and again, the mucosal tear is the most frequent with 12 cases followed by sigmoid perforation with 2 cases and need for colostomy type Hartmann in 2 patients. There was only one death (Fig. 8).

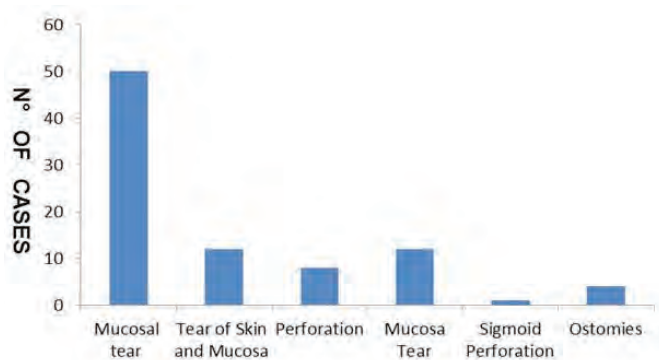


Fig 8. Complications

DISCUSSION

Transanal Insertion of foreign bodies is a worldwide problem with challenging implications for the attending physician. This is due not only to the uniqueness of each situation but also to the size, type, and texture of the objects used, the complexity of the treatment in severe cases, and the high risk of serious complications.

The incidence of this behaviour has shown gradual growth, which has nearly doubled over the past 10 years. This behaviour probably has increased due to the social and idiosyncratic changes of recent years, a more violent society, greater sexual freedom, etc. In this regard, Cologne *et al.*, in 2012 (7), report an incidence of one case per month, while Dahlberg reports (8), at the Stockholm South General Hospital that serves a population of 600,000, an incidence of 1.4-2.3 cases per 100,000 inhabitants in 2018, with a registration at the hospital of 85 patients with anal foreign bodies from 2009-2017, averaging 0.78 patients per month. At our hospital during the last 5 years, we have averaged 1.5-2.66 cases per month, and also demonstrating that the increase is

not only of the present, but one deriving from recent years: since 2000, there has been an average of 0.55 patients per month.

It is probable that the differences are due to the magnitude of the population treated at each hospital. Ours is a hospital that provides care for patients from several states of the Mexican Republic, with a much larger population than the average population found in the work of Dahlberg *et al.* (8). However, the incidence of this behavior must be taken with caution, in that many patients do not seek care or cases are not reported.

On the other hand, the majority of the studies consulted are in agreement that this type of problem has been reported from as early as 15 years, and that the upper age has virtually no limit, presenting a peak between 30 and 59 years, and averaging at an age of 40 years (10). In relation to sex, it is definitely much more frequent in men than in women, 87% vs. 13%, which also corresponds with that in the world literature (1, 7, 11). This work also includes data on education level and marital status that were not reported in other works. Apparently, there is an indirect relationship with schooling; therefore, the highest frequency was found in patients who had only attended elementary or middle school, and this frequency decreased to only two cases among patients with a postgraduate degree, revealing that the educational factor is important in this type of practice. Finally, in relation to marital status, it is striking that 48% were singles and 29% were married, suggesting a high rate of bisexuality in our population.

As expected for the majority of patients, the reason for the behavior was sexual in 91% of them vs. 9% for accidental; The discrepancy between voluntary and involuntary insertion of the foreign bodies however is apparently explained by the idiosyncrasy of the patients, a tendency to hide this behavior or provide false declarations with regard to the facts involved, especially when it becomes somewhat difficult to understand how the object could be introduced into the anus (12). In other reports, sexual self-stimulation was close to 50% of patients (5). Some patients who are frequent

visitors to the emergency room, even provide details regarding how the foreign objects were removed the previous time.

However, it is noteworthy that there are indeed cases, not a rarity, which are the result of an act of rape, revenge, humiliation, or shaming of the individual affected.

The great diversity and constitution of the objects employed are in agreement with the information in the literature, and it should be mentioned that the majority of these objects had a phallic similarity, suggesting sexual behaviors (5, 7, 8, 13). As for the size of the object, this was also highly variable, ranging from 1.5 cm in length to nearly 40 cm. In this respect, it can be mentioned that there is a report of a 20-cm-long eggplant (14), which is important due to the type of injury that may cause. However, we were unable to find data in the literature to perform a comparison with our observations.

Unfortunately, the majority of patients present at the hospital between 12 and 24 h after the occurrence of the event. At this point, we can consider that approximately 20% of patients will not divulge the history of the insertion of the foreign body into their rectum at presentation (2). The importance of the time delay is that there is greater inflammation, which makes it difficult to remove the foreign body and increases the possibility of perforation; the longest registered time passed from the insertion until the presentation was 3 months. In this regard, it is important to consider that it is probable that, due to the size of the object and pre-existing anal discomfort, some patients ignore its presence, as takes place with certain frequency with rectal-ointment applicators (10). In the present study, due to its poor casuistry, incidental findings were not taken into account. Another important point is to consider that sometimes the objects are not directly inserted into the anus, as is the case of some intrauterine devices, which rather pierce the tissues and advance intra-rectally (15).

The most effective diagnostic method includes rectal examination and abdominal radiography; computerized axial tomography was found to be less useful. In some centers tomography is used

more frequently; however, some authors do not lend routine importance to imaging, but continue to employ touch and x-rays (16). In this respect, it is necessary to consider that the majority of objects are radiopaque, which allows their detection and does not require more elaborate x-ray techniques. It should be noted that 100% of diagnoses were reached in our case studies, and it must be mentioned that the predominant sign was proctorrhagia. Therefore, in the Emergency Room, this diagnosis should always be considered in patients with sensation of a foreign body and pain, regardless if its origin is abdominal or perianal.

In relation to treatment, 82% of our casuistry benefited from the extraction of the foreign body manually. Only 7.5% of patients required more complicated methods, including 2.5%, colonoscopy and 5%, laparotomy. Based on the data from the literature, it is recommended to attempt extraction in the Emergency Room if there are no signs of peritonitis. Extraction rates were reported as successful in between 60 to 75% of cases. Our results confirm what has been reported (17-19). However, Dahlberg *et al.* (8), in their study of the insertion of sex toys, report that manual removal was not successful in 73% of cases. In this situation the authors reported the need for laparotomy in 8 of 85 cases (9.5%), colonoscopy in 3 cases (3.5%), vs. 5% and 2.5%, respectively reported in this work., it was not possible to establish the cause of these statistical differences in the reports; however while smaller objects can often be removed transanally, it is possible to consider that larger objects typically require a more invasive intervention (11). What is clear in the literature is that surgery will be required if the object reaches the sigmoid (10, 18). Finally, it is important to consider that, although fastest extraction of the foreign body is ideal, prudence is also recommended because, sometimes, the foreign body can exit spontaneously and a certain time for post-extraction observation is always recommended to avoid complications. This is due to that observation is not a waste of time, nor is the purchase of good-practice medical insurance. This is because in the majority of the cases these

patients remain in hospital for a short time, because extraction is achieved without great difficulty. Additionally, the patients usually request discharge as soon as possible, because they feel they are on display.

Complications arise with these objects mainly because of their size and their location inside the rectum (above the promontory), it is almost impossible for these objects to be passed spontaneously, making individual attempts to achieve this, in the most unlikely ways, to cause more damage than the insertion of the object itself. Points such as these appear to be in agreement with the literature, in that a tear is the most frequent occurrence, and that the tear occurs mainly at the time of insertion. The severity of the tear can lead to perforation; thus, it is always mandatory to exclude an acute abdomen, especially in its incipient stages.

CONCLUSION

At the end of this study, we can conclude that this type of pathology is not as rare as was considered previously at the end of the 20th century, and its incidence clearly is increasing. In terms of the clinical entity as such, it is shown that trans anal bleeding, lower abdominal pain, and signs of intestinal obstruction comprise the common denominators of patients with the presence of a foreign body in the rectum, whose intensity is reflected in the hours of evolution that the patient presents after insertion of the object. In addition, we must add that the injuries caused by the patient when the latter attempts to extract the foreign object increase the risk of severe complications, such as mucosal injury and/or intestinal perforation.

Regarding the prognosis, a speedy recovery and even the immediate discharge of the patient from the hospital will depend on the time of evolution that the patient presents, even if there is no difficulty when extracting the foreign object. This is due to that, at a longer evolution time, trauma can be generated in the mucosa of the intestine, which can cause ulcerative lesions and even perforations, which appear when the damaged tissue does not have the capacity to recover. Therefore, it is advisable to keep

the patient under surveillance in order to be able to act immediately if there are signs of intestinal perforation or abdominal sepsis.

The handling must be methodical; first, the inserted object must be identified (if possible) to assess its shape, especially if it presents sites with a point or edge, because this is decisive regarding the decision to attempt to extract the foreign object through the anal region or by means of surgery (abdominal laparotomy) since, with some frequency, the damage caused by the extraction of the foreign object is more serious than that caused by its insertion. Usually, x-rays and digital rectal examination are sufficient for the diagnosis.

Size is another of the questions required by the treating physician, in that large objects (greater than 15 cm on average) tend to stop at the angle formed by the sacral promontory, rendering anal extraction more difficult.

Consistency is critical, since there are objects that are compact (rigid and inflexible), which in addition to being challenging to handle, are those that cause the plunger effect. When attempting to pull the object, the latter gives rise to a contraction of the intestine when the object is encountered, which makes its mobilization impossible. In addition, one must bear in mind that despite being rigid, glass objects are very fragile and break into multiple fragments, which are most likely responsible for severe intestinal injuries. All of these points force us to decide on the type of extraction (manual or surgical) and whether the procedure requires sedation or anesthesia (regional or general).

If there arises a determination to intervene surgically by laparotomy, it is more advisable to perform a blind loop or Hartmann colonic ostomy. The prior revision and repair of the affected intestine ensures that, with this type of procedure, no excrement is present at the injury site, favoring the healing process of the damage and avoiding fistulas or abscesses in the region.

Thus, the management of this type of pathology involves its being treated by physicians with sufficient experience in the management of traumatic injuries of the colon, rectum, and anus, and the avoidance

of overhandling the region with multiple extraction attempts. The determination of proceeding with the surgical intervention should not be delayed for more time than it takes to prepare a patient for a surgical procedure of relative urgency.

REFERENCES

- Gentile M, Cestaro G, Di Filippo G, Amato B, Sivero L. Successful transanal removal of unusual foreign body self-inserted in the rectum A case report and review of literature. *Annali italiani di chirurgia* 2019 Oct;90:88-92. <http://www.annaliitalianidichirurgia.com/>
- Kurer MA, Davey C, Khan S, Chintapatla S. Colorectal foreign bodies: a systematic review. *Colorectal Dis* 2010 Sep;12:851-861. doi: 10.1111/j.1463-1318.2009.02109.x
- Kokemohr P, Haeder L, Fromling FJ, Landwehr P, Jahne J. Surgical management of rectal foreign bodies: a 10-year single-center experience. *Innov Surg Sci* 2017 May;2:89-95. doi: 10.1515/iss-2017-0021.
- Smile O. A glass tumbler in the rectum. *JAMA* 1919 May;72:1285. doi:10.1001/jama.1919.26110180004008c
- Alan Lucerna D. Foreign body insertions: A review. *Emergency Medicine*. 2017 July;49 (7):315-319. doi:10.1001/jama.1919.26110180004008c
- Griffin R, Mac Gwin G Jr. Sexual stimulation device-related injuries *J Sex Marital Ther* 2009 Jun;35 (4):253-261. doi: 10.1080/00926230902851249.
- Cologne KG, Ault GT. Rectal foreign bodies: what is the current standard? *Clin Colon Rectal Surg* 2012 Dec;25 (4):214-218. doi: 10.1055/s-0032-1329392.
- Dahlberg M, Nordberg M, Pieniowski E, Bostrom L, Sandblom G, Hallqvist-Everhov A. Retained sex toys: an increasing and possibly preventable medical condition. *Int J Colorectal Dis* 2019 Jan;34 (1):181-183. doi: 10.1007/s00384-018-3125-4.
- Moore EE, Cogbill TH, Malangoni MA, et al. Organ injury scaling, II: Pancreas, duodenum, small bowel, colon, and rectum. *J Trauma* 1990 Nov;30 (11):1427-1429. <https://ovidsp.ovid.com/ovidweb.cgi?T=JS&NEWS=n&CSC=Y&PAGE=toc&D=yrovft&AN=00005373-000000000-00000>
- Goldberg JE, Steele SR. Rectal foreign bodies. *Surg Clin North Am* 2010 Feb;90 (1):173-184. doi: 10.1016/j.suc.2009.10.004.
- Principe DR, Rubin J, Narbutis M, Cabrera J, Mitsiev I. Repeat presentation of large rectal foreign body requiring surgical intervention. *J Surg Case Rep* 2019 Apr; 2019(4):rjz121. doi: 10.1093/jscr/rjz121
- Cawich SO, Thomas DA, Mohammed F, Bobb NJ, Williams D, Naraynsingh V. A Management Algorithm for Retained Rectal Foreign Bodies. *Am J Mens Health* 2017 May;11(3):684-692. doi: 10.1177/1557988316680929.
- Dae Ro Lim JCK, Taehyung Kim, Eung Jin Shin. Surgery for intra-abdominal abscess due to intestinal perforation caused by toothpick ingestion Two case reports *Medicine* 2019 Sep;98 (36):1-5. doi:10.1097/MD.00000000000017032
- Sei H, Tomita T, Nakai K, et al. Rectal Foreign Body of Eggplant Treated Successfully by Endoscopic Transanal Removal. *Case reports in gastroenterology* 2018 Apr;12(1):189-193. doi: 10.1159/000488974
- Tavecchia M, Burgos Garcia A, de Maria Pallares P. Colorectal penetration by two intrauterine devices. *Revista espanola de enfermedades digestivas: Órgano oficial de la Sociedad Espanola de Patologia Digestiva* 2019 Apr;111(4):320-321. doi: 10.17235/reed.2019.5974/2018
- Coskun A, Erkan N, Yakan S, Yildirim M, Cengiz F. Management of rectal foreign bodies. *World J Emerg Surg* 2013 Mar;8 (11):11. <http://www.wjcs.org/content/8/1/11>
- Cawich SO, Mohammed F, Spence R, Albert M, Naraynsingh V. Colonic Foreign Body Retrieval Using a Modified TAMIS Technique with Standard Instruments and Trocars. *Case Rep Emerg Med* 2015 Apr; 2015. doi: 10.1155/2015/815616.
- Lake JP, Essani R, Petrone P, Kaiser AM, Asensio J, Beart RW, Jr. Management of retained colorectal foreign bodies: predictors of operative intervention. *Dis Colon Rectum* 2004 Oct ;47(10):1694-1698. doi: 10.1007/s10350-004-0676-4.
- Cohen JS, Sackier JM. Management of colorectal foreign bodies. *J R Coll Surg Edinb* 1996 Oct;41(5):312-315. <http://europepmc.org>, PMID: 8908954