

## Atypical socket repair in aesthetic implant rehabilitation

### *Reparación atípica de alveolo en rehabilitación estética implantológica*

Mauricio Toro<sup>1</sup> , Tomás Yoma<sup>1,2</sup> , Alain Manuel Chaple Gil<sup>3</sup> , Gloria Sánchez<sup>1</sup> , Eduardo Fernández<sup>4,5</sup>  

<sup>1</sup> University of Chile, Faculty of Dentistry, Department of Prosthetic Dentistry. Santiago de Chile, Chile.

<sup>2</sup> Universidad Politécnica y Artística del Paraguay. Paraguay.

<sup>3</sup> University of Medical Sciences of La Havana, Faculty of Medical Sciences "Victoria de Girón". Department of Comprehensive Dentistry. La Habana, Cuba.

<sup>4</sup> University of Chile, Faculty of Dentistry, Department of Restorative Dentistry. Santiago de Chile, Chile.

<sup>5</sup> Autonomous University of Chile, Institute of Biomedical Sciences. Santiago de Chile, Chile.



**Como citar:** Toro M, Yomas T, Chaple-Gil AM, Sánchez G, Fernández E. Atypical socket repair in aesthetic implant rehabilitation. Rev Cubana Estomatol. 2019;56(3):1-9.

#### ABSTRACT

**Introduction:** In implant therapy, adequate alveolar bone volume and favorable alveolar ridge architecture are important considerations to obtain positive functional and esthetic rehabilitation.

**Objective:** Describe prosthodontic treatment in an extraction socket with advanced palatal bone resorption secondary to a root fracture through the use of an implant-supported single fixed prosthesis.

**Principal case data:** 39-year-old male patient, without systemic disease, and completely dentate with no occlusal parafunction. Radiographic examination showed the presence of advanced palatal bone resorption, almost total loss of the palatal plate in all its extension secondary to a root fracture of the maxillary left lateral incisor and a large osteolytic area on the palatal aspect of the root. The procedure consisted in extraction of the maxillary left lateral incisor and eventual regeneration of the palatal plate using a resorbable collagen membrane, which was adapted to the bone defect. Then, particulate cortical bone allograft was compacted into the site. Four months after grafting the extraction site, an implant was placed. Six months after implant placement osseointegration was confirmed, and after several stages restoration with a zirconium dioxide abutment and a full ceramic crown was obtained and followed up for 2 years.

**Conclusions:** Regeneration of the palatal plate was possible through the use of particulate cortical bone allograft and a resorbable collagen membrane adapted to the bone defect and placed in position to recreate the palatal plate. This allowed installation

of an implant 4 months after the procedure. This technique allowed esthetic and functional results using a single fixed prosthesis.

**Keywords:** dental implant; alveolar bone grafting; allograft; osseointegration; dental socket.

## RESUMEN

**Introducción:** Para la terapia con implantes, un volumen adecuado de hueso alveolar y una arquitectura favorable de la cresta alveolar son consideraciones importantes para obtener una rehabilitación funcional y estética positiva.

**Objetivo:** Describir el tratamiento protésico en una cavidad de extracción con reabsorción ósea palatina avanzada secundaria a una fractura de la raíz, mediante el uso de una prótesis fija única con soporte de implante.

**Datos principales del caso:** Paciente masculino de 39 años, sin enfermedad sistémica, completamente dentado sin parafunción oclusal. El examen radiográfico mostró la presencia de una reabsorción ósea palatina avanzada, una pérdida casi total de la placa palatina en toda su extensión secundaria a una fractura de la raíz del incisivo lateral superior izquierdo y una gran área osteolítica en el aspecto palatino de la raíz. El procedimiento consistió en la extracción del incisivo lateral superior izquierdo y la regeneración posterior de la placa palatina mediante una membrana de colágeno reabsorbible, que se adaptó al defecto óseo. Luego, el aloinjerto de hueso cortical particulado se compactó en el sitio. Cuatro meses después de injertar el sitio de extracción, se colocó un implante. Seis meses después de la colocación del implante, se confirmó la osteointegración y, después de varias etapas, se obtuvo una restauración con un pilar de dióxido de circonio y una corona de cerámica completa, la que fue seguida durante dos años.

**Conclusiones:** La regeneración de la placa palatina fue posible mediante el uso de aloinjerto de hueso cortical particulado y una membrana de colágeno reabsorbible adaptada al defecto óseo y colocada en una posición para recrear la placa palatina. Esto permitió la instalación de un implante 4 meses después del procedimiento. Con esta técnica se obtuvieron resultados funcionales y estéticos utilizando una única prótesis fija.

**Palabras clave:** implante dental; injerto de hueso alveolar; aloinjertos; oseointegración; alveolo dental.

## INTRODUCTION

The alveolar process is a tooth-dependent structure, and its development is strictly connected with tooth eruption. Several changes could occur after tooth extraction, including a loss in height and width of the alveolar bone. Implant therapy can be considered successful only when functional and esthetic requirements have been accomplished. Therefore, both adequate alveolar bone volume and favorable alveolar ridge architecture are important considerations to obtain a positive functional and esthetic rehabilitation. Socket preservation procedures have been performed to preserve hard and soft tissue volume, which can be partially lost after tooth removal.<sup>(1)</sup>

An ideal situation would be that the extraction site heals with a bone formation that completely preserved or recreated the original dimensions of the ridge when the tooth

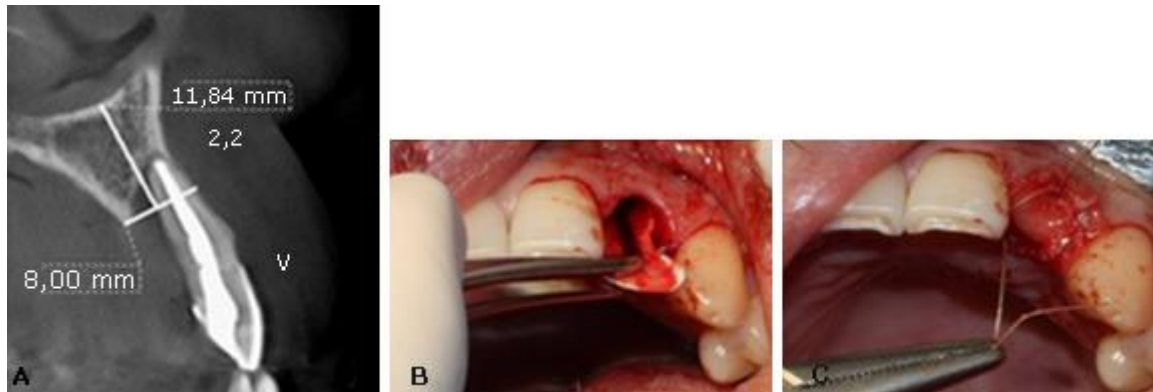
was present. Unfortunately, bone resorption is common after tooth extraction, which thus creates the need to intervene with a method to provide ideal bone for implant placement and reconstruction with an esthetic and functional restoration.<sup>(2)</sup> Successful management of the extraction socket can be challenging, particularly in the esthetic zone.<sup>(3)</sup> Different techniques appear to reconstruct lost tissue with enough bone volume for the placement of an osseo-integrated dental implant. The materials chosen to graft the extraction socket should include the following qualities:

1. The material should maintain space for the bone to repopulate the graft and thus recreate the bone volume similar to the original.
2. The bone formed should have the density to allow for stabile placement of the implant; thus, the material placed should have exciting osteoconductive features to enhance bone formation.
3. The material should be relatively inexpensive and readily available.

There are no cases reported in the literature with loss of the palatal plate, probably due to its complex regenerative process. This case report aimed to describe prosthodontic treatment in an extraction socket with advanced palatal bone resorption, through the use of an implant-supported single fixed prosthesis.

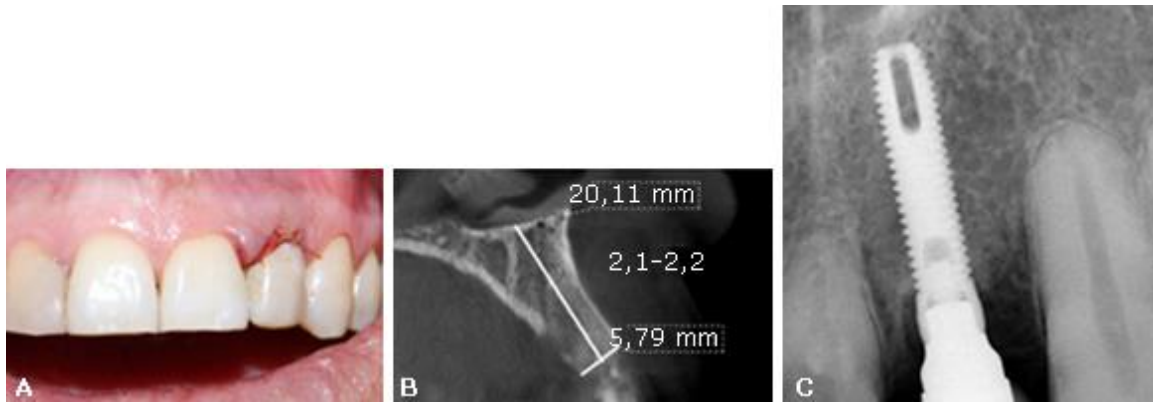
## CLINICAL REPORT

39-year-old male patient, without systemic disease, and completely dentate with no occlusal parafunction. The radiographic exam showed the presence of advanced palatal bone resorption (almost total loss of the palatal plate in all its extension (7 mm) secondary to a root fracture of the maxillary left lateral incisor and a large osteolytic area on the palatal aspect of the root (Fig.1, A). The patient's main complaint was aesthetic.



**Fig. 1** - A: Aspect of the root. B: Resorbable collagen membrane adapted to the bone defect. C: Retaining the bone allograft and closing the socket repair.

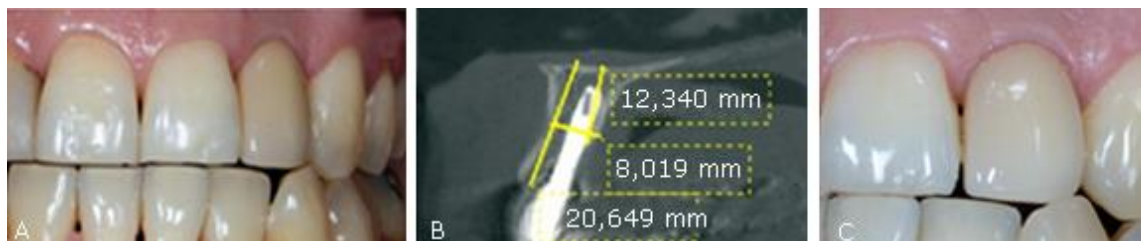In a first surgical phase, the patient was anesthetized with two tubes of mepivacaine 3 % (Scandicaine, Septodont). The lateral incisor was extracted using an atraumatic periosteal technique. Then, a resorbable collagen membrane (BioMend Extend, Zimmer Biomet Dental) (15 mm x 20 mm) was adapted to the bone defect and placed in a position to recreate the palatal plate (Fig. 1, B). After this, particulate cortical bone allograft (Puros Cortical Allograft Particulate, Zimmer Biomet Dental) (1 cc) was compacted into the site to fill the space that was previously occupied by the root of the tooth. The membrane was retained in position with three horizontal mattress sutures (Polysorb 4-0, Covidien) to the buccal free gingiva, retaining the bone allograft and closing the socket repair (Fig. 1, C). Finally, the temporary restoration was performed using the extracted natural tooth, which was adhesively bonded to the adjacent teeth (Fig. 2, A).



**Fig. 2** – A: Temporary restoration using the extracted natural tooth. B: Four months after grafting computed tomography (CT) scan showed an adequate height and width of the bone. C: Implant placed in the second surgical phase.

Four months after grafting the extraction site in preparation for dental implant placement, conventional radiology and computed tomography showed an adequate height and width of the bone (Fig. 2, B). In a second surgical phase, one implant was placed (Screw-Vent, Zimmer Biomet Dental) (3,3 x 16 mm) with an average surgical torque of 25 Ncm (Fig. 2, C). Then, an implant fixture mount was cut slightly above the tissue level and established the emergence profile by simply adding composite (flowable), until the desired contours were achieved. It is important to note that this step should be done extra-orally to prevent the contact of any debris with the surgical site. Subsequently, this custom healing cap was attached to the implant.

Six months after the implant placement, osseointegration was clinically confirmed and a provisional crown screwed on the implant was performed. After several stages, the final restoration with a zirconium dioxide abutment and a full ceramic crown was obtained and cemented (Fig. 3, A).



**Fig. 3** - A: Six months after the implant placement. B and C: Radiographic and clinical follow-up after two years.

Radiographic and clinical follow-up after two years showed a favorable evolution of the implant. No mechanical or biological complications were seen throughout this observation period. The buccal and palatal gingival margin are in a correct position and there was a vertical bone gain of approximately 2 mm. (Fig. 3, B and C).

## DISCUSSION

*Papaspyridakos et al.*<sup>(2)</sup> describe that the aesthetic rehabilitation of the anterior zone in patients who lose teeth prematurely continues to represent a huge and difficult challenge for implantology. This case report describes the resolution of an implant-supported rehabilitation with an unusual defect and its follow-up after 2 years.

In this case report, an anterior straight forceps and a periosteal elevator were used to remove the tooth and prevent trauma of the alveolar bone. This shows that minimally invasive extraction and grafting techniques satisfied the critical requirements needed for socket repair, as *Barone et al.*<sup>(1)</sup> research pointed.

In this case, a resorbable collagen membrane and bone allograft was adapted to the bone defect to recreate the palatal plate. Guided bone regeneration has proved to be a suitable and somehow predictable technique for promoting bone regeneration, as the case report of *Chaple and Baganet*,<sup>(4)</sup> where they repair a bone fenestration with this procedure in a vestibular defect site. The membrane *Biomend* enhanced the early osteoblast attachment reported in a study. Extraction sites in the aesthetic zone present an obvious restorative challenge. This single-stage approach preserves site morphology by protecting and supporting existing hard and soft tissues.

Clinical success appears to be attributable to several important features of the technique.<sup>(5)</sup>

In this case report, our results showed that the regeneration of the palatal plate was possible using particulate cortical bone allograft and a resorbable collagen membrane. *Sterio et al.*<sup>(6)</sup> has been reported that human mineralized bone in particulate form, preserve the site's bone bulk and volume in preparation for dental implants placement. Healing of defects packed with particles larger than 300 µm was slower than with 300-90 µm grafts. Fast healing of bone defects packed with particulate bone allografts in the range of 300 to 90 µm, indicates that such allografts can be used effectively in the filling of bone defects.<sup>(7)</sup> In this case, the particle size matches with the bone allograft recommendation. The advantages of using an allograft includes that the graft material is available without the need of a second surgical harvest site, and that the material is osteoconductive. A human case report conducted by *Elia et al.*,<sup>(3)</sup> reported that five months after grafting with mineralized human bone, osteocyte nuclei within lacunae in an osteoid matrix were found. This matrix was appositionally deposited against non-vital graft bone.

The combination of mineralized, freeze-dried, cortical allograft with a nonresorbable porous membrane has resulted in successful bone formation over an extraction site. When using a nonresorbable porous membrane, primary closure of the extraction site is mandatory. Current technique of *Attia et al.*<sup>(5)</sup> advocates the use of a fast-resorbing material to retain the graft and promote epithelialization over the graft. The graft can be covered with a collagen material that resorbs in less than seven days.

*Attia et al.*,<sup>(5)</sup> also set that there is insufficient reliable evidence to provide recommendations on which is the ideal flap design, the best soft tissue augmentation technique, the ideal technique to increase the width of keratinised/attached mucosa, and which are the best incision/suture techniques/materials.

Guide bone regeneration in a lateral maxillary incisor is difficult; its histological and anatomical characteristics complicate the clinical protocol. A recent study of *Papaspyridakos et al.*,<sup>(2)</sup> conducted with cone beam computed tomography technology, reported that spongy bone thickness in the maxillary lateral incisors is slightly smaller than in the central incisors and canine. In both, palatal and vestibular aspects, is important to consider anatomical situation for the regenerative process.

Despite the medium-term success of the treatment reported in this clinical case, is



important to emphasize that an adequate training and competences of the operator are necessary to achieve a successful outcome in similar cases. The process of guided bone regeneration is critical to subsequently achieve an optimal installation of the dental implant.

In the clinical follow-up performed after 2 years the rehabilitation is aesthetically pleasing, the buccal and palatal gingival margin are in a correct position and the interproximal papillae is in class I of Miller. According to the computerized axial tomography, in similar non-standardized cuts, there was a vertical bone gain of approximately 2 mm. *Rath et al.*<sup>(8)</sup> describe that this vertical gain is important to maintain the stability of the implant in the long term.

This case was performed in the context of a postgraduate program at local University, where patients are assured of institutional follow-up at a lower cost than in private practice. Follow-up and maintenance are also critical in the success of clinical situations similar to those reported.

The regeneration of the palatal plate was possible through the use of particulate cortical bone allograft and a resorbable collagen membrane adapted to the bone defect and placed in a position to recreate the palatal plate. This allowed the installation of an implant 4 months later the procedure. This technique allowed esthetics and functional results using a single fixed prosthesis.

## BIBLIOGRAPHIC REFERENCES

1. Barone A, Toti P, Piattelli A, Iezzi G, Derchi G, Covani U. Extraction socket healing in humans after ridge preservation techniques: comparison between flapless and flapped procedures in a randomized clinical trial. *J Periodontol.* 2014;85(1):14-23.
2. Papaspyridakos P, Tarnow DP, Eckert SE, Weber HP. Replacing Six Missing Adjacent Teeth in the Anterior Maxilla With Implant Prostheses: A Case Series. *Compend Contin Educ Dent.* 2018;39(6):e1-e4.
3. Elian N, Cho SC, Froum S, Smith RB, Tarnow DP. A simplified socket classification and repair technique. *Pract Proced Aesthet Dent.* 2007;19(2):99-104.
4. Chaple Gil AM, Baganet Cobas Y. Tratamiento integral de lesión endoperiodontal en molar con dehiscencia ósea. *Gaceta Dental.* 2016(276):142-7.
5. Attia MS, Mohammed HM, Attia MG, Hamid M, Shoeriabab EA. Histological and histomorphometric evaluation of hydroxyapatite-based biomaterials in surgically created



defects around implants in dogs. J Periodontol. 2018:[Epub ahead of print]. doi: 10.1002/JPER.17-0469.

6. Sterio TW, Katancik JA, Blanchard SB, Xenoudi P, Mealey BL. A prospective, multicenter study of bovine pericardium membrane with cancellous particulate allograft for localized alveolar ridge augmentation. Int J Periodontics Restorative Dent. 2013;33(4):499-507.

7. Le B, Borzabadi-Farahani A, Nielsen B. Treatment of Labial Soft Tissue Recession Around Dental Implants in the Esthetic Zone Using Guided Bone Regeneration With Mineralized Allograft: A Retrospective Clinical Case Series. J Oral Maxillofac Surg. 2016;74(8):1552-61.

8. Rath A, Varma S, Paul R. Two-Stage Mucogingival Surgery with Free Gingival Autograft and Biomend Membrane and Coronally Advanced Flap in Treatment of Class III Millers Recession. Case Rep Dent. 2016;2016:9289634.

Recibido: 2018/12/24

Aceptado: 2019/01/15

Publicado: 2019/08/29



Este artículo de **Revista Cubana de Estomatología** está bajo una licencia Creative Commons Atribución-No Comercial 4.0. Esta licencia permite el uso, distribución y reproducción del artículo en cualquier medio, siempre y cuando se otorgue el crédito correspondiente al autor del artículo y al medio en que se publica, en este caso, **Revista Cubana de Estomatología**.