







## CASE REPORT

# De-epithelialization technique as an esthetic treatment for gingival lichen planus

## Técnica de desepitelización como tratamiento estético para el liquen plano gingival

Marcelo Hissao Imano<sup>1</sup> , Luiza Foltran de Azevedo Koch<sup>2</sup> , Paula Porto Spada<sup>2</sup> , Marilisa Carneiro Leão Gabardo<sup>2</sup>  , Tatiana Miranda Deliberador<sup>2</sup> 

**ABSTRACT**

**Introduction:** Oral lichen planus is a chronic inflammatory disease affecting the mucosa.

**Objective:** To report a clinical case of oral lichen planus in gingiva whose removal was carried out by the de-epithelialization technique of the affected areas.

**Case report:** A 56-year-old female patient presented white plaques upon clinical examination that could not be removed by scraping. The treatment plan involved a biopsy and lesion removal by de-epithelialization, procedure not described in the literature up to date. This technique consisted of the removal of the plaques with the epithelial tissue from the gingiva using a 15c blade, leaving the connective tissue exposed. Clinical follow-up was performed at 3 and 10 days, and at 2, 3 and 15 months.

**Conclusions:** De-epithelialization was a resolute esthetic intervention for the case presented.

**Keywords:** Oral lichen planus; ambulatory surgical procedures; therapeutics; esthetics.

**RESUMEN**

**Introducción:** El liquen plano oral es una enfermedad inflamatoria crónica que afecta a la mucosa.

**Objetivo:** Reportar un caso clínico de liquen plano oral en encía cuya extirpación se realizó mediante la técnica de desepitelización de las áreas afectadas.

**Reporte de caso:** Una paciente de 56 años presentaba placas blancas en el examen clínico que no podían eliminarse con raspado. El plan de tratamiento consistió en una biopsia y extirpación de la lesión por desepitelización, procedimiento no descrito hasta la fecha en la literatura. Esta técnica consistió en la eliminación de las placas con el tejido epitelial de la encía utilizando una cuchilla de 15c, dejando expuesto el tejido conectivo. El seguimiento clínico se realizó a los 3 y 10 días, ya los 2, 3 y 15 meses.

**Conclusiones:** La desepitelización fue una intervención estética resolutiva para el caso presentado.

**Palabras clave:** liquen plano oral; procedimientos quirúrgicos ambulatorios; tratamiento; estética.

## INTRODUCTION

Oral lichen planus (OLP) is a chronic inflammatory disease affecting the oral mucosa with a variety of clinical presentations, including reticular, papular, plaque-like, atrophic, and ulcerative lesions.<sup>(1,2)</sup> Clinical, histological, immunological, immunohistochemical and genetic investigations have not identified the initial trigger and pathogenic pathway that leads to the formation of lesions.<sup>(3)</sup>

The pathogenesis is believed to involve a T-cell-mediated response. However, the mechanisms triggering the T-cells to enter the oral epithelium and to accumulate in the superficial lamina propria, as well the triggering mechanisms behind basal keratinocyte apoptosis, are not fully understood. Also, it may involve both, antigen-specific and non-specific mechanism.<sup>(4)</sup> Some general diseases, such as hypertension, diabetes, chronic liver disease and genetic predisposition have been associated with the etiology of the disease.<sup>(5)</sup> OLP is currently classified as a potentially malignant disorder, but there are still conflicting reports on this potential.<sup>(2,6,7)</sup>

OLP affects middle-aged and elderly, and is more prevalent in women.<sup>(3,4,8)</sup> The lesions are mostly bilateral and symmetrical, affecting predominantly the buccal mucosa, gingiva and tongue. It may appear isolated or associated with cutaneous lichen planus, the last develops by short-term outbreaks which usually respond well, and OLP tends to be chronic, relapsing and difficult to treat.<sup>(2)</sup>

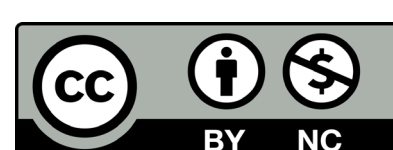
In symptomatic OLP, patients normally complain of a burning sensation or pain when eating or swallowing hot or spicy food that affects their quality of life.<sup>(5,9)</sup> High-potency topical steroids are considered to be effective drugs for palliative treating symptomatic OLP.<sup>(10,11)</sup> Because of the chronic nature, completely healing the lesions is very difficult.<sup>(1)</sup>

Thus, the aim of this manuscript is to report a clinical case of OLP in gingiva whose removal was carried out by the de-epithelialization technique of

Recibido: 28/05/2020  
Aceptado: 23/06/2020

<sup>1</sup>São Leopoldo Mandic. Curitiba, PR, Brazil.

<sup>2</sup>Universidade Positivo, School of Health Sciences. Curitiba, PR, Brazil.



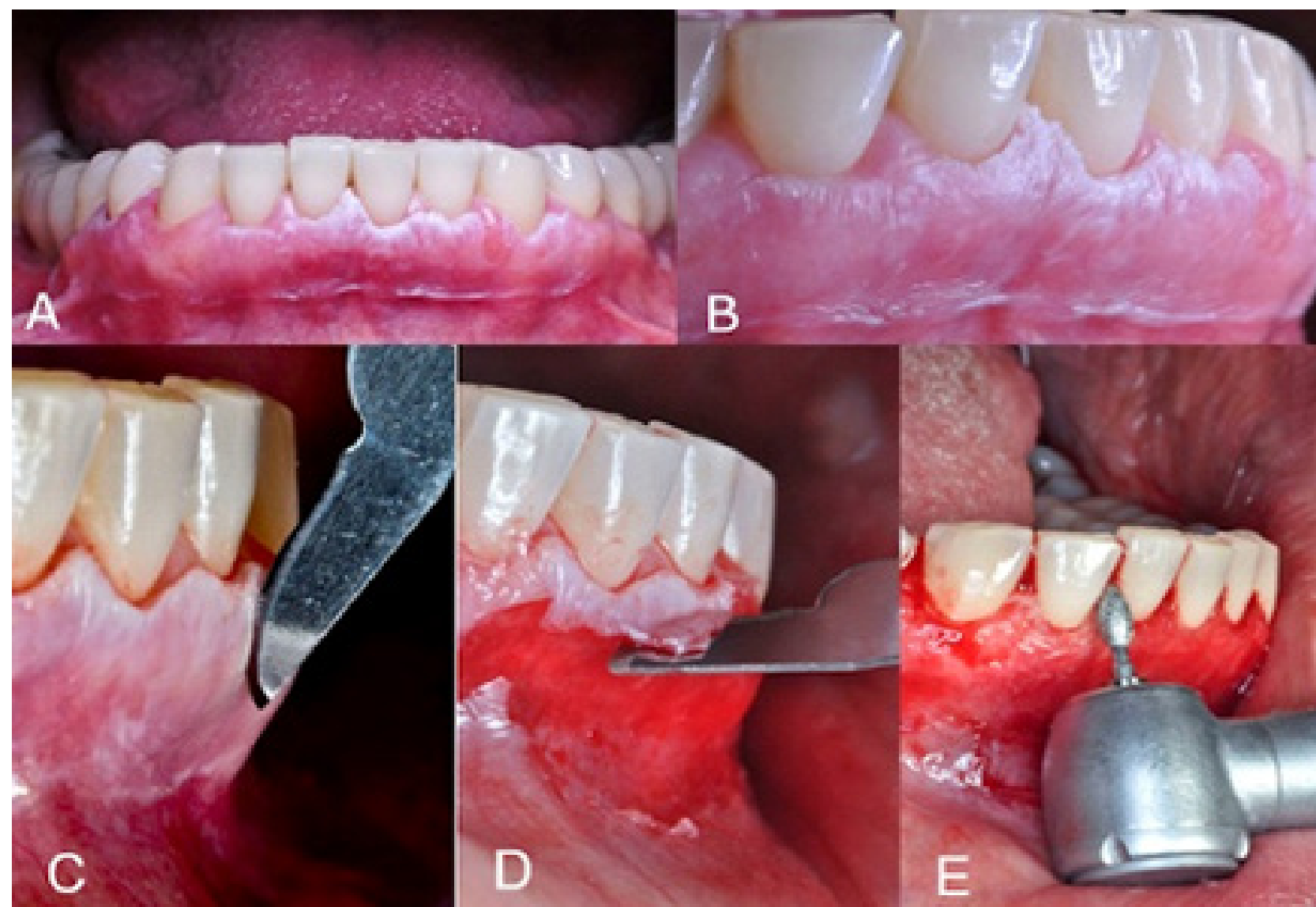


the affected areas.

## CASE REPORT

A female patient, 56 year-old, caucasian, presented to the clinic of a specialization in Periodontics, with the main complaint the "removal of a white spot on the jaw. The patient reported food accumulation in this region that made it uncomfortable.

At clinical examination, white plaques were not removed by scraping into the attached and papillary gingiva (Fig. 1). The diagnostic hypothesis was OLP. In addition, the patient had gingivitis. As a treatment plan, it was established that the same surgical procedure would be performed biopsy and removal of the white plaques, by the technique of de-epithelialization.<sup>(12)</sup>



**Fig. 1 - (A) White plaques in the region of attached gingiva. (B) Lateral view of gingiva. (C) Beginning of the process of removing white plaques. (D) Removal of epithelial tissue and connective tissue exposure. (E) Use of a flame shape diamond bur in high rotation.**

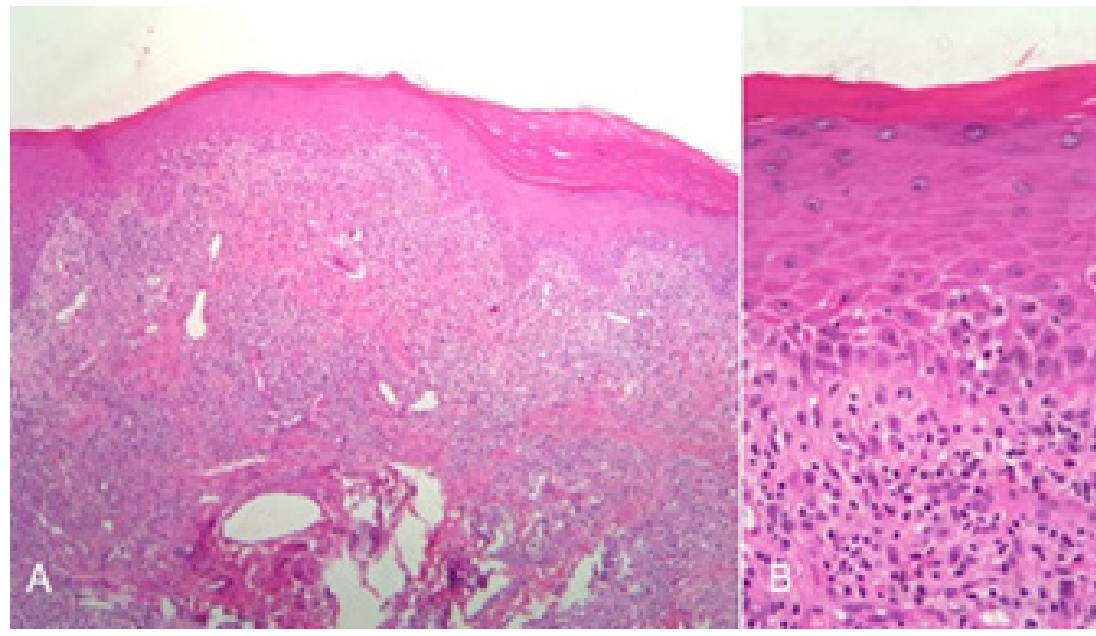
To perform the procedure, extra-buccal antiseptics with 2% chlorhexidine digluconate followed by intra-buccal antiseptics with 0.12% chlorhexidine digluconate. The infiltrative local anesthesia was performed from the mandibular second right premolar to the second left premolar with 2% mepivacaine with adrenaline 1:100.000 in a volume of approximately 1.8 ml. The technique consisted of removing the white plaques with a blade 15c along with the epithelial tissue from the gingiva, leaving the connective tissue exposed (Fig. 1C and 2D).

In the intrapapillary region, this process was performed with a flame shape diamond bur in high rotation (with constant and abundant irrigation with saline solution) (Fig. 1E).

This procedure does not require suturing. As post-operative medication prescribed was: amoxicillin 500 mg, every 8h for seven days, nimesulid 100 mg, every 12 h for five days, and paracetamol 750 mg, every 6 h for five days). After 24 h mouthwash was recommended every 12 h with 0.12% chlorhexidine digluconate.

The clinical follow-up of the patient was performed at three and 10 days, and then in two, three and 15 months. At the third postoperative day, a scar pattern was observed within the expected period with epithelization of the gingival tissue. After 10 days, the patient reported an improvement of the main complaint and improvement of esthetics.

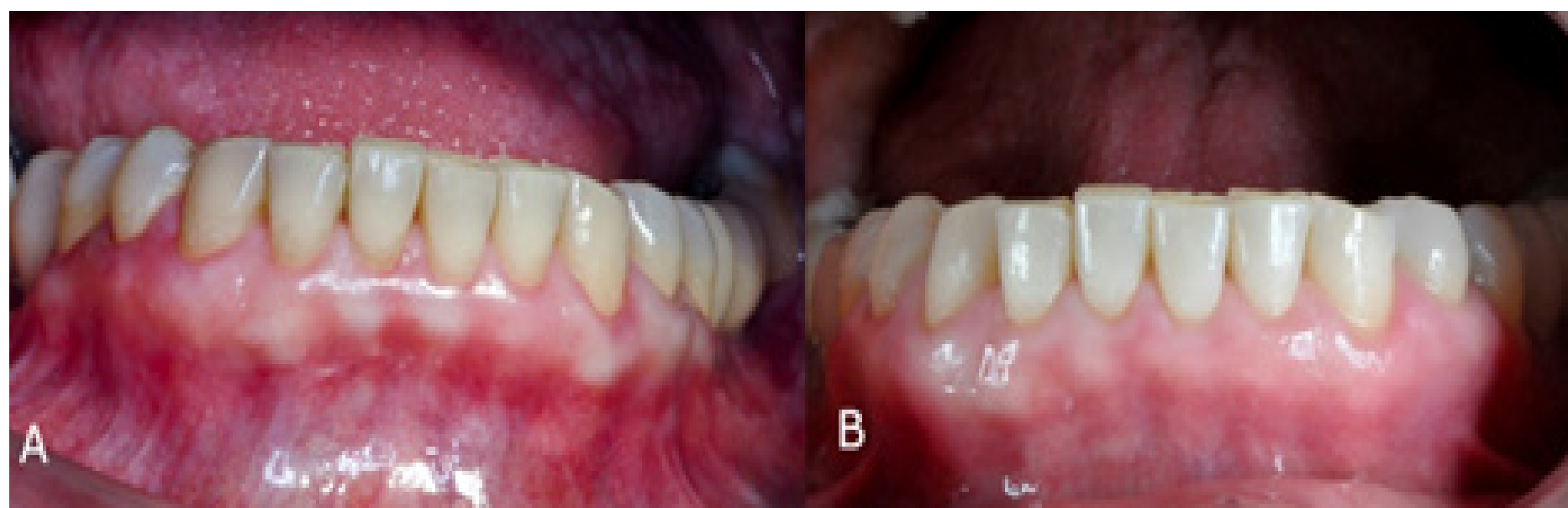
In the second month the condition was stabilized with no change in the color and texture of the gingival epithelium. Also, it was verified through pathological anatomical examination the diagnosis of lichen planus chronic lichenoid mucositis with thickened squamous epithelium, hyperkeratosis compact and without atypical. Presence of acute inflammatory infiltrated chronic with many plasma and outbreaks of fibrosis. The basal membrane shows normal pattern (Fig. 2).



**Fig. 2 - (A)** Histological aspect of the lesion removed. **(B)** Absence of cellular atypical and presence of inflammatory infiltrate.

After three months of follow-up, a new white plaque focus was observed. The option was to perform an excisional biopsy of the lesion and, again, the diagnosis found was OLP. After the last surgical procedure, the patient returned for follow-up (Fig. 3A).

Patient returned after 15 months to evaluate the clinical aspect. It was possible observe that until this moment there was no recurrence of the lesion (Fig. 3B).



**Fig. 3 - (A)** Gingival appearance after three months of follow-up. **(B)** Clinical aspect after 15 months of follow-up.

## DISCUSSION

OLP is a chronic inflammatory disease of difficult treatment, with persistent manifestations for years, alternating periods of quiescence and exacerbation.<sup>(2,13)</sup> It usually affects mouth, skin, nails, and may be involved with systemic diseases such as diabetes, hypertension and anxiety.<sup>(3)</sup> It presents several clinical forms including papule, reticular, plaque, atrophic, erosive and bullous, each one showing specific characteristics and appearing in either isolated or associated forms.<sup>(5)</sup>

In this case report the patient presented manifestations in the skin, scalp and buccal mucosa. The disease manifested in the oral cavity were white plaques involving attached and papillary gingiva, and also striae in the bilateral jugal mucosa.

The clinical form of white plaques and the striae usually do not present painful symptomatology<sup>(5)</sup> as in the present case, referred by the patient only as an aesthetic complaint. The patient stated that she was getting more embarrassed without smiling and being unable to socialize. She also complained that her hair was falling. A dermatologist also did a biopsy on the scalp and the diagnose was lichen planus.

The clinical aspect of patients affected by OLP with the erythematous and ulcerative type often suffer from severe oral mucosal pain, including burning and itching sensations, particularly in relation to the intake of spicy and acidic food, which may have a negative impact on oral functions as well as the patients' quality of life and wellbeing.<sup>(4,8)</sup>

The diagnosis of OLP is based on the clinical appearance of the lesions and is subsequently confirmed by histopathological study, mainly to exclude the presence of epithelial dysplasia or even signs of malignancy. Also, there are controversies regarding the potential of malignancy of the OLP.<sup>(2)</sup>

The biopsy and total surgical removal of the gingival lesions, using a de-epithelialization technique<sup>(12)</sup> were performed due to the aesthetic complaint and to rule out the possibility of cellular dysplasia. The surgical technique, here used, aimed to remove any affected epithelium and removal of melanocytic spots in patients



who present aesthetic complaints due to gingival staining.<sup>(12)</sup>

In the researched literature, one case of excision of OLP by removal of epithelium was found in Contin et al.,<sup>(14)</sup> which performed dermabrasion in the zygomatic region of a female patient followed by cosmetic protocol. There was an improvement in the clinical aspect, but after 12 months of follow-up, the melanocytic spots re-occurred. In the present case, after six months, the lesions returned to a lesser extent, but without aesthetic complaint. A new excisional biopsy was performed, again with diagnosis of OLP.

Even though there is no specific treatment for OLP, symptomatic treatment is indicated. Corticosteroids provide relief and are the first choice of drug.<sup>(3)</sup> In the case reported by Sharma et al.,<sup>(8)</sup> after surgical therapy for the control of gingival hyperplasia associated with erosive OLP, the authors indicated the topical use of corticosteroids with satisfactory results.

Due to the use of corticosteroids and the possibility of development of fungal lesions, some studies regarding the use of topical herbal medicines to control the lesions, such as curcumin and aloe vera, seem promising, but their effectiveness needs monitoring.<sup>(13)</sup> Nosratzahi<sup>(5)</sup> compared the use of corticoid with curcumin, showing the positive effects of the herbal product and no adverse reactions.

Despite the discussion about conservative treatments, the option in this case was the surgical intervention, with no prior medication attempt.

It was possible to observe that the clinical aspect of the gingiva after 15 months was satisfactory, but a long-term follow-up is necessary to be evaluated the conditions and to be analyzed a possible recurrence of the lesion. New therapies may be used in the patient if the lesion returns.

In conclusion, the technique de-epithelialization was resolute from the aesthetic in this case. However, researches and new clinical cases must be carried out in order to achieve the use of this treatment.

## REFERENCES

- Lodi G, Scully C, Carrozzo M, Griffiths M, Sugerman PB, Thongprasom K. Current controversies in oral lichen planus: Report of an international consensus meeting. Part 2. Clinical management and malignant transformation. *Oral Surg Oral Med Oral Pathol Oral Radiol Endod.* 2005;100(2):164-78.
- Ismail SB, Kumar SKS, Zain RB. Oral lichen planus and lichenoid reactions: etiopathogenesis, diagnosis, management and malignant transformation. *J Oral Sci.* 2007;49(2):89-106.
- Krupaa RJ, Sankari SL, Masthan KMK, Rajesh E. Oral lichen planus: An overview. *J Pharm Bioallied Sci.* 2015;7(Suppl 1):S158-61.
- Larsen KR, Johansen JD, Reibel J, Zachariae C, Rosing K, Pedersen AML. Oral symptoms and salivary findings in oral lichen planus, oral lichenoid lesions and stomatitis. *BMC Oral Health.* 2017;17(1):103.
- Nosratzahi T. Oral lichen planus: an overview of potential risk factors, biomarkers and treatments. *Asian Pac J Cancer Prev.* 2018;19(5):1161-7.
- Aguirre-Urizar JM, Alberdi-Navarro J, Lafuente-Ibáñez de Mendoza I, Marichalar-Mendia X, Martínez-Revilla B, Parra-Pérez C, Juan-Galíndez A-D, et al. Clinicopathological and prognostic characterization of oral lichenoid disease and its main subtypes: A series of 384 cases. *Med Oral Patol Oral Cir Bucal.* 2020;25(4):554-e562. PMID: 32388519
- Kaomongkolgit R, Daroonpan P, Tantanapornkul W, Palasuk J. Clinical profile of 102 patients with oral lichen planus in Thailand. *J Clin Exp Dent.* 2019;11(7):e625-e629.
- Sharma A, Aggarwal C, Mathur VP, Sardana D. Severe gingival enlargement with coexisting erosive lichen planus in severe chronic periodontitis patient. *Case Rep Dent.* 2015;2015:538538. DOI: [10.1155/2015/538538](https://doi.org/10.1155/2015/538538)
- Wiriyakijja P, Porter S, Fedele S, Hodgson T, McMillan R, Shephard M, et al. Meaningful improvement thresholds in measures of pain and quality of life in oral lichen planus. *Oral Dis.* 2020;26(7):1464-73. DOI: [10.1111/odi.13379](https://doi.org/10.1111/odi.13379)
- Thongprasom K, Dhanuthai K. Steroids in the treatment of lichen planus: a review. *J Oral Sci.* 2008;50(4):377-85.
- Moritani NH, Hara ES, Kubota S. New functions of classical compounds against orofacial inflammatory lesions. *Medicines (Basel).* 2018;5(4):118.
- Chethana K, Pradeep K. Scalpel depigmentation and surgical crown lengthening to improve anterior gingival esthetics. *Ann Med Health Sci Res.* 2016;6(6):385-8.
- Thongprasom K. Oral lichen planus: Challenge and management. *Oral Dis.* 2018;24(1-2):172-3.
- Contin LA, Costa DM, Bet DL, Moura LB, Michalany AO, Di Chiacchio N. Líquen plano pigmentoso: tratamento cirúrgico com dermoabrasão. [Lichen planus pigmentosus: surgical treatment with dermabrasion] *Surg Cosmet. Dermatol.* 2014;6(4):384-6.

## CONFLICT OF INTEREST

There are no conflicts of interest.

## AUTHOR'S CONTRIBUTIONS

Marcelo Hissao Imano: performed de clinical case.

Luiza Foltran de Azevedo Koch: contributed to drafting of manuscript.

Paula Porto Spada: contributed to case description and follow-up.

Marilisa Carneiro Leão Gabardo: contributed to critical revision.

Tatiana Miranda Deliberador: contributed study conception and design.

