

Diagnostic yield and therapeutic impact of fine-needle aspiration biopsies guided by endoscopic ultrasound in pancreatic lesions

Miguel Ángel Ramírez-Luna,* Sergio Zepeda-Gómez,* Norberto C. Chávez-Tapia,** Félix I. Téllez-Ávila**

*Endoscopy and **Gastroenterology Departments.
Instituto Nacional de Ciencias Médicas y Nutrición Salvador Zubirán.

ABSTRACT

Background and aim. The correct approach and treatment in a patient with a pancreatic lesion detected by imaging is not easy. Recently, the endoscopic ultrasound-guided fine-needle aspiration (EUS-FNA) biopsy is becoming a useful tool. The aim of the study is to evaluate the diagnostic yield and therapeutic impact of EUS-FNA in pancreatic lesions. **Methods.** Fifty-three patients with focal pancreatic lesions underwent EUS-FNA from March 2005 to March 2006. The final diagnosis was confirmed by the histological analysis from the surgical specimen and/or clinical follow-up for at least 6 months. **Results.** Fifty-two patients were evaluated. Forty-seven useful samples for histological evaluation were obtained. Adequate samples were obtained in 83.3% (5/6) for lesions < 20 mm, 100% (19/19) for lesions from 20 to < 40 mm and 85.1% (23/27) for those \geq 40 mm. To differentiate between benign/malignant disease the sensitivity, specificity, positive predictive value, negative predictive value and diagnostic accuracy of EUS-FNA were 97.3% (95%CI: 84.9-99.1), 100% (95%CI: 66-100), 100% (95%CI: 88-100), 90% (95%CI: 57-96) and 97.8%, respectively. There was a change in the initial diagnosis in seven patients (14.8%). No complications were reported. **Conclusions.** EUS-FNA is a useful and safe method with high predictive values to differentiate between malignant and benign pancreatic lesions.

Key words. Endoscopic ultrasound. Fine-needle aspiration biopsy. Pancreatic cancer. Predictive values.

Rendimiento diagnóstico e impacto terapéutico de las biopsias por aspiración guiadas por ultrasonido endoscópico en lesiones pancreáticas

RESUMEN

Antecedentes y objetivo. La decisión de qué conducta tomar ante una lesión pancreática detectada por estudios de imagen en ocasiones no es fácil. Recientemente, las biopsias obtenidas por aspiración con aguja fina guiada por ultrasonido endoscópico (BAAF-USE) han mostrado tener un adecuado rendimiento diagnóstico. El objetivo de este estudio fue evaluar el rendimiento diagnóstico e impacto terapéutico de las BAAF-USE. **Pacientes y métodos.** 53 pacientes con lesiones pancreáticas focales fueron sometidos a BAAF-USE en el periodo de marzo/2005 a marzo/2006. El diagnóstico definitivo (ideal estándar) fue realizado con base al resultado histopatológico de las muestras quirúrgicas y/o el seguimiento clínico por al menos 6 meses. **Resultados.** 52 pacientes fueron evaluados, en 47 se obtuvieron muestras de tejido útiles para evaluación histopatológica. La proporción de muestras adecuadas, de acuerdo al tamaño de la lesión fue: 5/6 (83.3%) en las lesiones < 20 mm, 19/19 (100%) para las lesiones de 20 a < 40 mm y en 23/27 (85.1%) en las lesiones \geq 40 mm. Al correlacionar el resultado definitivo de las muestras obtenidas por BAAF-USE con el resultado del ideal estándar para distinguir entre lesiones benignas y malignas, la sensibilidad, especificidad, valor predictivo positivo, valor predictivo negativo y exactitud diagnóstica fueron 97.3% (IC95%: 84.9-99.1), 100% (IC95%: 66-100), 100% (IC95%: 88-100), 90% (IC95%: 57-96) y 97.8%, respectivamente. En siete pacientes (14.8%) hubo un cambio en el diagnóstico inicial obtenido por otros métodos de imagen. No existieron complicaciones. **Conclusión.** La BAAF-USE es un método útil y seguro para la evaluación de lesiones pancreáticas que permite una adecuada diferenciación de lesiones benignas y malignas.

Palabras clave. Ultrasonido endoscópico. Biopsia por aspiración. Cáncer pancreático. Valores predictivos.

INTRODUCTION

Endoscopic Ultrasound (EUS) has been a useful method to evaluate pancreatobiliary pathology for more than a decade.¹ Recently, the availability for obtaining histological samples by endoscopic ultrasound-guided fine-needle aspiration biopsies (EUS-FNA) or Tru-Cut biopsies has allowed a better care of patients with cystic or solid pancreatic lesions.² EUS is currently the method with better sensitivity for the evaluation of pancreatic lesions smaller than 2 cm of diameter.² The studies that evaluate the diagnostic yield of EUS-FNA for pancreatic lesions have shown high sensitivity, specificity and predictive values ranging from 80 to 100%.³⁻⁶ However, EUS and EUS-FNA are invasive methods that require a trained and experienced endoscopist.

The aim of this study is to evaluate the diagnostic yield and therapeutic impact of EUS-FNA on pancreatic lesions.

METHODS

We reviewed in a retrospectively manner the electronic and paper records of patients with clinical, biochemical and/or radiological suspicion (Ultrasound, CT, MRI) of a pancreatic lesion that underwent EUS in the Instituto Nacional de Ciencias Médicas y Nutrición "Salvador Zubirán" from March 2005 to March 2006. There were 83 procedures in total. Four patients were excluded because incomplete data in the paper/electronic database. Biopsy was not performed in 13 patients because no lesion was found in EUS and in other 13 because it was considered that the result would not change the further management of the patients. Before each procedure, complete blood count, INR, and prothrombin time were obtained for all patients to minimize the risk of bleeding. An experienced endoscopist in EUS (MARL) performed the EUS-FNA in all cases. Written informed consent was obtained for each patient and the procedures were performed under deep sedation with midazolam, propofol and phentanyl by an anesthetist. It was used a linear GF UCT-140 echoendoscope (Olympus) with an Aloka console SSD 5500. It was used an 8 cm long ECHO TIP needle 22 or 19 gauge (Wilson-Cook) for the FNA. The tissue samples obtained by EUS-FNA were sent for histological and cytological evaluation. A pathologist was not available in endoscopy room. The final diagnosis (gold standard) was made in each patient based on the results from the surgical specimen and/or the

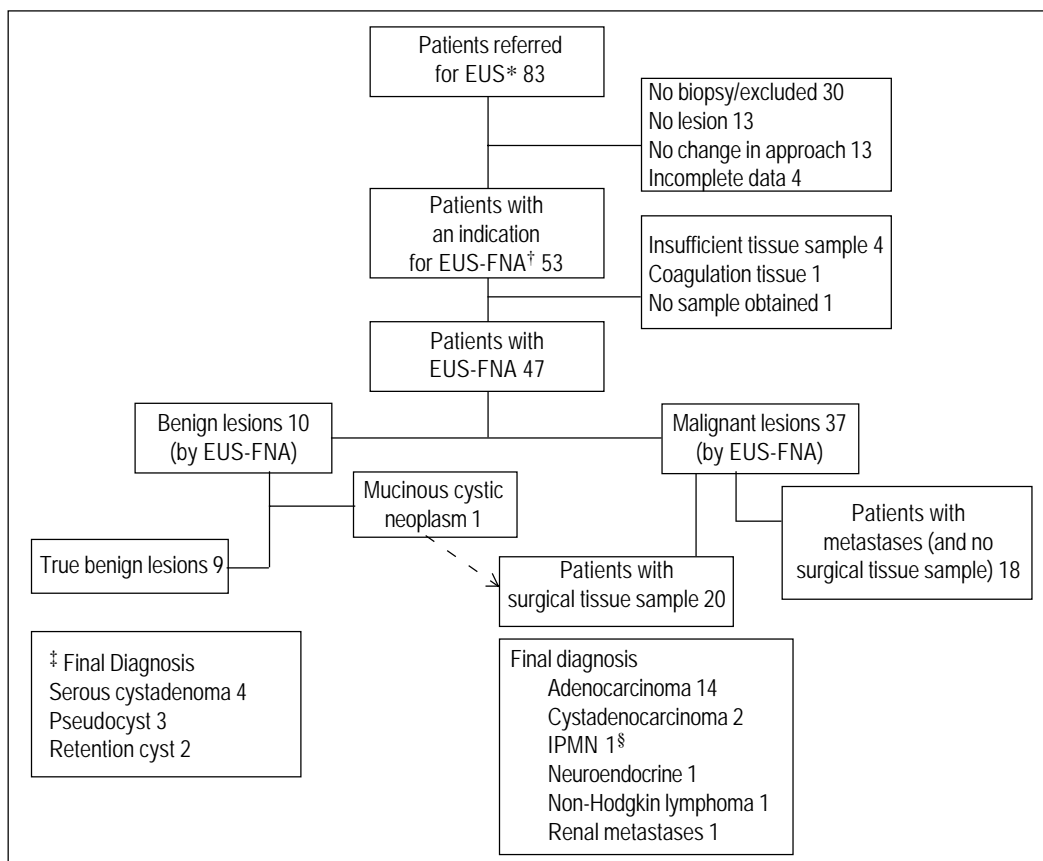
clinical follow-up for at least 6 months. The patients that were diagnosed with pancreatic cancer with the results from the EUS-FNA (besides of CT and/or MRI) and with confirmed metastases to distant organs (18/37) were not undergone to surgery and they have been treated with chemotherapy and/or palliative measures. In patients that underwent surgery, the diagnosis of malignant tumor was confirmed. All patients were hospitalized after the procedure for at least 4 hours for surveillance of possible complications. The diagnostic usefulness of EUS-FNA was evaluated in terms of sensitivity, specificity and predictive values.

RESULTS

Tissue samples were obtained in 52 patients of 53 who underwent EUS-FNA (98.1%) as shown in figure 1. Characteristics of the patients are shown in table 1. The size of the lesions of the 53 patients ranged from 11 mm to 120 mm with a median of 32.5 mm. Adequate tissue samples were obtained for histological evaluation in 47 patients (90.3%). The characteristics of the pancreatic lesions (location, size and type) are described in table 2. According with lesion size, successful sampling was obtained in 83.3% (5/6) for lesions ≤ 20 mm, 100% (19/19) for lesions from 21 to 39 mm and 85.1% (23/27) for those ≥ 40 mm. Inadequate tissue samples were reported in five patients, the pathology report was consistent with insufficient material in four patients and coagulation tissue in one patient.

To differentiate between benign/malignant disease the calculated sensitivity, specificity, positive predictive value, negative predictive value and diagnostic accuracy of EUS-FNA were 97.3% (95%CI: 84.9-99.1), 100% (95%CI: 66-100), 100% (95%CI: 88-100), 90% (95%CI: 57-96) and 97.8%, respectively. The data for the analysis is shown in table 3.

The only false negative result was also reported as benign in the imaging studies (CT scan), malignancy was diagnosed by histological analysis of surgical specimen. In the group of 13 patients with none pancreatic lesion founded by EUS, all of them have had a benign clinical course with a follow-up of more than 6 months (interval of 6 to 16 months). The patients with metastatic pancreatic cancer diagnosed by EUS-FNA, CT and/or MRI (18/37) were managed with palliative care. Twenty patients underwent surgery (the remaining 19 plus one patient with a false negative by EUS-FNA), malignancy was confirmed in all of them (Figure 1).



* Endoscopic Ultrasound.
† Endoscopic ultrasound-guided fine-needle aspiration.
‡ In these patients the final diagnosis was made based in clinical follow-up, laboratory results and radiologic studies (CT and MRI).
§ Intraductal papillary mucinous neoplasm.

Figure 1. Referred patients for EUS-FNA and final (including histological) diagnosis.

Table 1. Characteristics of the patients with EUS-FNA. Number of patients 79, with biopsy 52. The number (%) of female were 44 (56).

Variable	Median	(Range)
Age, yr	61	(17-87)
Size of lesion, mean cm (range)	3.2	(1.1-12)
Total bilirubin (mg/dL)	1.19	(0.16-37.7)
Direct bilirubin (mg/dL)	0.42	(0.05-23)
ALP (IU/L)	138	(47-1086)
ALT (IU/L)	36	(10-437)
AST (IU/L)	42	(13-469)
Albumin (g/dL)	2.87	(1.23-4.3)
CA 19-9 (IU/L)	1509	(0.8-36963)

In our study, seven patients had a change in the initial diagnosis after the EUS-FNA was performed, which was confirmed by gold standard. In three patients the EUS-FNA identified a malignant lesion which previously were diagnosed as benign, and in four patients benign lesions were identified which previously were diagnosed as malignant. There were no complications associated to the EUS-FNA in our study.

Table 2. Characteristics of the pancreatic lesions in which histological samples were obtained by EUS-FNA.

Type of Pancreatic Lesion	Cystic	Solid	Total
Location			
Head	8	32	40
Body	4	3	7
Tail	1	4	5
Total	13	39	52
Size of lesion			
≤ 20 mm	2	1	3
21-39 mm	6	12	18
≥ 40 mm	5	26	31
Total	13	39	52

Table 3. Agreement of histological diagnosis between tissue samples obtained from EUS-FNA and gold standard.

Histologic diagnosis of tissue sample obtained from EUS-FNA	Final diagnosis		
	Malignant	Benign	Total
Malignant	37	0	37
Benign	1	9	10
Total	38	9	47

DISCUSSION

In this study we observed that EUS-FNA has a high diagnostic yield and clinical utility (considering the predictive values) in pancreatic lesions, with a low complication rate. To our knowledge, this study represents the first report of the experience with EUS-FNA in pancreatic lesions in Latin America, regardless limitations in economic support (a few number of technicians, absence of pathologist in endoscopy room, and insufficient equipment), it has been a useful technique.

The high predictive values of EUS-FNA may suggest that: 1) patients with benign results could receive conservative management only, and 2) patients with malignant results who are candidates to palliative surgical treatment intraoperative biopsies could be avoided. These results are consistent with findings of Eloubeidi, *et al.*⁷

EUS has been shown to be useful in the diagnosis of pancreatic diseases, even more with the possibility to obtain FNA. Recently, Mitsuhashi, *et al.*⁸ reported similar results to our study, with a sensitivity of 94.6%, specificity of 100%, positive predictive value of 100%, negative predictive value of 82% and a global precision of 95.6%. Although the clinical usefulness of this diagnostic method has been shown in this and in similar series,⁷⁻⁹ false negative results have been reported, but we believe these can be avoid with an adequate communication between radiologists, clinicians and endoscopists.⁸ An inadequate sample for diagnosis is an issue reported in other studies.¹⁻³ The presence of a pathologist in the procedure room to evaluate the quantity of tissue obtained, it is a measure to solve this matter.

An interesting issue is that most of inadequate samples belong to patients with large tumors (more than 4 cm of diameter), maybe this is related to a major amount of necrosis in this type of lesions. Although in our study there were no complications, the reported rate of pancreatitis after biopsies is about 2%.¹⁰ The risk of dissemination is also reduced with EUS when taking pancreatic biopsies, Micames, *et al.*¹¹ showed that patients with percutaneous biopsies had peritoneal carcinomatosis in 16.3% in comparison with 2.2% in the group of EUS biopsies ($p < 0.025$).

Limitations in our study is that the information was collected in a retrospective manner and some data like the number of attempts to obtain biopsies and a strict follow-up for the possible complications could not be evaluated properly. The medium-size sample could be considered.

In summary, the EUS-FNA for the evaluation of pancreatic lesions is a useful and safe method in our medium. In patients with malignant results who are candidates to palliative surgical treatment intraoperative biopsies could be avoided. However, at this time, prospective studies are necessary to corroborate these results and intraoperative biopsies in patients with suspicion of pancreatic cancer is recommended.

REFERENCES

1. Vilman P, Jacobsen GK, Henriksen FW, Hancke S. Endoscopic ultrasonography with guided fine needle aspiration biopsy in pancreatic disease. *Gastrointest Endosc* 1992; 38(2): 172-3.
2. Buscail L, Faure P, Bournet B, Selves J, Escourrou J. Interventional endoscopic ultrasound in pancreatic diseases. *Pancreatology* 2006; 6(1-2): 7-16.
3. Wiersema MJ. Accuracy of endoscopic ultrasound in diagnosing and staging pancreatic carcinoma. *Pancreatology* 2001; 1: 625-32.
4. Levy MJ, Jondal ML, Clain J, Wiersema MJ. Preliminary experience with an EUS-guided trucut biopsy needle compared with EUS-guided FNA. *Gastrointest Endosc* 2003; 57: 101-06.
5. Eloubeidi MA, Jhala D, Chheng DC, Chen VK, Eltoun I, Vickers S, Mel Wilcox C, Jhala N. Yield of endoscopic ultrasound-guided fine needle aspiration biopsy in patients with suspected pancreatic carcinoma. *Cancer* 2003; 99: 285-92.
6. Voss M, Hammel P, Molas G, Palazzo L, Dancour A, O'Toole D, et al. Value of endoscopic ultrasound guided fine needle aspiration biopsy in the diagnosis of solid pancreatic masses. *Gut* 2000; 46: 244-9.
7. Eloubeidi MA, Varadarajulu S, Desai S, Shirley R, Heslin MJ, et al. A Prospective Evaluation of an Algorithm Incorporating Routine Preoperative Endoscopic Ultrasound-Guided Fine Needle Aspiration in Suspected Pancreatic Cancer. *J Gastrointest Surg* 2007; 11(7): 813-9.
8. Mitsuhashi T, Ghafari S, Chang CY, Gu M. Endoscopic ultrasound-guided fine needle aspiration of the pancreas: cytomorphological evaluation with emphasis on adequacy assessment, diagnostic criteria and contamination from the gastrointestinal tract. *Cytopathology* 2006; 17: 34-41.
9. Ryoza S, Kitoh H, Gondo T, Urayama N, Yamashita H, Ozawa H, Yanai H, Okita K. Usefulness of endoscopic ultrasound-guided fine-needle aspiration biopsy for the diagnosis of pancreatic cancer. *J Gastroenterol* 2005; 40: 907-11.
10. Frossard JL, Amouyal P, Amouyal G, Palazzo L, Amaris J, Soldan M, et al. Performance of endosonography-guided fine needle aspiration and biopsy in the diagnosis of pancreatic cystic lesions. *Am J Gastroenterol* 2003; 98: 1516-24.
11. Micames C, Jowell PS, White R, Paulson E, Nelson R, Morse M, et al. Lower frequency of peritoneal carcinomatosis in patients with pancreatic cancer diagnosed by EUS-guided FNA vs. percutaneous FNA. *Gastrointest Endosc* 2003; 58: 690-5.

Correspondence and reprint request:

Miguel A. Ramírez-Luna, MD.
Departament of Gastroenterology
Instituto Nacional de Ciencias Médicas y Nutrición
Salvador Zubirán
Vasco de Quiroga 15. Tlalpan
Col. Sección XVI.
14080 Mexico City.
Phone: 5487-0900, ext. 2715
E-mail: mangelramirez@yahoo.com

Recibido el 10 de julio del 2007.
Aceptado el 9 de octubre del 2007.