

# Right and left partial iatrogenic injuries of the biliary tree. Therapeutic options

Miguel Ángel Mercado,\* Ismael Domínguez,\*  
Juan Carlos Arriola,\* Fernando Ramirez-Del Val,\* Miguel Urencio,\* Norberto Sánchez-Fernández\*

\* Departamento de Cirugía, Instituto Nacional de Ciencias Médicas y Nutrición Salvador Zubirán.

## ABSTRACT

**Background.** Bile duct injuries (BDI) have a wide array of presentation. Left partial injuries (Strasberg D) of the hepatic duct are the result of excessive traction, which dissects the hepatic hilum and provokes medial perforations without continuity loss. Right partial injuries (Strasberg A, B and C) are produced by direct damage to the hepatic duct or isolated injury to the right and accessory ducts. It is important to determine frequency, spectrum and treatment outcome of this BDI in the surgical scenario. **Methods.** Patients with BDI who underwent surgical treatment in our hospital were reviewed, right and left partial injuries were selected. Demographic, clinical and therapeutic data were analyzed. **Results.** In a 16-year period, 405 patients underwent surgical treatment of BDI. 31 (8%) were classified as a left partial injury (Strasberg D): 23 injuries at the common hepatic duct treated with a Hepatojejunostomy (HJ); four at the confluence level which received a HJ with neoconfluence construction; two partial injuries in the left hepatic duct underwent a selective left HJ; and two complete occlusions of the left hepatic duct, one treated with a partial hepatectomy and the last case underwent a partial HJ. Right partial injuries (Strasberg A, B or C) were identified in 21 cases (5%), their treatment was tailored according to the type of BDI (conservative, selective HJ, or hepatectomy). **Conclusions.** In our series the frequency of left and right partial BDI injuries was 8% and 5%, respectively. The spectrum of analyzed injuries included four subtypes for the left partial and eight for the right partial lesions. Most BDI in the two analyzed groups presented concomitant devascularization of the extra-hepatic ducts, therefore receiving surgical treatment rather than endoscopic treatment was done.

**Key words.** Biliary injury. Hepatojejunostomy. Roux en Y. Bile duct injuries.

## Opciones terapéuticas en lesiones laterales iatrogénicas de la vía biliar

### RESUMEN

**Introducción.** Las lesiones de las vías biliares (BDI) tienen una amplia gama de presentación. Las lesiones parciales izquierdas (Strasberg D) del conducto hepático son el resultado de una tracción excesiva, que disecciona el hilio hepático y provoca perforaciones mediales sin pérdida de continuidad. Las lesiones parciales derechas (Strasberg A, B y C) son producidas por el daño directo al conducto hepático o lesión de conductos accesorios. El objetivo de este estudio es determinar la frecuencia, espectro y los resultados del tratamiento quirúrgico. **Métodos.** Se analizaron variables clínicas, demográficas y terapéuticas en pacientes con lesión de vía biliar tratados quirúrgicamente en nuestro hospital en quienes se demostró lesión parcial. **Resultados.** En un periodo de 16 años, 405 pacientes fueron tratados quirúrgicamente por lesión iatrogénica de vía biliar. Se encontraron 31 casos (8%) con lesión parcial izquierda (Strasberg D): 23 lesiones en el conducto hepático común tratados con hepatoyeyuno anastomosis, cuatro a nivel de confluencia tratados con neoconfluencia y hepatoyeyunoanastomosis, dos lesiones parciales en el conducto hepático izquierdo tratados con hepatoyeyunostomía izquierda selectiva y dos oclusiones completas del conducto hepático izquierdo manejados con una hepatectomía parcial y hepatoyeyunoanastomosis selectiva izquierda respectivamente. Dentro de las lesiones parciales derechas (Strasberg A, B, y C) se identificaron 21 casos (5%) y su manejo fue de acuerdo al tipo de lesión ya sea conservador, hepatoyeyunoanastomosis selectiva derecha o hepatectomía parcial. **Conclusiones.** En nuestra serie la frecuencia de lesiones izquierdas y derechas parciales fue del 8 y 5%, respectivamente. El espectro de las lesiones analizadas tiene cuatro subtipos para las lesiones parciales izquierdas y ocho para las parciales derechas. La mayoría de las lesiones en los dos grupos presentaron devascularización concomitante de conductos extrahepáticos lo cual las convierte en lesiones complejas que requieren reconstrucción.

**Palabras clave.** Lesión iatrogénica de la vía biliar.

## INTRODUCTION

Iatrogenic bile duct injuries (BDI) may occur after gallbladder, pancreas and gastric surgery; laparoscopic cholecystectomy is responsible for 80 to 85% of them.<sup>1-3</sup> Although not statistically significant, BDI during laparoscopic cholecystectomy is twice more frequent compared to injuries during the open procedure (0.3% open vs. 0.6% laparoscopic).<sup>4</sup> BDI are a complex health problem, and although they usually occur in healthy young people, the effect on the patient's quality of life and overall survival is substantial.<sup>5</sup>

Despite their wide range of presentation, most of them fit into one of the existing classifications, however the individual characteristics of each injury, makes them unique. In addition, the acute process associated with the injury at the time of diagnosis and the presence of concomitant hepatic illness are important factors which have a significant impact on the patients outcome. A multidisciplinary approach (endoscopic, radiologic, medical and surgical) is necessary to achieve an adequate workup and optimal treatment.<sup>6-8</sup>

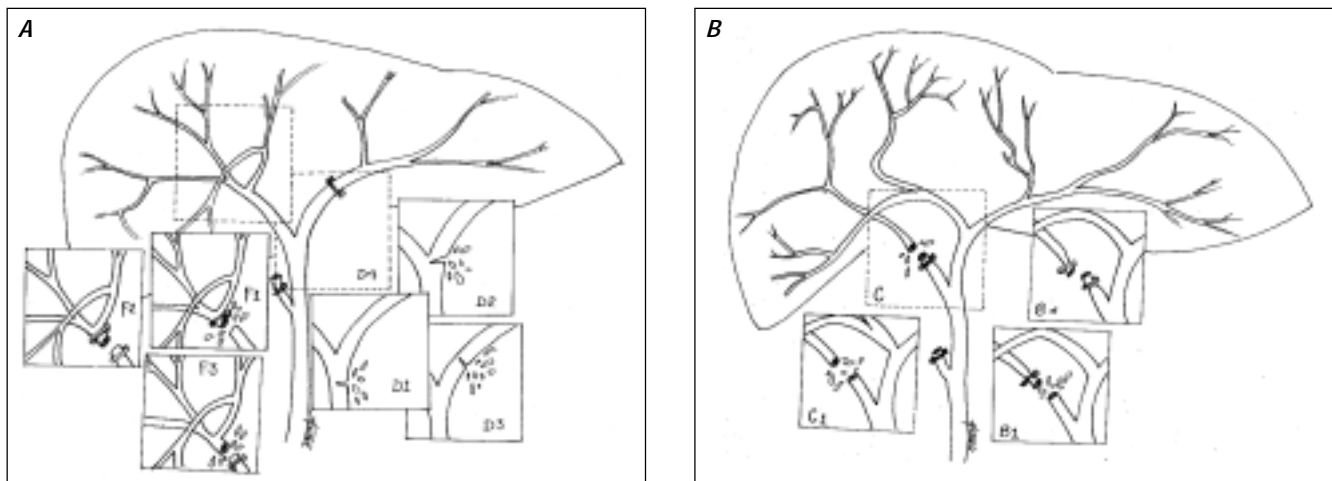
As we analyze the spectrum of BDI, the different injury mechanisms play an important role in the anatomical structures involved and the final result. Complex BDI (Strasberg E), present a total obstruction, ablation or section of the common bile duct or hepatic duct. Partial injuries of the biliary tree are due to direct trauma (thermal or mechanical) over the main or aberrant bile ducts (BD) producing incomplete injuries while maintaining continuity of the overall structure.

Strasberg et al developed a very complete classification for BDI<sup>9</sup> (Figure 1). For the purpose of this manuscript, we will interpret this classification as follows: right partial injuries (RPI) (Strasberg A, B and C), left partial injuries (LPI) (Strasberg D) and complex or circumferential injuries (Strasberg E). Left partial injuries (Strasberg D) occur almost exclusively during laparoscopic cholecystectomies. Excessive traction on Hartmann's bag and the cystic duct, results in an incomplete lateral injury to a major bile duct. Another mechanism for Strasberg D injuries is extensive thermal cautery exposure. These have considerable variations in therapeutic options depending on their individual characteristics.<sup>10</sup>

Both partial and complete right injuries (Strasberg A, B and C) occur in the right hepatic duct, aberrant anterior, posterior right hepatic ducts or in an accessory duct. We will further analyze the clinical characteristics of the right partial injury on the major BD, its presentation and therapeutic options.

## METHODS

Using our institution's database, a tertiary level university hospital, a systematic analysis of patient charts with BDI was made. Included charts dated from 1990 to 2006, from the general cohort of patients, those with right or left partial injuries that underwent surgical repair were selected. Patients who received definitive endoscopic treatment were excluded. The general data from the presenting signs, symptoms, diagnostic tools, diverse therapeutic



**Figure 1. A.** Right and left partial bile duct injuries. Right: F 4/21 cases (19%), F1 2/21 cases (9%), F2 1/21 cases (4%), F3 2/21 cases (9%). Left: D1 23/31 cases (74%), D2 4/31 cases (12%), D3 2/31 cases (6%), D4 2/31 cases (6%). **B.** Right partial bile duct injuries. C 5/21 cases (23%), C1 4/21 cases (19%), B 1/21 cases (4%), B1 2/21 cases (9%).

options employed were recorded. In addition, cholangitis and surgical or radiological interventions were also included in order to determine long term postoperative outcomes. A favorable outcome was defined as asymptomatic or mild cholangitis with no need of surgical or radiological intervention.

The surgical approach used for patients with a left partial common BDI is similar to the one used in complex BDI. The ischemic compromise and major bile leak, found in left common BDI, impedes adequate primary end-to-end anastomosis. Roux en Y HJ, indicated for all complex BDI, is the only successful repair for left partial common BDI with ischemic compromise.

### Technique

An exploratory laparotomy through a Kocher incision is performed, adhesions released and pre-existing bile collections are drained. We follow the drainage pathway to rule out adjacent visceral injuries caused by erosion after prolonged use of the drains. If such were the case, they would be repaired at the time of their discovery. Mucous or serous patches may be useful in duodenum erosions. Occasionally intestinal resections may be indicated.

The hepatic hilum is dissected, actively trying to maintain adequate circulation. When the injury site is identified, the biliary conducts are explored with different size dilators to identify the left and right hepatic ducts. Debridement is frequent as the presence of necrotic tissue in the duct is a common finding. Once viable tissue is found, a longitudinal incision through the anterior margin of the left hepatic duct is done. Another incision through the hilar plate facilitates its descent. In 40% of the cases a partial resection on the base of the IV and V segment, increases the surface along the caudal portion of the duct. Partial resection of the IV segment also facilitates placement of the jejunum in the hepatic hilum. A Roux en Y end-to-side HJ is performed. Even if the ducts have a small caliber, the incision along their anterior portion allows an adequate anastomosis. We do not routinely use intra-hepatic T tubes, although it is useful in scenarios where the duct is thin and scarred.

## RESULTS

### Partial Left common BDI

Out of the 405 patients with BDI, 31 patients (8%) were classified as Strasberg D (left partial injury of a major bile duct with continuity preserva-

tion). In 21 cases, the diagnosis of BDI was made at the time of the injury (index operation), in two cases the injury occurred at our hospital. Ten cases were diagnosed during the postoperative period; clinical presentations consisted of abdominal pain caused by ileum, biloma and/or biliary peritoneum.

The average age of presentation was 38 years, with a range between 19 and 68. Out of the total 31 patients with left partial injuries, 20 were female and 11 male.

Partial left common BDI occurred at four different anatomical levels throughout the extra-hepatic biliary tree. In 23 cases the injury was found along the common hepatic duct, four cases presented injuries at the confluence. Two cases sustained partial injuries in the left hepatic duct. Two more, whose initial clinical manifestation was cholangitis, had a complete left hepatic duct occlusion (Figure 1).

From the 31 left partial common BDI, a diagnostic endoscopic retrograde cholangiopancreatography (ERCP) was performed in 25 cases, which demonstrated a wide ductal leak, which ruled them out for an endoscopic repair. The remainder six cases that had a T-tube at their arrival to our institution underwent a cholangiography, revealing bile leak at the level of the injury.

Fifteen cases of left partial BDI had undergone previous intents to repair the injury through primary closure, using different materials.

Left partial lesions in the common hepatic duct received a high repair through a Roux en "Y" HJ. Injuries at the level of the confluence underwent a Roux en "Y" HJ with neoconfluence formation. The left hepatic duct partial injuries were repaired through a selective HJ to the left bile duct. The two complete left hepatic duct occlusion received different treatment. One underwent a selective HJ to the left hepatic duct. The remaining patient received a partial hepatectomy due to the presence of confluent cholangitic abscess (Figure 1).

There was no peri-operative mortality with a mean follow-up of 62 months (ranging from 1 to 160). Since 2006, 19 patients (61%) continue follow up at five years, ten cases (31%) at three years and two cases (6%) at one year. One case had postoperative cholangitis (3%), which resolved with antibiotics. Overall morbidity resulted in five cases of wound infection, two post incisional hernias and two seromas. Only two patients (2/31)(6%) who underwent a selective HJ to the left bile duct had recurrent mild cholangitis requiring conservative treatment with no surgical or radiological intervention needed.

**Table 1.** Right partial bile duct injuries. Type of lesion and treatment.

Type of lesion	Number	Surgery
C	5	Occlusion (1) External drainage (1) Selective Hepato jejunoanastomosis (3)
C1	4	Occlusion (1) External drainage (1) Selective Hepato jejunoanastomosis (2)
B	1	Hepatectomy (1)
B1	2	Hepatectomy + Stent placement (1) Hepatectomy + Hepato jejunoanastomosis (1)
F	4	Hepatectomy (1) Selective Hepato jejunoanastomosis (2) Hepato jejunoanastomosis (1)
F1	2	Hepato jejunoanastomosis (1) Hepato jejunoanastomosis + Hepatectomy (1)
F2	1	Hepatectomy (1)
F3	2	Hepato jejunoanastomosis + Hepatectomy (1) Hepato jejunoanastomosis (1)

### Right partial BDI (Strasberg A, B and C)

Right partial BDI of a main or aberrant duct occurred in 21 cases (5%). The initial manifestations of the BDI were as follows: 13 cases with biliary fistula, four bilomas/bile peritoneum and four cases with a late onset of segmental cholangitis on the right posterior hepatic segments.

Nine patients underwent a selective HJ to the injured right BD, four developed a malfunctioning anastomosis, with later segmental cholangitis without jaundice. There was no peri-operative mortality. Table 1 shows a detailed description of the number of patients, type of lesion and therapeutic choices. The different variants of the right duct injuries are shown in figure 1.

Only four patients (4/21) (19%) who underwent selective HJ to the right bile duct presented cholangitis. Two of them (9%) had an unfavorable outcome requiring radiological intervention. None of the cases underwent surgery after the index repair.

## DISCUSSION

Minor bile duct injuries, that preserve continuity (Strasberg A through D), are usually candidates for endoscopic treatment and/or radiologic intervention. Complex lesions with complete section or obstruction of a main duct (Strasberg E) should receive, as a rule, surgical therapy through a Roux en Y anastomosis.

There is a correlation between the variations in minor BDI and the proper therapeutic approach. Although there are several BDI classifications, we will refer only to the three most widely used, those developed by Strasberg,<sup>9</sup> Stewart-Way<sup>11</sup> and Bismuth.<sup>12</sup> The latter was suggested in the era before laparoscopic surgery, therefore it only describes complete sections of the extra hepatic bile tree.

Stewart-Way's classification is based on the type of lesion mechanism and includes a subdivision for hepatic artery lesion in complex bile injuries.<sup>13</sup> Strasberg's classification practically includes all possible conditions deriving from an injury in a laparoscopic cholecystectomy and those with a partial continuity gap in the lateral regions as well as in the aberrant ducts and relatively common anatomical variants.<sup>9</sup>

Left partial BDI occur almost exclusively after laparoscopic cholecystectomy. Excessive traction on Hartmann's pouch and the cystic duct (initially facilitates the dissection of the structures in the hepatoduodenal ligament, widening the space between the hepatic artery, biliary tract and portal vein) injures the main BD. After the dissection is done, instruments can be introduced among the structures in the hepatogastric ligament. While dissecting Calot's triangle, vascular injuries of the biliary tree are most frequently produced (by means of electrocautery or staples). The dissection progresses in a cephalic direction, it is at this point that most BDI occur. During some cases a complete section of the common bile duct (CBD) occurs as the instrumentation continues its path along the posterior wall of the duct. If the biliary tree has a low confluence, when traction is applied, the left bile duct may resemble a vascular structure making it more susceptible to injury. If the left or the common bile ducts were injured, we would be in the presence of a complex circumferential lesion (Strasberg E). On the other hand if the BDI has a partial left common bile duct perforation it will be classified as a (Strasberg D). The same is true for partial right injuries of the common bile duct (Strasberg A, B and C).

BDI should be suspected whenever there is fresh bile oozing, with no bile mud or stones, despite constant suction. Occasionally a primary direct suture on the small lesion is applied, either by a laparoscopic or open technique. In most situations it's difficult to assess if the primary repair of a partial (right or left) main bile duct injury will be successful and since this events are not always reported it is hard to maintain a proper record of

them in order to determine real incidence. In many of the formerly mentioned scenarios a biliary fistula may appear within days from the intervention, this happens as a result of suture dehiscence, product of prior devascularization of the duct at the time of the injury. Devascularization of the biliary tree is responsible for the primary repair (end-to-end anastomosis) malfunction. Partial BDI with vascular compromise can evolve to complete injuries. Clinical manifestations of BDI usually involve a biloma or bile peritoneum.

Strasberg D BDI occur at four different anatomical sites: the CBD, the confluence level, as a partial injury in the left hepatic duct or as a complete lesion in the left hepatic duct (Figure 1).

T-tubes to decrease ductal pressure and prevent leaks through the sutures could further complicate the lesion rather than improve it. Even 8 French tubes are difficult to introduce, longitudinal incisions on the anterior wall of the duct may often compromise duct perfusion. In our experience, patients who underwent placement of a T-tube, rather than experiencing positive results (fistula drainage control) ended up with a complex lesion with continuity loss.<sup>14</sup>

The Strasberg D variations represent the different injury mechanisms. The site of the lesion has important therapeutically considerations. As a principle, small partial left lesions of the common bile duct could be treated with a simple suture after evaluating circulatory status of the duct, note that small incomplete injuries may often maintain adequate perfusion. Initial management may include an ERCP with sphincterotomy and stent placement. However if extensive dissection occurred, it is far more likely for the duct to be devascularized. In this case regardless of the size of the lesion and its location, a HJ with its previously described variants would be the standard of care. We suggest a high anastomosis as it guarantees a properly vascularized site, with much lower dehiscence incidence.<sup>4,15</sup> Injuries located at the confluence, should receive a HJ with neoconfluence formation, rather than an end-to-end anastomosis, to guarantee a healthy tissue anastomosis.<sup>16,17</sup>

Decisions regarding early versus late repair<sup>18</sup> depends on the clinical characteristics of the patient. The best possible time to repair the injury is, during the index surgery. If the surgeon is not qualified to perform such repair surgical drains should be placed while referral to a center with a higher level of care takes place. Duct ligation in an attempt to increase duct pressure and dilate the biliary

tree is futile, as it is successful in few cases (less than 10% of our series). Usually duct ligation leads to biliary necrosis with a secondary biliary fistula.<sup>18</sup>

Sepsis or organ failure must lean the physician to prioritize medical therapy before attempting surgical reconstruction. Percutaneous or sub hepatic drains may be used until the patient overall condition improves. A definitive repair must be done when the patient has no signs of infection or acute organ failure.

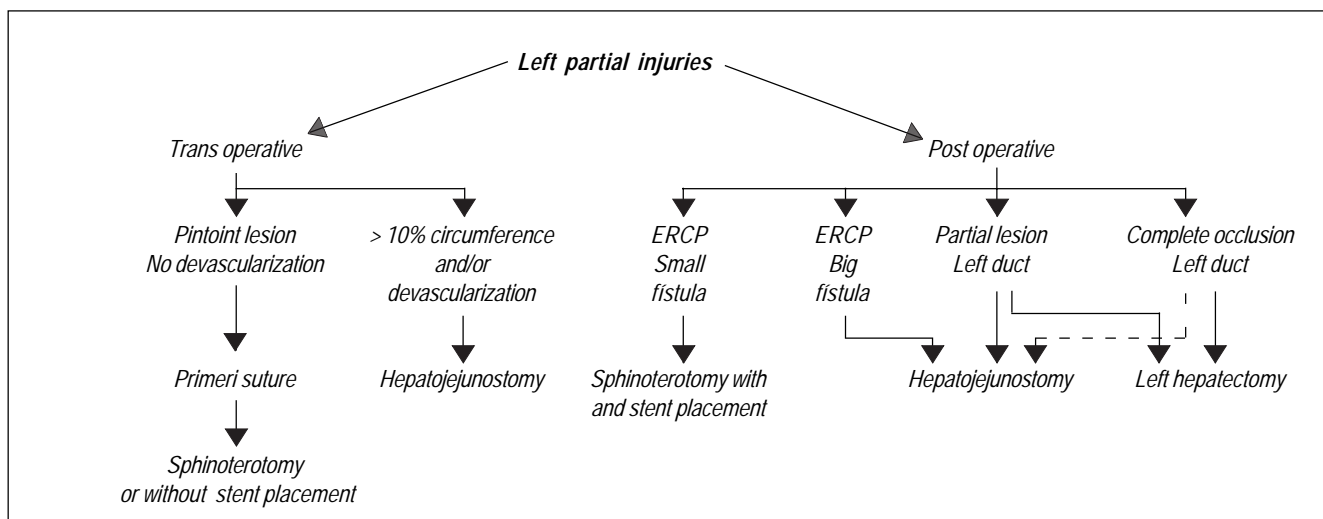
Special scenarios are complete left duct occlusions, which have other therapeutic possibilities. If the caliber of the duct is adequate, a HJ is a viable option. On the other hand, if the diameter is insufficient to perform a HJ, a hepatic resection is probably the best choice. In our series, each of the two therapeutic options occurred. One of the patients had proper duct viability hence a HJ was performed. The other patient developed cholangitic abscess, needing a hepatic resection.

The incidence of left partial injuries of the CBD (Strasberg D) corresponds to 8% of the BDI in our cohort. The different Strasberg's D anatomical variants are: D-1: lateral injury of the common bile duct, D-2: Lateral injury of the confluence, D-3: Partial injury of the left hepatic duct and D4: Complete occlusion of the left hepatic duct.

Left partial injuries of the common hepatic duct, associated with devascularization must receive a HJ, preferably at a high level. Patients with anatomical variants D-3 or D-4 should be considered for a hepatectomy when unable to find viable biliary ducts as well as in the presence of cholangitis abscess. The suggested management for left partial BDI can be found in figure 2.

Right partial hepatic duct injuries (Strasberg A, B and C) or injuries proper to the aberrant ducts are deeply related to anatomical variations. It is not uncommon to find intra or extra hepatic anastomosis of the right posterior and anterior ducts. Other variations seen in our series were intra or extra-hepatic anastomosis between the right and left aberrant ducts or a cystic duct that drains to the right posterior duct rather than the common hepatic duct.

There are different injury mechanisms for right partial BDI. Generally, the right posterior duct is confused with the cystic duct and is fully dissected and severed. In this instance, trans-operative cholangiography will reveal an intact common bile duct and a preserved confluence, showing the presence of a left duct and a right anterior duct. The previously described image may be mistakenly interpreted as a normal intact biliary tree. On a further examination



**Figure 2.** Management of left partial bile duct injuries.

it will reveal lack of contrast material in the posterior segment of the right lobe.

Complete lesions of the right hepatic duct (Stewart class IV) are fairly uncommon and generally associated with a right hepatic artery injury. The type of injury and clinical presentation depends on the anatomical condition of the stump. Complete occlusion may be present with proximal and/or distal staples, sometimes sutures. Variants of this injury include: a permeable proximal stump with an occluded distal stump, mirror conditions where only the proximal stump is occluded, no occlusions on either stump or both proximal and distal stump occlusion. The most common clinical presentations are biliary leaks, fistulas, bilomas or biliary peritonitis. Proximal occlusions always evolve into segmentary cholangitis. Liver function tests show a significant elevation in alkaline phosphatase as well as liver enzymes (AST and ALT).

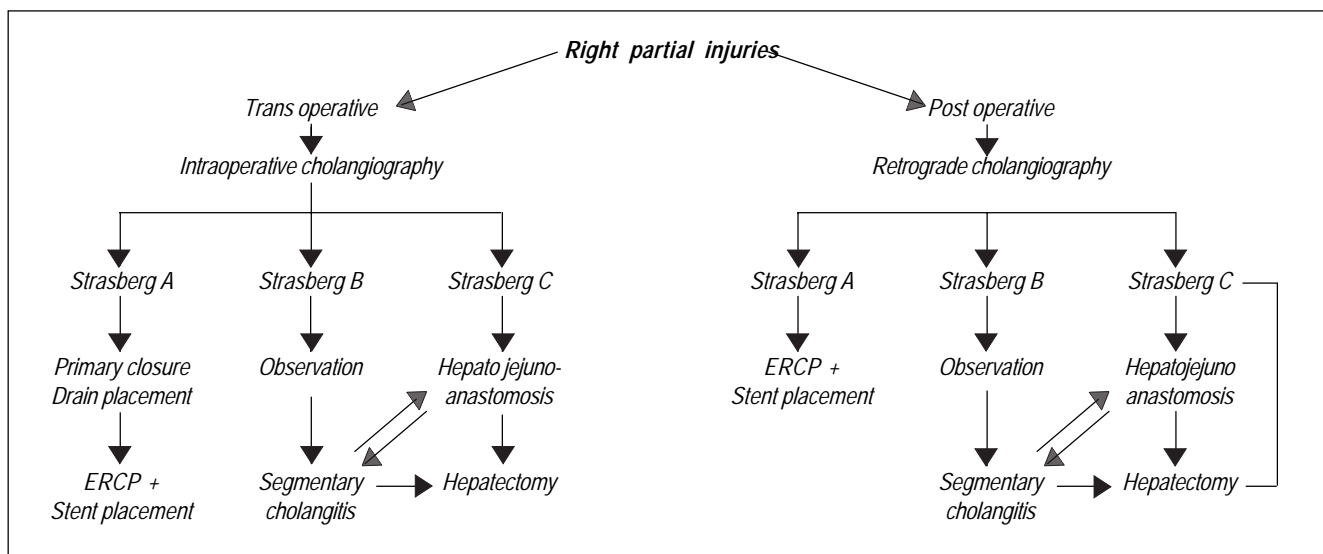
Surgical therapy has a different array of options when compared to that of partial left BDI. Strasberg et al described a technique by which the V segment (lateral to the hepatic hilum) is removed, exposing the anterior part of the right duct.<sup>19</sup> A longitudinal incision is made into the duct, to widen the biliary end of the HJ. Some cases require intra-hepatic drains, postponing the repair, thereby allowing the ischemic components of the lesion to become evident in an attempt to avoid ischemic tissue as part of the anastomosis.

In our experience the small accessory ducts result in an intricate treatment, with a HJ success rate of 50%. Because the main duct is preserved and small-thin accessory ducts are present; it is difficult to adequately place the jejunum for the anastomosis.

Endoscopic retrograde cholangiography (ERCP) both diagnostic and therapeutic can be necessary for non complex lesions (Strasberg A, B and C) for several reasons:

- It adequately marks the anatomy of the biliary tree,
- Stent placement may solve the partial injury in the main duct,
- If the biliary lesion maintains continuity with the rest of the bile tree, placement of a stent will solve the problem (Strasberg A),
- If no lesion is initially observed a secondary revision with an ERCP may show the absence of a right posterior duct. Transhepatic percutaneous approach through interventional radiology can serve the same purpose.

Depending on the findings of the cholangiography it will become evident if the patient is candidate for a surgical repair (like those in our series). Injuries that do not maintain continuity with the rest of the biliary tree are always candidates for a HJ. Some injuries with occluded right ducts may develop atrophy of the hepatic segment dependant of the injured duct (secondary segmental biliary cirrhosis), ultimately developing a compensatory mechanism with the remaining parenchyma. BDI with poor duct viability (because they are inadequate for anastomosis or because a fistula is present) or segmental refractory cholangitis may need a partial hepatectomy. When the biliary fistula is in the proximal end of the injured biliary tree it may require a hepatectomy and a HJ. A proposed thera-



**Figure 3.** Management of right partial bile duct injuries.

peutic algorithm for this type of lesions is shown in figure 3.

Only 5% of our series are right partial BDI (Strasberg A, B and C). Diagnosis is made by a careful evaluation of the biliary anatomy and a multidisciplinary approach. Although most of them are candidates for endoscopic treatment, those that evolve to complete injuries require surgical treatment. The wide array of therapeutic options includes conservative management, radiologic intervention, endoscopic stent placements and surgical treatment, selective HJ with or without a partial hepatectomy and drain placement.

The right and left partial lesions represent an unfrequent clinical scenario. We do not suggest a subclassification of Strasberg's D type of injuries but to aware surgeons of the occurrence of these rare lesions and the importance of their timely referral.

#### ACKNOWLEDGMENTS

Dedicated to the memory of Rafael Morantes MD, extraordinary surgeon and friend.

#### REFERENCES

1. Karvonen J, et al. Bile duct injuries during laparoscopic cholecystectomy: primary and long-term results from a single institution. *Surg Endosc* 2007; 21(7): 1069-73.
2. Bujanda L, et al. MRCP in the diagnosis of iatrogenic bile duct injury. *NMR Biomed* 2003; 16(8): 475-8.
3. Bergman JJ, et al. Treatment of bile duct lesions after laparoscopic cholecystectomy. *Gut* 1996; 38(1): 141-7.
4. Mercado MA, et al. Acute bile duct injury. The need for a high repair. *Surg Endosc* 2003; 17(9): 1351-5.
5. Flum DR, et al. Bile duct injury during cholecystectomy and survival in medicare beneficiaries. *Jama* 2003; 290(16): 2168-73.
6. Chapman WC, et al. Bile duct injuries 12 years after the introduction of laparoscopic cholecystectomy. *J Gastrointest Surg* 2003; 7(3): 412-6.
7. Costamagna G, et al. Multidisciplinary approach to benign biliary strictures. *Curr Treat Options Gastroenterol* 2007; 10(2): 90-101.
8. Rauws EA, Gouma DJ. Endoscopic and surgical management of bile duct injury after laparoscopic cholecystectomy. *Best Pract Res Clin Gastroenterol* 2004; 18(5): 829-46.
9. Strasberg SM, Hertl M, Soper NJ. An analysis of the problem of biliary injury during laparoscopic cholecystectomy. *J Am Coll Surg* 1995; 180(1): 101-25.
10. Callery MP. Avoiding biliary injury during laparoscopic cholecystectomy: technical considerations. *Surg Endosc* 2006; 20(11): 1654-8.
11. Stewart L, Way LW. Bile duct injuries during laparoscopic cholecystectomy. Factors that influence the results of treatment. *Arch Surg* 1995; 130(10): 1123-8. discussion 1129.
12. Bismuth H. In: Bismuth H (ed.). Postoperative Strictures of the bile duct. The biliary Tract V. New York: Ed. Churchill. Livingstone; 1982, p. 209-18.
13. Stewart L, et al. Right hepatic artery injury associated with laparoscopic bile duct injury: incidence, mechanism, and consequences. *J Gastrointest Surg* 2004; 8(5): 523-30, discussion 530-1.
14. Mercado M, et al. Bile duct injuries related to misplacement of T tubes. *Ann Hepatol* 2006; 5: 44-8.
15. Mercado MA, et al. Bile duct growing factor: an alternate technique for reconstruction of thin bile ducts after iatrogenic injury. *J Gastrointest Surg* 2006; 10(8): 1164-9.
16. Mercado MA, et al. Voluntary and involuntary ligation of the bile duct in iatrogenic injuries: a nonadvisable approach. *J Gastrointest Surg* 2008; 12(6): 1029-32.
17. Mercado MA, et al. Long-term evaluation of biliary reconstruction after partial resection of segments IV and V in iatrogenic injuries. *J Gastrointest Surg* 2006; 10(1): 77-82.

18. Mercado MA. Early versus late repair of bile duct injuries. *Surg Endosc* 2006; 20(11): 1644-7.
19. Strasberg SM, Picus DD, Drebin JA. Results of a new strategy for reconstruction of biliary injuries having an isolated right-sided component. *J Gastrointest Surg* 2001; 5(3): 266-74.

*Correspondence and reprint report:*

**Dr. Miguel Angel Mercado**

Department of Surgery, Instituto Nacional de

Ciencias Médicas y Nutrición Salvador Zubirán  
Vasco de Quiroga No. 15,  
Col. Sección XVI Tlalpan,  
14080, México, D.F.  
Phone and fax: + (52) 5573-9321  
Fax: + (52) 5573-9321  
E-mail: miguel.mercadod@quetzal.innsz.mx

*Recibido el 28 de septiembre de 2009.*

*Aceptado el 17 de marzo de 2010.*