

REVIEW

Vol. 32. No. 1 January-March 2009
pp 50-55

Intracoronary stent and non-cardiac surgery

Horacio Elitonio Mendoza-de la Vara, M.D.*

* Anesthesiologist Physician of Hospital de Cardiología Siglo XXI Centro Médico Nacional.

Reprints requests:

Horacio Elitonio Mendoza-de la Vara, M.D.
Av. Cuauhtémoc Núm. 330
Colonia Doctores
Delegación Cuauhtémoc.
06720 México, D.F.

Received for publication: 25-01-2008

Accepted for publication: 21-02-2008

SUMMARY

Nowadays, it is frequent to give attention to patients suffering from coronary artery disease in the operating rooms programmed for non-cardiac surgery. This is because the improvement of the percutaneous coronary intervention technique and the development of intracoronary stent. Through these two techniques it is achieved a good myocardial revascularization without cardiac surgery, increasing life expectation and its quality. However, the healing response from the human organism, the technique of placing and the type of stent, the used co adjuvant therapy, and the time gone from the implant at the surgery day, are all determinant factors in order to decrease or increase events such as thrombosis, restenosis and bleeding, which must be solved by the anesthesiologist. So it is important for the anesthesiologist to know the patient entirely and to be acquainted with the used interventionist procedure. Whether to postpone the surgery or not depends on the security conditions of the patient to be subjected to the surgery, and if it is elective or urgent. The anesthetic technique to be employed after the patient has been evaluated is the anesthesiologist's election.

Key words: Coronary artery disease, percutaneous coronary intervention, stent, percutaneous transluminal coronary angioplasty, myocardial revascularization, non-cardiac surgery.

RESUMEN

Al paciente con enfermedad arterial coronaria en la actualidad es frecuente atenderlo en quirófanos programados para cirugía no cardíaca; esto debido al perfeccionamiento de la técnica de intervención coronaria percutánea y al desarrollo del stent intracoronario, con lo que se logra una buena revascularización miocárdica sin cirugía cardíaca, aumentando la expectativa de vida y calidad de la misma. Sin embargo la respuesta curativa del organismo, la técnica de colocación y tipo de stent, la terapia coadyuvante utilizada y el tiempo transcurrido desde el implante al día de la cirugía, son factores determinantes para aumentar o disminuir eventos como trombosis, reestenosis y sangrado, mismos que el anestesiólogo debe resolver, siendo necesario para esto conocer íntegramente al paciente y estar familiarizado con el procedimiento intervencionista realizado. El diferir, suspender o no la cirugía queda sujeto a encontrarse el paciente dentro de los cánones de seguridad para realizar la misma y si es electiva o de urgencia, quedando a elección del anestesiólogo la técnica anestésica a emplear, previa valoración del paciente.

Palabras clave: Enfermedad arterial coronaria, intervención coronaria percutánea, stent, angioplastia coronaria transluminal percutánea, revascularización miocárdica, cirugía no cardíaca.

OVERVIEW

Ischemic heart disease and myocardial infarction resulting from coronary artery disease continues to occupy an important place in the adult cardiac patient's morbidity and mortality^(1,2).

This has motivated the development of new methods and therapeutic techniques and mechanical endoluminal devices that keep the intravascular light of already-treated vessel and decrease the incidence of accidents, complications and restenosis^(3,4).

At present, percutaneous transluminal coronary angioplasty (PTCA) remains one of the most-used and successful methods in endoluminal revascularization. Even the amended revascularization has shown to significantly decrease the stenosis of diseased vessel and improve the clinical picture of angina pectoris⁽⁵⁾.

However, the body's healing response to this mechanical process may lead to relapse^(4,5), so it becomes necessary to the placement of prosthesis to maintain the dissections sealed, delay endothelial remodeling, decrease vascular stenosis and retraction, and favor the purpose of angioplasty^(5,6).

Therefore, percutaneous coronary intervention (PCI) arises as an alternative to bypass surgery and it is aimed at achieving a good and satisfactory revascularization without cardiac surgery^(3,4), without ignoring the commonly used adjuvant therapy before, during and after the procedure⁽⁵⁾.

While percutaneous transluminal coronary angioplasty restores blood flow to the heart area previously lacking it due to the narrowed artery, compression of the atheromatous plaque is correlated with the internal process of vessel's remodeling, -inflammation process, and -acute closure. Stent placement prevents these effects and keeps the vascular light, becoming a basic part of the process of percutaneous transluminal angioplasty (PTCA)⁽⁸⁾.

The term stent derives from a dental prosthesis developed by the London dentist Charles Stent (1885) and is now used to indicate any device used for extending, stretching, or fixing in an expanded state^(4,5). It is indicated, other than PCI, in: Suspected acute vessel occlusion during angioplasty, primary decrease of stenosis, and focal novo lesions in vessels with more than 2.5 mm in diameter, focal lesions in saphenous vein grafts, total coronary occlusions, and as urgent treatment for acute myocardial infarction occlusions. An appropriate choice of stent size and design decreases the risk factor to trigger myonecrosis, thrombosis and restenosis^(8,10) (Tables I and II).

Due to the complications that occurred during implant placement, the stent can be grouped into six categories⁽⁹⁾ (Table III). The characteristics of an ideal stent focus on its

biocompatibility, adaptation, tortuosity, easy advance, re-flexibility, high radial force, reduced metal surface, low profile, radiopacity, sure positioning system, access to side branches, and thromboresistant⁽⁹⁾. Moreover, the stent can be classified according to its composition, configuration, method of implant, bioabsorption and coating (Table IV).

Thrombogenesis leads to local thrombosis or early (1 to 4 days) or late (30 days to 12 months) distal coronary embolization, which eventually ends with myocardial infarction and death^(8,11).

ANESTHETIC CONSIDERATIONS

Thrombosis, restenosis, and bleeding are events that must be solved by anesthesiologist when an intracoronary stent patient undergoes elective or emergency non-cardiac surgery. Therefore, factors such as knowledge of the placement techniques, types of devices, endovascular reactions, accidents, complications, guidelines and strategies to reduce morbidity and mortality help the anesthesiologist to choose appropriately the anesthetic technique.

Table I. Stent dimensions.

A.	Coronary arteries diameters from 2.5 to 5 mm and length varies between 8 and 33 mm
B.	Saphenous vein graft can be used stents with diameter greater than 5 mm

Table II. Stent design .

• Mesh
• Spiral
• Perforated pipe ring
• With multiple cells
• To measure
• With (PTFE) coating for coronary breakage, aneurysms and deteriorated saphenous vein graft.

Table III. Complications during placement and intracoronary stent implantation.

1. Failed placement of stent
2. Failed expansion or persistent narrowing
3. Loss of access to stent
4. Mislaced stent or embolized
5. Stent perforation
6. Dissection, thrombosis and ischemia associated with stent

Risk factors for stent thrombosis include acute coronary syndrome, small intraluminal diameter and minimal procedure, too long stent, plurivascular intervention, and persistent dissection^(8,9).

Intrastent restenosis is grouped into three categories^(4,12) (Table V), and is largely due to neointimal hyperplasia secondary to vessel injury caused by the stent's ball or bars. The risk factors for this are: Small diameter vessels, large injury, length stent, and diabetes mellitus, among others.

Such events have been observed mainly when the patient with implanted intracoronary stent undergoes non-cardiac surgery in a time less than 35 days after the implantation, regardless of whatever kind of implantation, as well as adjuvant therapy used^(13,14).

Early restenosis is mainly due to a thrombus and delayed endovascular remodeling.

Heparin-, carbon-, polytetrafluoroethylene-, and polymer-coated stents, as well as drug-eluting stents (Table VI) have been developed in order to decrease the incidence of aforementioned events.

Stent implantation performed 6 weeks or less before accomplishing non-cardiac surgery has a high incidence of migration, myocardial infarction, bleeding and death.

It is convenient to postpone the surgery until meeting the safety period from 6 to 8 week, period in which the stent remains endothelialized; moreover, it is recommended to avoid subjecting the patient to magnetic resonance before that time.

It is necessary to know used anticoagulant pharmacotherapy to treat the effect and secondary complications

thereof (in case of poor substitution or discontinuation). On the other hand, it is recommendable to know its mechanism and time of action for recognizing if they are reversible or not, as well as for estimating the bleeding risk. Screening tests and control enrolling are according to the used type of drug⁽²¹⁾.

Thrombin inhibitors, platelet aggregation inhibitors and glycoprotein IIb/IIIa receptor blockers, among others are commonly administered (Table VII).

The aspirin-clopidogrel combination is commonly used after stent implantation until for 12 months, reducing the complications of PCI. In non-cardiac surgery, aspirin becomes a drug of choice due to it is easily administered by nasogastric, rectal or intravenous route, and it is possible to continue with the preoperatively established regimen^(13,14).

So anesthesiologist faces the dilemma of continuing or discontinuing these drugs before surgery to reduce operative bleeding; however, he/she equally faces the complications that this entails. Some strategies are mentioned in international literature to solve this problem^(14,17,20), carefully assessing the type and combination of drugs that the patient is receiving. Some rules dictated by cardiologists and anesthesiologists who have encountered these situations include a period of 6 to 12 weeks after percutaneous coronary intervention for surgery, except in those cases where it is necessary to save life. It is considered unwise to discontinue anti-coagulant therapy in elective interventions. On the other hand, it has been observed that a large population with in-

Table IV. Stents types.

<ol style="list-style-type: none"> 1. Composition <ul style="list-style-type: none"> • Stainless steel • Alloy with cobalt, tantalum, nitinol, platinum and chromium • With active and inert coatings • Biodegradable 2. Configuration <ul style="list-style-type: none"> • Coils • Grooved tubes • Modular designs 3. Mode implant <ul style="list-style-type: none"> • Self-expanding (for saphenous) • Expandable with ball (most used) 4. Bioabsorption <ul style="list-style-type: none"> • Inert/biostable • Degradable/bioabsorbable 5. Coating <ul style="list-style-type: none"> • Heparin • Phosphorycholine • Carbon • PTFE (Polytetrafluoroethylene)

Table V. In-stent restenosis (classification).

<ol style="list-style-type: none"> A. Focal (≤ 10 mm length) B. Diffuse (> 10 mm length confined within of the stent) C. Proliferative (> 10 mm length extending beyond the margin)
--

Cuadro VI. Drugs released by stents.

<ul style="list-style-type: none"> • Paclitaxel • Tacrolimus • Sirolimus • Dexamethasone • Prednisone • Batimastat • Estrogen • Angiopeptin • Actinomiocina D • C – MYC Antisense

Table VII. Anticoagulant drugs used in therapy with intracoronary stent.

Anticoagulants
• Thrombin inhibitors
– Heparin
– Hirudin
– Lepirudine
– Argatroban
– Bivalirudin
– Danaparoid
Antiplatelet
• Platelet aggregation inhibitors
– Aspirin
– Ticlopidine
– Clopidogrel
Receptor blockers of Gp IIb/IIIa
• Desintegrins (Natural)
• Monoclonal antibodies of Gp IIb/IIIa
– Abciximab (ReoPro)
• Synthetic peptides and non peptides
– Eptifibatide (Integrelin)
– Tirofiban (Aggrastat)

tracoronary stent and antiplatelet regime benefits if this regime is not altered^(13,14,17).

Before elective non-cardiac surgery that meets the safety margin after stent implantation, clopidogrel may be suspended from 3 to 5 days before the event as a measure to reduce surgical bleeding, not forgetting to start replacement therapy based on low-molecular-weight heparin⁽¹⁸⁻²⁰⁾, the therapeutic regimen of aspirin (325 mg every 24 hours) and 20 minutes before surgery can be continued.

Subcutaneous administration of low-molecular-weight heparin (enoxaparin) as temporary replacement therapy (3 to 5 days) with therapeutic dose of 1 mg x kg/24 h or dose of 35 to 40 mg 1 to 2 hours before surgery to maintain the activated clotting time of thromboplastin (ATTP) twice 1.5 is recommended to reduce intrastent stenosis, thrombosis and myocardial infarction among others.

The use of short-acting antiplatelet agents, tirofiban and the substitution of clopidogrel before and during surgery, prevent serious bleeding and protect perioperatively the coronary endovascular injury.

Table VIII shows one of several guidelines to follow for patients with intracoronary stenting and non-cardiac surgery.

RECOMMENDATIONS

Know fully the patient and be aware, specifically, of the incidents during percutaneous coronary intervention and

Table VIII. Substitute pharmacological therapy.

1. Five days before surgery suspend clopidogrel
2. Three days before surgery hospitalize the patient
Start infusion of tirofiban
Start infusion of unfractionated heparin
3. Six hours before surgery:
Suspend infusion of tirofiban
Suspend infusion of unfractionated heparin
4. Postoperative first day
Start dose of clopidogrel
5. Postoperative second day
Start a maintenance dose of clopidogrel
Dose of aspirin is kept

stent placement, as well as the date in which it was performed. Determine the type of surgery and the classification thereof (elective or emergency), in the first case if stent implantation is less than 4 weeks before surgery, differ from surgery and any magnetic resonance imaging; and if stent implantation is within suggested safe limits (8 to 12 weeks) after stent implantation, begin replacement therapy protocol, perform screening test, and propose surgical management in group (anesthesiologist, surgeon, hemodynamics cardiologist, therapist). If surgery is urgent, it will be high risk: perform screening testing to find out status of anticoagulation; propose surgical management in group (anesthesiologist, surgeon, hemodynamics cardiologist, and therapist), have fresh whole blood, platelets, fresh plasma and adjuvant drugs (Figure 1). Regardless if the surgery is elective or urgent, perioperative patient monitoring must be comprehensive and invasive to obtain opportune information to guide us to any cardiac, electrolyte and acid-base dysfunction, if not, the patient should be transferred to a hospital care center that has everything necessary.

With regard to the anesthetic technique, it is recommended to first assess the coagulation status of the patient to choose among locoregional, regional or neuraxial conduction block to prevent complications including interdural haematoma and injury of nerve endings. If one of these technique is chosen, heparin should be discontinued six hours before the puncture and stent placement, only in case of elective surgery in which an alternative therapy protocol has been conducted.

General anesthesia may be intravenous, balanced, or balanced inhalation using drugs to maintain hemodynamic stability and balance between supply and demand of oxygen (O₂).

CONCLUSION

At present the patient with coronary artery disease has improved his/her quality and length of survival due to

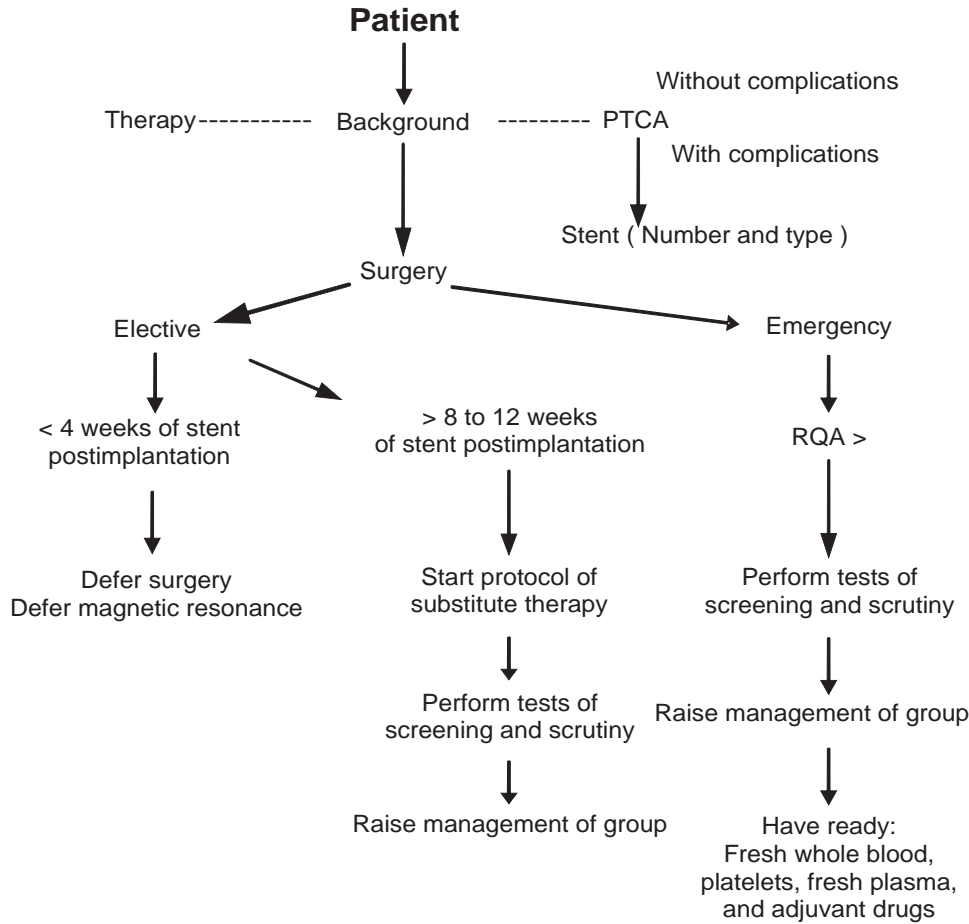


Figure 1. Perioperative guidelines to follow.

advances in PTCA and development of intracoronary stents for achieving a successful coronary revascularization without cardiovascular surgery, raising the possibility of undergoing general surgery to solve other types of pathologies; reason by which the anesthesiologist should be familiar with the procedure carried out during a PCI.

Moreover, the incidence of perioperative thrombosis, restenosis, bleeding and morbidity will be decreased by the following aspects: Knowledge of the time passed between stent placement and the accomplishment of the surgery; used adjuvant therapy; perioperative guidelines to be followed in these patients; the participation of an experienced surgical team; and count on a laboratory which conducts perioperative screening tests.

REFERENCES

1. Fleisher LA. Strategies to reduce cardiac risk in noncardiac surgery, where are we in 2005? *Anesthesiology* 2005;v105,5:801-802.
2. Yves DJ, Marino L. Noncardiac surgery in patients with coronary artery stent: what should the anesthesiologist know? *Can J Anaesth* 2005;52,4:356-361.
3. Newby DE. Prevention of cardiac complications of non-cardiac surgery: stenosis and thrombosis. *Br J Anaesth* 2004;ed II:328-332.
4. Grossman's. Cardiac catheterization, angiography, and intervention. Donald S. BAIM. Stents generalitis. Lippincott Williams and Wilkins. Seventh Edition. 2006.
5. Eagle AK, Gibbond RJ, Antman ME, et al. ACC/AHA guideline for perioperative cardiovascular evaluation for noncardiac surgery-executive summary. A report of the American College of Cardiology/American Heart Association task force on practice guidelines (Committee to update the 1996 guidelines on perioperative cardiovascular evaluation for noncardiac surgery). *JACC* Vol. 39, No. 3 2002;6:542-53.
6. Wilson HS, Panayotis F, Orford LJ, et al. Clinical outcome of patients undergoing non-cardiac surgery in the two months following coronary stenting. *JACC* Vol 42, No. 2, 2003:234-240.
7. Waksman R. Mysteries behind stent struts cathet cardiovasc interv. 2005;65:254-256.

8. Morton JH. Handbook of interventionist cardiac catheterization. In: Morton JH, ed. Hand book. 2^a ed. Ed. Cientffica Interamericana 2005.
9. Warren CJ, Tchong EJ, Blankenship CJ, O'shea CJ, et al. Temporal spectrum of ischemic complications with percutaneous coronary intervention: the esprit experience. *J Invasive Cardiology* 2005;1-14.
10. Landerberg G. The pathophysiology of perioperative myocardial infarction: facts and perspectives. *J Cardiothoracic Vasc Anaesth* 2003;90-100.
11. Gomez JA, Requiera, Fernández NE y cols. Treatment of in-stent restenosis. Current status and future perspectives. *Rev Esp Cardiol* 1999;52:130-138.
12. Vicenzi MN, Meislitzer T, Heitzinger B, et al. Coronary artery stenting and non-cardiac surgery- a prospective outcome study. *Br J Anaesth* 2006;96:686-693.
13. Spahn DR, Howell SJ, Delabays A, et al. Coronary stent and perioperative antiplatelet regimen dilemma of bleeding and stent thrombosis. *Br J Anesth* 2006;675-677.
14. Frishman HW, Sonnenblick HE. Cardiovascular pharmacotherapeutics. (Antiplatelet drug). Second edition. McGraw-Hill, 2004;13:2004-263.
15. Bradley GP, Somers KV. Drugs information handbook for cardiology. Editorial: Lexi Comp Inc. 2001.
16. Wartier CD, Kam CP, Egan KM. Platelet glycoprotein IIb/IIIa antagonists: Pharmacology and clinical developments. *Anesthesiology* 2002;96,5:1237-1249.
17. Bombeli T, Spahn DR. Updates in perioperative coagulation: physiology and management of thromboembolism and haemorrhage. *Br J Anesth* 2004;93:275-287.
18. Newby DE, Nimmo AF. Prevention of cardiac complications of non-cardiac surgery: stenosis and thrombosis. *Br J Anaesth* 2004;92,5:628-632.
19. Garcia EA, Casey M, Szitefman C y cols. Recomendations for the use of antithrombotics in interventional cardiology. *Rev Argent Cardiol* 2003;71,4:282-284.
20. Broad L, Lee T, Conroy M, et al. Successful management of patients with a drug-eluting coronary stent presenting for elective, non-cardiac surgery. *Br J Anaesth* 2006;98,1:19-22.
21. Becq KMC. The «prise in charge» of a patient with anticoagulants or antiplatelet agents before of transurethral resection of prostate. *Rev Med Univ* 2006;2,2:1-3 ó 14-18.