



ARTÍCULO EXPERIMENTAL

In non-preserving surgery: the hyperbaric chamber accelerates the time of recovery

Histological and functional evidence with nerves interposed in an experimental model

Figueroa-Granados V,¹ Raquel Eguiluz O,² Venegas Aureliano AS,³ Sánchez Cuauhtémoc E,⁴ Hernández-Pando R⁵

SUMMARY

The effect of hyperbaric oxygen (HBO₂) therapy on peripheral nerve after its transection and repair, using microsurgical technique, was studied using the rat sciatic nerve model. Following repair, 50 animals were randomly assigned to four groups: 1) No HBO₂, sectioned and repaired (n = 10) killed at 7 weeks. 2) HBO₂, sectioned and repaired (n = 10) killed at 7 weeks. 3) No HBO₂, sectioned and repaired (n = 10) killed at 14 weeks. 4) HBO₂, sectioned and repaired (n = 10) killed at 14 weeks. Nerve recovery was assessed by neurophysiological studies (EMG and motor latency) comparing the response before nerve section and after repair, at base line, and after 7 or 14 weeks in all groups. Electromyography was performed comparing HBO₂ treated rats and no treated controls after 7 and 14 weeks. Foot-ankle angle response (dorsiflexion) was assessed and histopathology with automated morphometry (axon number, myelin area, blood vessels number) was performed after 7 or 14 weeks. At 7 weeks, motor latency increased

RESUMEN

Antecedentes: Los tiempos de recuperación de la función en las PRR con interposición de nervio sural son aun prolongados. La literatura que respalda el efecto benéfico de la cámara hiperbárica aumenta cada día.

Objetivo: Evaluar el efecto que la terapia con oxígeno hiperbárico tiene sobre el tiempo de éxito de una interposición de nervio periférico.

Material y métodos: Cincuenta ratas Wistar se aleatorizaron en grupos de 10 individuos cada uno. Un grupo de controles sanos, misma talla y edad. La terapia con hiperbárica fue administrada (Monoplace Ncup 44.1 psi; Sechrit, CA). Se midió la recuperación nerviosa mediante estudios neurofisiológicos presacrificio en la semana 7 y 14. Se hicieron mediciones funcionales, histopatológico. El análisis estadístico con t de Student y Anova de una vía.

Resultados: En la semana 7 ya existe un incremento estadísticamente significativo en la cantidad de axones, vasos sanguíneos en los individuos tratados con oxígeno hiperbárico. Después de 14 semanas

1 M.D. Ph. D.: Consultant Urologist. Hospital Ángeles. Leon Gto.
2 M.D.: Consultant Plastic Surgeon. Hospital Ángeles del Pedregal. Mexico City. 3 Consultant in Physical Medicine and Rehabilitation. Hospital PEMEX Sur. Mexico City. 4 M.D.: Medical Director Hiperbaric Medicine Department. Hospital Ángeles del Pedregal. Mexico City. 5 M.D. Ph. D.: Head of the Pathology

Department. Instituto Nacional de Ciencias Médicas y Nutrición. Mexico City.

Correspondencia: Víctor Figueroa-Granados. Avenida Cerro Gordo, Núm. 311, Consultorio 410. CP. 37150. León, Guanajuato. Tel.: 01(477) 7171779. Correo electrónico: vfig@hotmail.com.

significantly in the control non-treated group, whereas amplitude was higher in the HBO₂ treated group together with better foot-ankle angle response, higher axons and blood vessels number, and an increase in myelin surface area. After 14 weeks, electromyography showed moderate denervation (90%) and a better foot-ankle angle response in groups treated with HBO₂. These results suggest that functional recovery in transected peripheral nerves may be improved by hyperbaric oxygenation following microsurgical repair its application can be extended to the radical prostatectomy with sural nerve interposition.

Key words: hyperbaric oxygen, nerve, radical prostatectomy.

las mediciones funcionales electromiográfica y dorsiflexión mostró una mejoría más importante en el grupo tratado con oxígeno hiperbárico.

Discusión: El hallazgo principal de este estudio fue que existe un incremento más temprano de 27.81% en el número de axones por micra cuadrada en los nervios tratados con oxígeno hiperbárico. ¿Significa eso una recuperación en la función?

Conclusiones: La terapia inmediata con oxígeno hiperbárico acelera la recuperación funcional en los nervios periféricos interpuestos en un nervio seccionado. La cámara hiperbárica podría contribuir al éxito en la prostatectomía radical.

Palabras clave: oxígeno hiperbárico, nervio, prostatectomía radical.

INTRODUCTION

Our understanding of the basic underlying mechanism of peripheral nerve regeneration has been advancing rapidly and although there is an immense progress in cellular, biochemical and ultrastructural elements of nerve injury and repair,¹ our knowledge is still quite limited. Nevertheless we continue searching for better ways to improve nerve regeneration, including hyperbaric oxygenation as it is an accepted adjuvant treatment for several conditions,² among them, acute traumatic ischaemias. Traumatic lesions of the extremities are responsible for most of the peripheral nerve injuries. Injured nerves may have a compromised blood supply, edema and impairment of oxygenation that may trigger a vicious cycle of further hypoxia and edema.

When resection of one or both neurovascular bundles is necessary in radical prostatectomy it is possible to use a technique for placing interposition grafts from the sural nerve to one or both neurovascular bundles.²⁷⁻²⁸ Surgeons have performed nerve grafts successfully for many years to repair transected peripheral sensorimotor nerves. The basis for nerve regeneration, and consequently for nerve grafting, is the capacity of axons to produce axon sprouts. After the transection has occurred axons sprouts will invariably grow, then it will

be produced a neuroma if they do not come into contact with an environment adequate for their growth. The cut end of the nerve sprouts minifascicles that contain axons sprouts, fibroblasts, Schwann cells and capillaries. The minifascicles grow haphazardly for a limited distance and then a neuroma is produced. On the other hand if the axons encounter an empty nerve sheath, growth is organized and directed, resulting in a new nerve. A nerve graft function is to provide a conduit through which regenerating nerves are oriented to join the distal end of the transected nerve. This description supports the idea that cavernous nerve grafts may restore penile autonomic innervation and also restore therefore will permit to experiment spontaneous erections following deliberate neurovascular bundle resection at the time of radical prostatectomy. According to some of the work available to date. One third of patients with bilateral nerve resection and placement of bilateral nerve grafts had spontaneous, medically unassisted erections sufficient for a sexual intercourse. The greatest return of function is observed 14 to 18 months after surgery. Having established the ability of nerve grafts to restore natural spontaneous erectile function after wide resection of both neurovascular bundles, they began to perform unilateral interposition nerve

grafts when one neurovascular bundle was resected. Between 1998-2002 a total of 108 previously potent patients underwent placement of a unilateral interposition of the cavernous nerve by a graft or a sural nerve graft. The observations of these patients demonstrate that 24 of the patients without a graft were potent *versus* 42% of the patients that had at least one graft after prostatectomy. These and other authors confirm that, nerve grafts provide in solution to a common surgical dilemma. To resect into the posterolateral capsule close to the nerve even this is a high risk for the recovery of potency.

Hyperbaric oxygen treatment has been used for peripheral nerve injuries since the seventies³⁻⁷ the rationale for its use is to provide optimal tissue pO₂ tension to maintain the neural aerobic metabolism and viability of the tissue, reduce edema, and enhance perfusion of the injured tissue, breaking the vicious cycle of edema and hypoxia, restore axonal transport, and enable the necessary delivery of nutrients at the site of injury; accelerate healing and promote neovascularization.⁸ HBO₂ has shown favourable effects on healing of mechanically damaged peripheral nerves induced by nerve transection or crushing injury or both in animal models⁹⁻¹⁶ and in humans.¹⁷⁻²¹ It has also been reported benefits from HBO₂ in the peripheral and central nervous system, mainly due to improvement in microcirculation as it has been considered that mechanical compression destroys nerve blood supply, leaving the nerve anoxic and stopping axonal transport. Ochs²² has shown, *in vitro*, fast axonal transport restored by the transport administration of normobaric O₂ (95%) to an anoxic nerve. Therefore, HBO₂ seems to play a role in facilitating peripheral nerve recovery.

MATERIAL AND METHODS

Fifty male Wistar rats, average weight of 295 g, were randomly distributed into four groups and into control groups, one with and one without HBO treatment. The surgeon and investigators measuring the outcome were blinded to groups assignment. Animals were anesthetized with intraperitoneal pentobarbital (40 mg/kg), shaved, and prepared with antiseptic solution. The right sciatic nerve was then exposed through a posterolateral approach using a semitendinous

biceps femoris (long-head) muscle splitting incision. The left unoperated leg served as control in all animals. The sciatic nerve was dissected free of surrounding connective tissue and transected sharply with a number 15 blade, a piece of blue background material was placed under the sciatic nerve, to improve its view. One millimeter of epineurium was trimmed from the ends with straight scissors. The nerve ends were then realigned and repaired, using standard microsurgical techniques with two interfascicular 11-0 nylon and three epineural 10-0 nylon sutures. All repairs were performed by the same microsurgeon who was blinded to the randomization process. The skin incision was closed with running 6-nylon. Animals were randomly assigned to four groups: 1) Not HBO₂ treated, sectioned and repaired ($n = 10$) killed at 7 weeks. 2) Sectioned and repaired, plus 10 days of HBO₂ ($n = 10$) killed at 7 weeks. 3) Sectioned and repaired, not HBO₂ treated, killed at 14 weeks. 4) Sectioned and repaired, plus 10 days of HBO₂ ($n = 10$) killed at 14 weeks. HBO₂ treatment was administered twice daily with 100% oxygen at 2.0 atmosphere absolute for 90 absolute minutes for 10 days. The first treatment was given within three hours of surgery. All treatments were performed in the animal hyperbaric chamber (Monoplace Ncup 44.1psi. Sechrit, Calif. U.S.A.). Oxygen concentrations within the chamber were monitored with a calibrated oxymeter to ensure 100% oxygen during treatment. Independent variables were: HBO₂ treatment or no treatment. Dependent variables were: 1) Neurophysiological evaluation by measuring motor latency, foot-ankle angle values (degrees), and electromyography. 2) Hystopathologic evaluation, including myelin surface, myelinated axons number, and blood vessels count. Neurophysiological studies Foot-ankle angles were evaluated to determine the functional recovery of the sciatic nerve and the group of muscles it supplies. The measurement was recorded with a goniometer, grasping the rat from the back of the body and holding it in space with one hand, while the angle was measured in a free position. The angle during dorsiflexion of the affected leg was measured, considering 15° as the normal angle. A larger than 90° angle would indicate less activity of the group of muscles involved in dorsiflexion, as well as foot drop and loss of the footprint. Motor latencies were as-

sessed with needle and surface electrodes placed in the distal part of the affected leg; an electric stimulus was applied in the proximal part above the lesion. Recordings were made with Nicolet Viking IV D. U.S.A. equipment. The electromyography study was performed on the interossei muscles of the foot at 7 or 14 weeks with monopolar needle electrodes. The EMG was classified according to the signs of recovery by assessing reinnervation or denervation. Positive waves and fibrillations were considered signs of denervation and therefore classified as group 3 (+++). Group 2 (++) corresponded to recovery signs, and Group 1 (+), i.e., with few positive waves, corresponded to a good recovery. Preparation of nerve tissue for histology and automated morphometry analysis. All rats were killed, by administering a lethal anesthetic dose, 7 or 14 weeks after sciatic nerve transection and its microsurgical repair. The sciatic nerve was dissected and the previously surgically restored segment was identified, removed, and sectioned in two. Both sections were immediately fixed by immersion in a solution of 4% glutaraldehyde dissolved in 0.20M cacodylate buffer, pH 7.3, for 4 hours at 4°C. Small tissue fragments were postfixed in 1% osmium tetroxide, dehydrated in graded ethyl alcohols, and embedded in Epon resin. One micrometer width transversal nerve sections were obtained, placed on glass slides, stained with toluidin blue, and examined under light microscopy. The number of transversal sectioned axons, the surface area occupied by the myelin layer, and number of blood vessels were determined by automated morphometry using Leica QW500/W (Leica, Milton Keynes, U.K.). image analyzer. Three random fields at 200x magnification from each animal were used for these determinations. **Statistical analysis:** Student's t test was used to determine statistical significance in these histological parameters, comparing HBO₂ treated rats and control non-treated animals. A difference of $p < 0.05$ was considered significant. All calculations were made with a SPSS/PC (SPSS Inc. Chicago Il). Data are given as mean and standard deviation. Results within each group were analyzed using one-way ANOVA. Comparison between pairs of means was done with paired Student's t test. A value of $p < 0.05$ was considered significant, unless three groups were compared ($p < 0.01$).

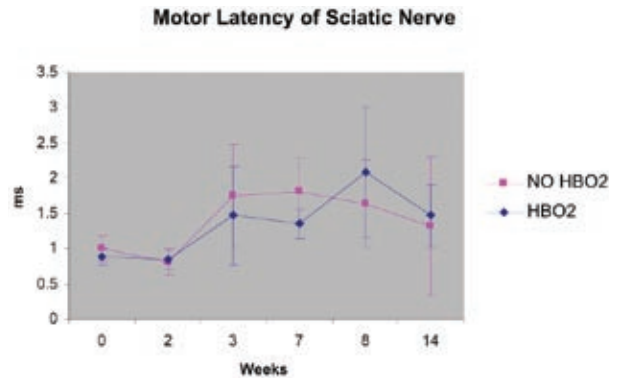


Figure 1. At week 7, there was a significant increase in latency ($p < 0.033$)* in the non-treated group. However, at the 14th week, there was no significant difference between both groups.

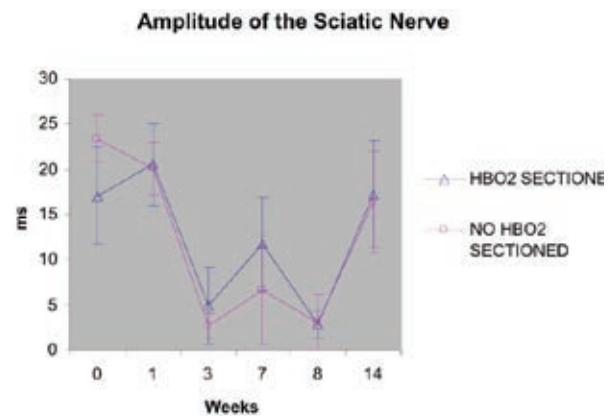


Figure 2. Although no statistically significant difference existed between both groups, the amplitude of the nerve response was greater in the HBO₂ treated group at 7 weeks.

RESULTS

1) Motor latencies were assessed before nerve transection and after its repair (baseline recordings), and at 7 or 14 weeks thereafter. A) Duration was not statistically different (data not shown). B) Latency was significantly delayed at 7 weeks ($p < 0.033$) in the group of rats that did not receive HBO₂ (figure 1) as compared with the group that received HBO₂. C) Amplitude was not different significantly (figure 2) between the two groups, although it was greater in the group of rats that received HBO₂ treatment, particularly at 7 weeks. 2) Foot ankle-angle was considered normal at 15° (table 1); as can be observed, it improved in the treated group.

Table 1. Comparison of the foot-ankle angle groups between HBO₂ treated or not.

KILLED	7 WEEKS		14 WEEKS	
	Group I (No HBO ₂)	Group II (HBO ₂)	Group III (No HBO ₂)	Group IV (HBO ₂)
No. of rats	10	10	10	10
TOTAL: 40				
Foot-ankle angle degree	57.5°-17.19	45.5°-18.17	68°-16.4	57.2°-11.18

Table 1. Groups treated with HBO₂ and not treated, including foot-ankle angles showing an increase in angulation at weeks 7 and 14, which was more severe in rats that did not receive HBO₂ treat.

The electromyography revealed (table 2) that most rats without HBO₂ treatment had a severe degree of denervation at 7 weeks, whereas 60% of those receiving hyperbaric oxygen, depicted moderate denervation, only 40% had severe denervation at 7 weeks. Fifty per cent of the group of rats without HBO₂ treatment at 14 weeks, showed moderate denervation, and 20% severe denervation, and 30% light denervation; whereas, in the group with HBO₂ treatment, 90% showed moderate denervation and only 10% light denervation, none showed severe denervation. It is important to mention that electromyographic differences were more significant at 14 weeks, since the nerve recovers slowly. Comparative histological analysis and automated morphometry.

We preferred Epon resin inclusion and postfixation with osmium tetroxide over paraffin embedded tissue sections because the histological structures are better defined and tissue overlapping, is avoided; the black of the myelin layers produced by osmium tetroxide allows for better measuring of this important nerve component. Transversal sections of the sciatic nerve in the middle of the surgical reconstituted area showed small patches of chronic inflammation surrounded by fibrosis and occasional foreign body granulomas embracing suture material. After 7 weeks of nerve transection and repair, the surface of axon myelin layers increased in the HBO₂ treated groups and continued in the same way up to 14 weeks (figure 3).

Table 2. Denervation results from the EMG study.

KILLED			
7 WEEKS		14 WEEKS	
GROUP I	GROUP II	GROUP III	GROUP IV
70% +++	60% ++	50% ++	90% ++
30% ++	40% +++	30% +	10% +
		20% +++	
NO HBO ₂	HBO ₂	NO HBO ₂	HBO ₂

Table 2. Electromyography. At 7 weeks the group that received hyperbaric oxygenation had less severe denervation as compared with rats that did not receive HBO₂, the difference was even larger at 14 weeks, between treated and non treated rats.

HBO₂ treated rats during 7 weeks showed numerous small axons, and the automated morphometry analysis showed a 70.8% increase in the number of axons in their sciatic nerve in comparison with the non-HBO₂ treated rats (figure 4). At 14 weeks post-transection and repair of the sciatic nerve, there was no difference in the number of axons between HBO₂ treated and non-treated control animals. After 7 weeks of nerve transection and repair, HBO₂ treated animals showed an important increase of small blood vessels (capillaries, arterioles) over the control non-treated group (figure 5). After 14 weeks of nerve lesion and surgical repair, the number of small vessels was the same in both HBO₂ treated and control non-treated groups (figure 6).

DISCUSSION

The long time necessary to recover sexual potency after radical prostatectomy with no preservation of uni or bilateral cavernous nerves. The well known and validated method to transpose sural nerve in many examples. The main finding in this study was that HBO₂ treatment enhances peripheral nerve regeneration as evaluated through motor latency, electromyography, ankle-foot angles, and histopathological analysis. Peripheral nerve fibers show a far greater capacity for regeneration than do those in the central nervous system, and this is one of the most important features distinguishing

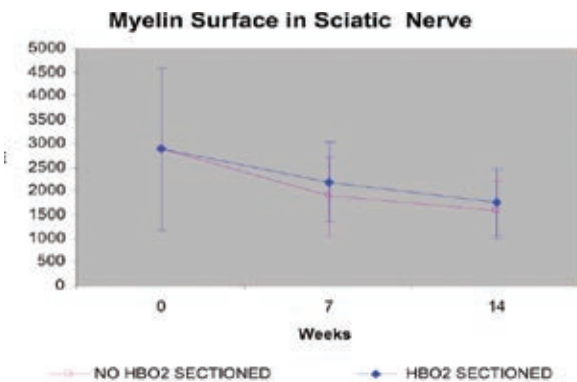


Figure 3. Myelin layers increased in the HBO₂ treated groups up to 14 weeks.

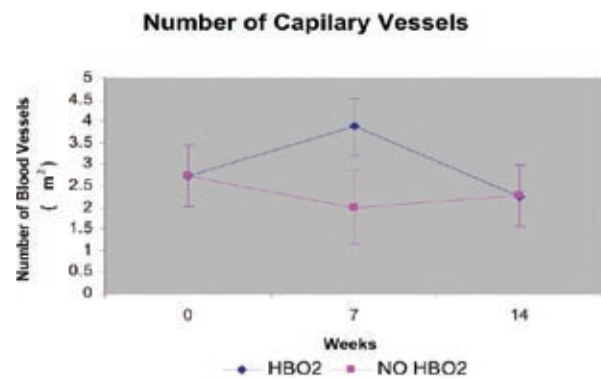


Figure 5. Increase in the number of blood vessels over the control non-treated group at 7 weeks.

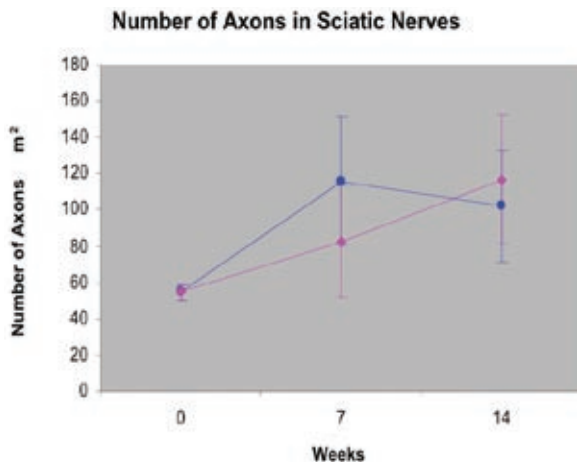


Figure 4. There is a 70.8% increase in the number of axons at 7 weeks in the HBO₂ treated rats.

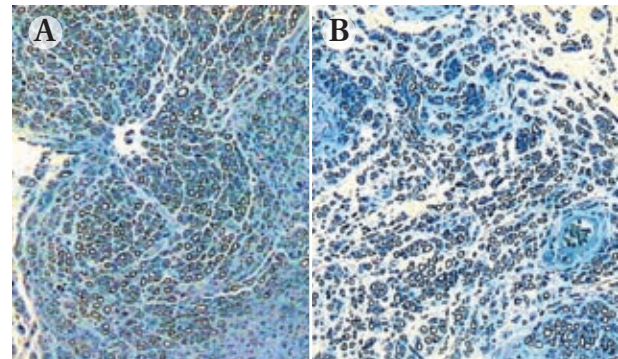


Figure 6. Representative histology features from transversal sections of sciatic nerves. A. An apparent lower number of axons and blood vessels is shown in the sciatic nerve from a non-HBO₂ treated rat after 14 weeks of transection and surgical repair. B. HBO₂ treated rats, at 14 weeks, showing an increase in axons. Magnification, 200x; toluidin blue staining.

both components of the nervous system. Our experimental data suggest that hyperbaric oxygenation may improve and accelerate peripheral nerve regeneration. We believe that the greater number of axons seen at 7 weeks in the HBO₂ group, was secondary to an intense regenerative activity related with an angiogenic effect induced by tissue oxygenation. However, no further axon growth was observed at week 14, and their number even decreased probably because these regenerated axons failed to follow the bands of Bügner or growth cones and entered the connective tissue compartment. Thus, it is likely that the greater number of axons produced at week 7 could not match the less numerous axons from the distal stump, partially

interfering with nerve bridging after total axotomy. In the present work, the sciatic nerve was transected not crushed as done by other authors,¹¹⁻¹⁴ to preserve the basal lamina of Schwann cells, considered to have a trophic role since they can retain trophic factors such as the fibroblast growth factor involved importantly in regenerating axons; in spite of not preserving the basal lamina in this experiment, the group that underwent HBO₂ had a better outcome. It seems probable that hyperbaric oxygenation increases the number of Schwann cells associated with Wallerian degeneration, producing a variety of trophic factors that participate in nerve regeneration, and they are probably of great relevance in restoring lost qualities of the nerve. It was observed

that the number of capillary vessels increased at 7 weeks in the groups treated with HBO₂. This neovascularization effect of HBO₂ has been documented extensively in the literature.^{23,24} It has also been suggested that the stimulus for angiogenesis is mediated through tissue macrophages that migrate and release growth factors.^{25,26} There is no doubt that after nerve transection there must be a hypoxic state in the involved tissues and, therefore, the arterial partial pressure of oxygen (PaO₂) and tissue oxygen tension might trigger angiogenesis, which is most important during the first weeks of peripheral nerve regeneration. We also think that the benefit of HBO₂ does not extend to the 14th week, but is helpful in the first weeks as it accelerates the repair process, increasing growth factors locally. This effect could shorten the time required for patient's sexual rehabilitation, which in the end would represent a great advantage for the recovery time.^{27,28}

CONCLUSIONS

The information available from previous experiments and the present study suggests that hyperbaric oxygenation has a place in the treatment of peripheral nerve damage even though this is an area wide open for further research. Velocity of recovery is shortened significantly in the presence of hyperbaric oxygen therapy. Our experimental work interpolated to human situation will encourage more work in this area.

The final proof of the efficacy of nerve grafts after unilateral or bilateral non preserving nerves surgery must await the finalization of the prospective and comparative and randomized studies, comparing nerve grafts (uni or bilateral) versus no grafts after unilateral NVB resection. Until then we should utilize judgement to do NVB grafts, under informed consent to decide whether a nerve graft is or not indicated.

ACKNOWLEDGEMENTS

The authors are grateful to Dr. Solis-Maldonado, G. Consultant Neurosurgeon and Head of the Department of Neurosurgery of Hospital PEMEX Sur, for providing the facilities and support to this research.

The authors also thank Dr. Guzman Gonzalez F, for his skillful technical assistance and help with animals and to Contreras-León, J.C. Biologist who prepared all the histology slides.

BIBLIOGRAPHY

1. Panayotis, KT, Okajima S, Terzis JK. Ultrastructure and cellular biology of nerve regeneration. *J Reconstr Microsurg.* 1998;14:423-436.
2. Hampson N. Hyperbaric Oxygen Therapy: A Committee Report. *Undersea Hyperbaric Medical Society.* 1999;1(5):19.
3. Yu WY, Shimm SS. The effect of hyperbaric oxygen on nerve regeneration, an experimental study in the femoral nerve of rabbits. In: Proceedings on the 5th International Congress on hyperbaric medicine. Burnaby, B.C., Canada; Simon Fraser University. 1974: 473-478.
4. Gignoux M, Firica A, Ray A. Effects of ischemia and hyperbaric oxygen on the neuromuscular excitability of the dog paw applications preliminary to reimplantation of the limb. *Lyon Chir.* 1970; 66:167-170.
5. Takahashi M, Hirose N, Takeuchi H, Minamiguchi T, Kyo S. Clinical and electrophysiological evaluation of hyperbaric oxygenation in SMON. *Nippon Rinsho.* 1974;32:362-364.
6. Mukoyama M, Lida M, Sobue I. Hyperbaric oxygen therapy for peripheral nerve damage induced in rabbits with cloquinol. *Exp Neurol.* 1975;47:371-380.
7. Holbach KH, Wassmann H, Linke D. The use of hyperbaric oxygenation in the treatment of spinal cord lesions. *Eur Neurol.* 1977;16(1-6):213-21.
8. Jain, KK. Textbook on Hyperbaric Medicine. 1999;478-480.
9. Kihara M, McManis PG, Schmelzer JD, Kihara Y, Low PA. Experimental ischaemic neuropathy: salvage with hyperbaric oxygenation. *Ann Neurol.* 1995;37(1):89-94.
10. Zamboni WA, Brown RE, Roth AC, Mathur A, Stephenson LL. Functional evaluation of peripheral nerve repair and the effect of hyperbaric oxygen. *J Reconstr Microsurg.* 1995;11(1):27-9.
11. Bradshaw PO, Nelson AG, Fanton JW, Yates T, Kagan-Hallet KS. Effect of hyperbaric oxygenation on peripheral nerve regeneration in adult male rabbits. *Undersea Hyperb Med.* 1996;23(2):107-13.
12. Haapaniemi T, Nylander G, Kanje M, Dahlin L. Hyperbaric oxygen treatment enhances regeneration of the rat sciatic nerve. *Exp Neurol.* 1998;149(2):433-8.

13. Haapaniemi T, Nishiura Y, Dahlin LB. Effects of hyperbaric oxygen treatment on axonal outgrowth in sciatic nerve grafts in rats. *Scand J Plast Reconstr Surg Hand Surg.* 2001;35(1):7-11.
14. Bajrovic FF, Sketelj J, Jug M, Gril I, Mekjavic IB. The effect of hyperbaric oxygen treatment on early regeneration of sensory axons after nerve crushes in the rat. *J Peripher Nerv Syst.* 2002;7(3):141-48.
15. Perez-Bolde A, Sanchez EC. Hyperbaric oxygen therapy in the peripheral nerve regeneration. *Undersea and Hyperbaric Medicine.* 1999;26-40.
16. Liu, QL, HeB P. Effects of hyperbaric oxygen therapy on rat sciatic nerve injury. *Undersea and Hyperbaric Medicine Biomed Res.* 1994; 21:3341-343.
17. Tyshkevich TG, Bersnev VP, Rafikov AM. The prospects for the sequential use of hyperbaric oxygenation and muscle electrostimulation for the rehabilitation of patients with nerve injuries. *Vopr Kurortol Fisioter Lech Fiz Kult.* 1990;(4):26-30.
18. Zhao DW. Therapeutic effect of hyperbaric oxygen on recovery of surgically repaired peripheral nerve injury. *Zhonghua Wai Ke Za Zhi.* 1991;29(2):118-120, 143.
19. Najajima M, Kuwabara S, Uchino F, Hiriyama K. Enhanced regeneration of terminal axons after hyperbaric oxygen therapy in a patient resembling progressive postpoliomyelitis muscular atrophy. *Rinsho Shinkeigaku.* 1994;34(1):48-51.
20. Gen J, Wang YW, Gao HJ. Hyperbaric oxygen therapy of nerve injuries: 3 case report. *J Xi An Med Coll.* 1982;6:797-798.
21. Viera C, Galvez C, Carrasco B, Santos C, Castellanos R. A study of peripheral neural conduction, motor and sensory in diabetic patients treated with hyperbaric oxygenation. *Rev Neurol.* 1999;28(9):868-72.
22. Ochs, S. Energy metabolism and supply of P to the fast axoplasmic transport mechanism in nerve. *Fed Proc.* 1974;33:1049-1058.
23. Marx R.E, Ehler WJ, Tayapongsak P, Pierce LW. Relationship of oxygen dose to angiogenesis induction in irradiated tissue. *Am J of Surg.* 1990;160:519-524.
24. Knighton DR, Silver IA, Hunt TK. Regulation of wound angiogenesis. Effect of oxygen gradients and inspired oxygen concentration. *Surg.* 1981;90(2):262-269.
25. Polverini PJ, Coran RS, Ginbrone MA, Unanue ER. Activated macrophages induced vascular proliferation. *Nature.* 1977;269:804.
26. Thakral KK, Goodson WH, Hunt TK. Stimulation of wound blood vessel growth by wound macrophages. *J Surg Res.* 1979;26:430.
27. Kim ED, Scardino PT, Hampfel O. Interposition of sural nerve restores function of cavernous nerves resected during radical prostatectomy. *J Urol.* 1999; 161:188.
28. Kim ED, Nath R, Kadmon D. Bilateral nerve graft during radical retropubic prostatectomy: 1 year follow-up. *J Urol.* 2001;165(6pt1):1950-1956.