

## First identification of Herpesvirus infections among endemic and exotic psittacines in Mexico

Turrall Ramírez Ma. Montserrat<sup>a</sup>

Córdova Ponce Rodolfo<sup>a</sup>

González Ruíz Cynthia<sup>b</sup>

 0000-0001-8786-399X

Castañeda Aceves Graciela<sup>c</sup>

Marín Flamand Ernesto<sup>b</sup>

 0000-0003-1475-8982

Garrido Fariña Germán<sup>d</sup>

 0000-0003-2137-9315

Ramírez Álvarez Hugo<sup>a\*</sup>

 0000-0003-1682-8104

<sup>a</sup> Laboratorio de Virología,  
Genética y Biología Molecular,  
Facultad de Estudios Superiores Cuautitlán (FESC),  
Campo 4, Universidad Nacional Autónoma de México  
(UNAM), Estado de México, México.

<sup>b</sup> Laboratorio de Patología,  
Facultad de Estudios Superiores Cuautitlán (FESC),  
Campo 4, Universidad Nacional Autónoma de México  
(UNAM), Estado de México, México.

<sup>c</sup> Laboratorio de Análisis Clínicos,  
Facultad de Estudios Superiores Cuautitlán (FESC),  
Campo 4, Universidad Nacional Autónoma de México  
(UNAM), Estado de México, México.

<sup>d</sup> Laboratorio de apoyo a Histología y Biología,  
Facultad de Estudios Superiores Cuautitlán (FESC),  
Campo 4, Universidad Nacional Autónoma de México,  
Estado de México, México.

\*Corresponding author:

Tel: 55 5623 1920

Email address:

[ramiralh@unam.mx](mailto:ramiralh@unam.mx)

### Abstract

The illegal trafficking of exotic birds such as parrots is now the third most lucrative business in the world and has been a problem for several years. As a result of this trafficking, there has been an increase in the emergence of exotic diseases. Herpesvirus is a pathogen of psittacines that has not been identified in Mexico to date. Through the use of polymerase chain reaction (PCR) assays and pathological analyses, the present study demonstrates the presence of herpesvirus in endemic and exotic psittacines in Mexico. The study was based on 50 birds, with clinical signs of herpesvirus infection, and 45 clinically healthy birds. DNA samples were obtained from proctodeal cells of the healthy birds, collected through the use of an enema; additionally, the liver, kidneys, brain, large intestines, and lungs of five birds exhibiting clinical signs suggestive of herpesvirus infection, were collected and fixed in buffered formalin for histopathological examination. PCR assays revealed herpesvirus infection in 8 clinically healthy birds, including four exotic species, and one endemic species. On necropsy, four of the five birds with clinical signs of herpesvirus infection showed lesions caused by herpesvirus, and the presence of intranuclear inclusion bodies in various tissues. Thus, these results demonstrate that there is a high risk of herpesvirus infection in endemic Mexican psittacines, which could significantly impact the health of these populations.

**Keywords:** Herpesvirus, Psittacines, Proctodeum Cells, PCR, Histopathology.

Received: 2017-05-23

Accepted: 2017-10-19

Published: 2017-10-31

Additional information and declarations  
can be found on page 9

© Copyright 2017

Turrall Ramírez Ma. Montserrat Pérez *et al.*

open access 



Distributed under Creative Commons CC-BY 4.0

### Cite this as:

Turrall Ramírez MM, Córdova Ponce R, González Ruíz C, Castañeda Aceves G, Marín Flamand E, Garrido Fariña G, Ramírez Álvarez H. First identification of Herpesvirus infections among endemic and exotic psittacines in Mexico. *Veterinaria México OA.* 2017;4(4). doi:10.21753/vmoa.4.4.469

## Introduction

Herpesviruses that predominantly infect psittacines (e.g., parakeets, parrots, macaws, and cockatoos) belong to the subfamily *Alphaherpesviridae* and the genus *Iltovirus*. These viruses are double-stranded DNA with a viral tegument and envelope.<sup>1</sup> Through their replication cycle, herpesviruses can establish latent infections and reactivate spontaneously; as a result, infected individuals may serve as lifelong reservoirs of the virus.<sup>2,3</sup> The initial herpesvirus infection is acute and usually occurs in cells or epithelial tissues where virus replication is efficient.<sup>3,4</sup> Four genotypes of herpesvirus have been identified so far, including virulent and non-virulent strains, all of which have the potential to cause disease.<sup>5</sup> Most disturbingly, infected birds can act as asymptomatic carriers of herpesvirus. For example, the Patagonian Conure (*Cyanoliseus patagonus*), Nanday Conure (*Nandayus nenday*), and golden parrot (*Aratinga solstitialis*) have been implicated in outbreaks of herpesvirus infection without showing signs of the disease. New world Psittaciformes such as macaws and *Amazona* spp. are considered highly susceptible, whereas old world Psittaciformes appear to be more resistant to herpesvirus.<sup>6-9</sup> Birds that survive infection become latent carriers, and stressors, such as concomitant infections, malnutrition, reproductive periods, thermal variations, and environmental changes, can cause carriers to release the virus in their faeces without showing any symptoms.<sup>10</sup>

The clinical presentation of herpesvirus may be acute and lack clinical signs. However, when clinical signs are present, they include depression, anorexia, diarrhoea, regurgitation, bristling plumage, elimination of yellow-greenish urates, tremors and, less frequently, conjunctivitis and sinusitis.<sup>6</sup> Additionally, lesions may be observed in various organs, such as the liver, spleen, kidneys, and intestines. The liver may be enlarged and may exhibit multiple foci of yellowish discoloration with haemorrhagic centres. The kidneys may be enlarged, and the intestinal mucosa may be hyperaemic or haemorrhagic. Herpesviruses can induce the formation of intranuclear inclusion bodies, which are frequently found in the liver but have also been identified in other organs, such as the kidneys, spleen, pancreas, and large intestines.<sup>11</sup>

The illegal trafficking of exotic birds in Mexico is concerning because it may promote the entry of birds with latent infections and thereby endanger the health of endemic psittacines.<sup>12</sup> The objective of this study was to identify the presence of herpesvirus in endemic and exotic psittacines in Mexico, based on the results of polymerase chain reaction (PCR) assays and pathological studies.

## Materials and methods

### Study population

Fifty psittacines in captivity were involved in the study. Forty-five were clinically healthy, and five presented with clinical features suggestive of herpesvirus infection. The study sample included 13 native birds representing six species (*Amazona autumnalis*, *Amazona oratrix*, *Amazona albifrons*, *Amazona farinosa*, *Ara militaris*, and *Cacatua galerita*) and 37 exotic birds representing nine species (*Agapornis* spp., *Nymphicus hallandicus*, *Myiopsitta monachus*, *Cyanoliseus patagonus*, *Ara ararauna*, *Eclectus roratus*, *Melopsittacus undulatus*, *Eupsittula canicularis*, and

*Aratinga mitrata*). The study was approved by the FESC Internal Committee on Animal Used, Care, and Experimentation code C14\_11.

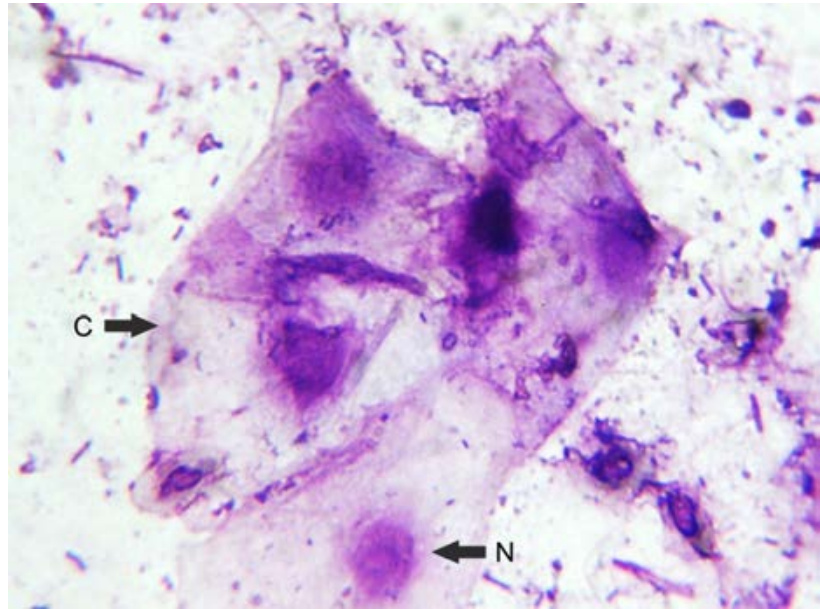
### Sample collection

Three methods for obtaining proctodaeal cells—(1) swabs, (2) interdental brushes, and (3) enemas—were evaluated prior to performing the study. These methods were initially performed in one bird with clinical signs of being infected with herpesvirus, and based on the results, the enema procedure was selected for the collection of cells from the 45 clinically healthy psittacines. After immobilizing each bird, 0.6 ml of Hank's 1× solution (In Vitro S.A. Mexico city, Mexico) was introduced through the cloaca using an insulin syringe without a needle. Then, the area was lightly massaged, and the solution was recovered in a microtube. The microtubes were centrifuged at 6000 rpm, and the pellets were resuspended in phosphate-buffered saline (PBS). The resulting suspensions were used for DNA extraction and for Wright's stained smears that were observed under a microscope.

### Polymerase Chain Reaction (PCR)

The primers used for PCR were designed based on sequences available in GenBank from psittacidae herpesvirus genotypes 1–4 (Accession numbers: **genotype 1** [NC\_005264, AF261756, JF313327, JF338866, JF338872, JF33886, AY282622, AB510906, AY421992, AY421979, and AY326284], **genotype 2** [AY282623 and AY282630], **genotype 3** [AY282641 and AY282635], and **genotype 4** [AY282660 and AY282669]). BioEdit and Primer3 Input V4.0 were used to design the primers. Two pairs of primers located in a portion of the UL16 gene, which is related to the expression of the viral tegument protein and, possibly, virion morphogenesis, were generated: PROFw 5'ATGCGCGTATCCGTATCTAA3', PRORv 5'ACAAAAGACAAAACGCATGG3' and RAVFw 5'CGAGCGACTTCTCAACGA3', RAVRv 5'CACAGCTGGGACTTAGATACG3'. These primers produced 301bp and 336bp amplification products, respectively.

The PCR reaction mixture included Buffer 1X (Kapa taq, Kapa Biosystems, Cape Town, South Africa), 0.08-U/μl Taq polymerase (Kapa taq, Kapa Biosystems, Cape Town, South Africa), 224 μM DNTPs (Kapa taq, Kapa Biosystems, Cape Town, South Africa), 2 mM MgCl<sub>2</sub> (Kapa taq, Kapa Biosystems, Cape Town, South Africa), 600 nM forward and reverse primers (Eurofins), and 500 ng of DNA in a 30-μl mixture. The amplification conditions were as follows: initial denaturation at 95 °C for 5 min; 40 cycles at 95 °C for 40 s (denaturation), 54 °C for 40 s (hybridization), and 72 °C for 30 s (elongation); and one final step of extension at 72 °C for 7 min. DNA from a psittacine without apparent clinical signs of herpesvirus infection was used as a negative control, and DNA from a red-lored parrot (*Amazona autumnalis*) with lesions suggestive of herpesvirus infection (necrotic hepatitis with intranuclear inclusion bodies, nephromegaly, and cerebral congestion) was used as a positive control. As expected, amplification products were corroborated in the positive control but not in the negative control. The amplification products were separated by electrophoresis, stained with ethidium bromide, and visualized using a transilluminator.



**Figure 1.** Epithelial cells collected from the proctodeum, which is the last portion of the colon and rectum. The cytoplasm (C) and nucleus (N) (Wright's stain, 100×) are observed.

Birds with clinical signs suggestive of herpesvirus infection that died were submitted for necropsy. The following organs were collected, fixed in 10% buffered formalin, and embedded in paraffin for histopathological studies: kidneys, liver, intestines, brain, and lungs.

## Results and discussion


Herpesvirus can be identified via PCR by detecting extracellular viral particles during phases of active infection as well as during periods of latency. Herpesviruses generate latency in nervous system, lymphoid, and epithelial cells.<sup>13</sup> In the present study, three methods for obtaining proctodaeal epithelial cells from psittacines were evaluated, and an enema was found to be the most efficient. Smear loops<sup>5</sup> and swabs<sup>7</sup> have also been used to obtain intestinal epithelial cells. In this study, the swab method collected a small population of nucleated cells (fewer than three cells per observed field/100×), similar to that obtained using an interdental brush. In contrast, the enema method proved to be the most useful for obtaining nucleated proctodaeal cells from psittacines (Figure 1). This method collected a satisfactory number of cells (seven cells per observed field/100×) and resulted in less trauma and stress for the birds than the other two methods tested.

PCR was performed to detect herpesvirus in the collected cells. Primers that hybridized to a portion of the UL16 gene, a region that is frequently used for the identification of herpesviruses in psittacines, were used.<sup>5,11,14</sup> The expected amplification was achieved in two *M. monachus* birds (Table 1 and Figure 2) using PRO primers (301 bp) and in 7 psittacines (Agapornis spp: *A. ararauna*, *A. autumnalis* [n = 2], *M. monachus* [n = 2], and *A. mitrata* [Table 1]) with the RAV primers (336 bp). However, in paraffin-embedded tissue specimens, the herpesvirus

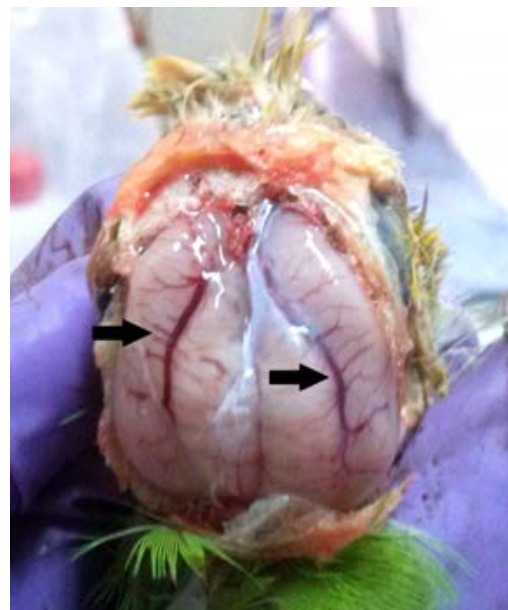
**Table 1.** The common and scientific names of the psittacines included in the study population, their status in Mexico, and the PCR results.

Common name	Scientific name	Status in country	PCR amplification product (bp)
Agaporni	<i>Agapornis</i> spp.	Exotic	Negative
Agaporni	<i>Agapornis</i> spp.	Exotic	Negative
Agaporni	<i>Agapornis</i> spp.	Exotic	Negative
Agaporni	<i>Agapornis</i> spp.	Exotic	Negative
Agaporni	<i>Agapornis</i> spp.	Exotic	Negative
Agaporni	<i>Agapornis</i> spp.	Exotic	Negative
Agaporni	<i>Agapornis</i> spp.	Exotic	Negative
Agaporni	<i>Agapornis</i> spp.	Exotic	Positive (336)
Agaporni	<i>Agapornis</i> spp.	Exotic	Negative
Agaporni	<i>Agapornis</i> spp.	Exotic	Negative
Cockatiel	<i>Nymphicus hollandicus</i>	Exotic	Negative
Cockatiel	<i>Nymphicus hollandicus</i>	Exotic	Negative
Cockatiel	<i>Nymphicus hollandicus</i>	Exotic	Negative
Cockatiel	<i>Nymphicus hollandicus</i>	Exotic	Negative
Cockatiel	<i>Nymphicus hollandicus</i>	Exotic	Negative
Monk parakeet	<i>Myiopsitta monachus</i>	Exotic	Negative
Monk parakeet	<i>Myiopsitta monachus</i>	Exotic	Negative
Monk parakeet	<i>Myiopsitta monachus</i>	Exotic	Negative
Monk parakeet	<i>Myiopsitta monachus</i>	Exotic	Positive (336)
Burrowing parrot	<i>Cyanoliseus patagonus</i>	Exotic	Negative
Blue-and-yellow macaw	<i>Ara ararauna</i>	Exotic	Positive (336)
Eclectus parrot	<i>Eclectus roratus</i>	Exotic	Negative
Red-lored parrot	<i>Amazona autumnalis</i>	Endemic	Negative
Budgerigar	<i>Melopsittacus undulatus</i>	Exotic	Negative
Sulphur-crested cockatoo	<i>Cacatúa galerita</i>	Endemic	Negative
Agaporni	<i>Agapornis</i> spp.	Exotic	Negative
Military macaw	<i>Ara militaris</i>	Endemic	Negative
Military macaw	<i>Ara militaris</i>	Endemic	Negative
Mealy parrot	<i>Amazona farinose</i>	Endemic	Negative
Yellow-headed amazon	<i>Amazona oratrix</i>	Endemic	Negative
Red-lored parrot	<i>Amazona autumnalis</i>	Endemic	Positive (336)
Monk parakeet	<i>Myiopsitta monachus</i>	Exotic	Negative
Monk parakeet	<i>Myiopsitta monachus</i>	Exotic	Positive (301)
Monk parakeet	<i>Myiopsitta monachus</i>	Exotic	Negative
Red-lored parrot	<i>Amazona autumnalis</i>	Endemic	Positive (336)
Agaporni	<i>Agapornis roseicollis</i>	Exotic	Negative
Monk parakeet	<i>Myiopsitta monachus</i>	Exotic	Positive (301)
Monk parakeet	<i>Myiopsitta monachus</i>	Exotic	Positive (336)
Mitred parakeet	<i>Aratinga mitrata</i>	Exotic	Positive (336)
Monk parakeet	<i>Myiopsitta monachus</i>	Exotic	Negative
Monk parakeet	<i>Myiopsitta monachus</i>	Exotic	Negative
Orange-fronted parakeet	<i>Eupsittula canicularis</i>	Exotic	Negative
Monk parakeet	<i>Myiopsitta monachus</i>	Exotic	Negative
White-fronted parrot	<i>Amazona albifrons</i>	Endemic	Negative
Red-lored parrot	<i>Amazona autumnalis</i>	Endemic	Negative
Yellow-headed amazon	<i>Amazona oratrix</i>	Endemic	Negative
Red-lored parrot	<i>Amazona autumnalis</i>	Endemic	Negative
Monk parakeet	<i>Myiopsitta monachus</i>	Exotic	Negative
Monk parakeet	<i>Myiopsitta monachus</i>	Exotic	Negative
Red-lored parrot	<i>Amazona autumnalis</i>	Endemic	Negative





**Figure 2.** The 301-bp amplification product (PRO primers) of the herpesvirus UL16 gene from DNA obtained from the proctodeum cells of an *M. monachus* (33). Mbp = base pair marker; C + = positive control; C- negative control.



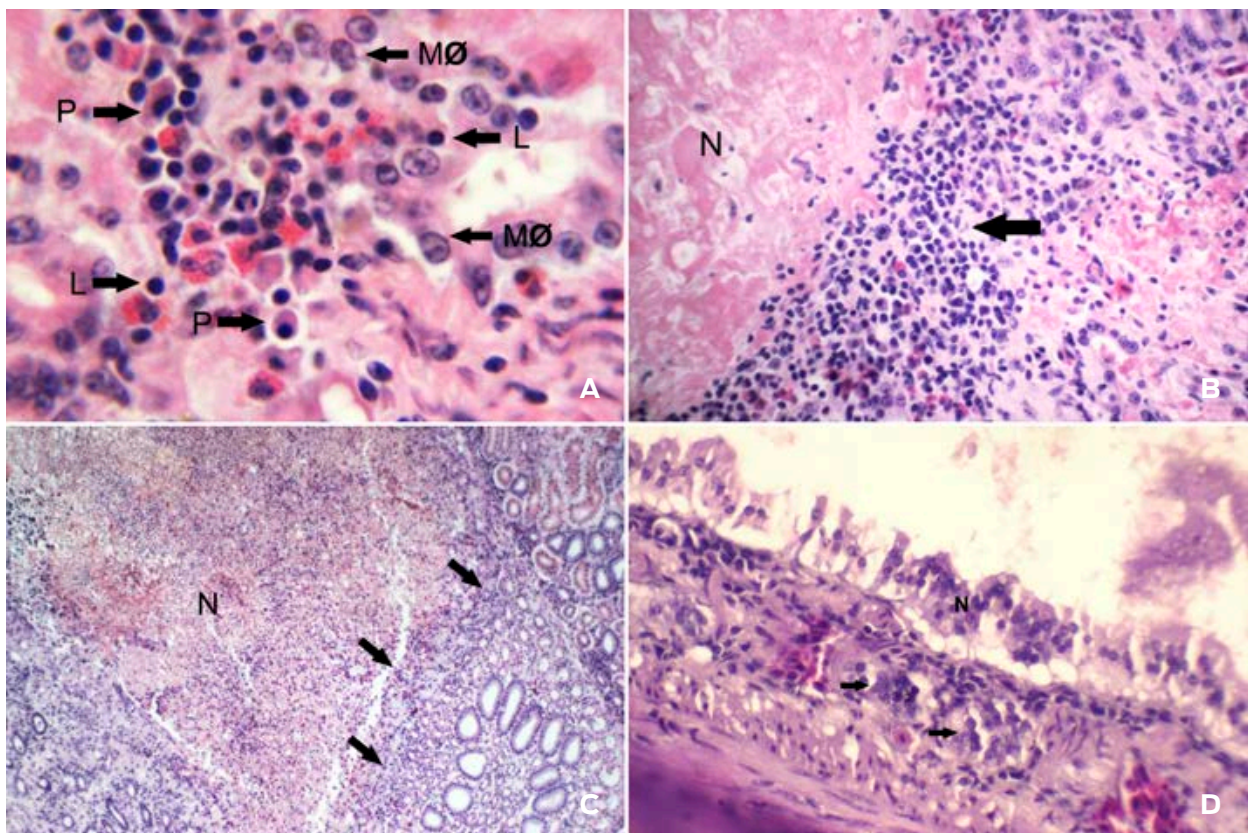
**Figure 3.** Congestion in the blood vessels of the brain. Highly congested and prominent blood vessels are indicated by arrows.

genome could not be amplified by PCR, possibly because of fragmentation, base modification, or oxidative damage in the formalin-fixed tissues. These changes degrade the sample material and negatively affect the DNA yield, as demonstrated in a study of a previously described DNA extraction method.<sup>15,16</sup>

Only five psittacines exhibited clinical signs suggestive of herpesvirus infection (*Amazona autumnalis* [n = 2] and *Myiopsitta monachus* [n = 3]), such as diarrhoea, dyspnoea, ataxia, and posterior limb paralysis. On necropsy, congestion in the blood vessels of the brain (Figure 3), enlarged livers with multiple zones of pale-yellow parenchyma (Figure 4), dark-brown kidneys with asymmetric discoloration, and haemorrhagic lungs were observed. Microscopically, mononuclear infiltrates were observed in various organs and predominantly consisted of lymphocytes and plasma cells (Figure 5 a). In the liver, kidneys, and intestines, multiple foci of coagulative necrosis surrounded by mononuclear infiltrates were identified (Figures 5 b,c,d). Additionally, neurophagia and satellites were identified in the grey matter of the brain (Figure 6 a), and intranuclear inclusion bodies exhibiting basophilic

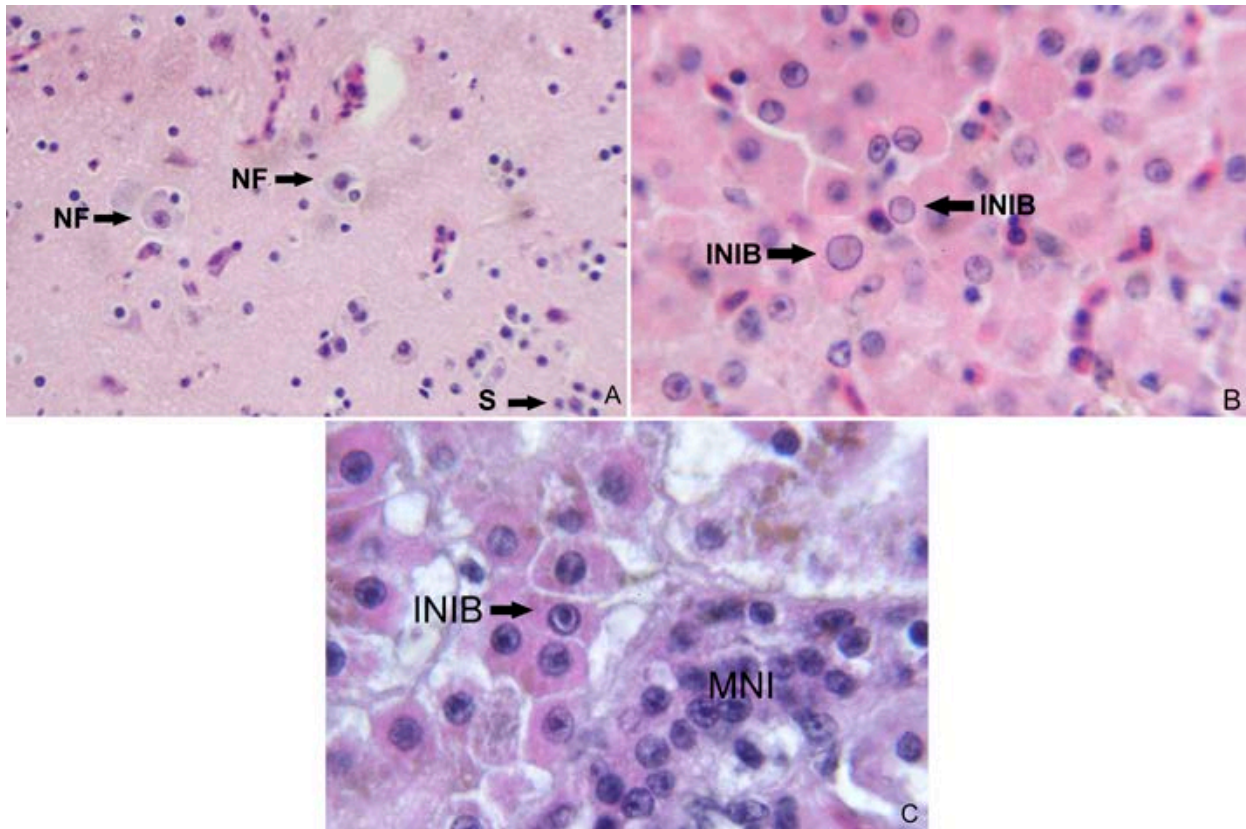


**Figure 4.** Liver with hepatomegaly. Rounded edges and blackish-red coloration interspersed with areas of apparently normal color were observed. Additionally, pale-yellow areas were distributed in the parenchyma.



**Figure 5.** a) Liver with mononuclear infiltrate (MNI) (100× magnification). The image shows the parenchyma at the interstitial level with a mononuclear inflammatory infiltrate characterized by the presence of lymphocytes (L), plasma cells (P), and macrophages (MØ). b) Liver with necrosis and mononuclear infiltrate (40× magnification). Zones of coagulative necrosis (N) delimited by the inflammatory mononuclear infiltrate (arrow) are evident. c) Kidney with necrosis and mononuclear infiltrate (10× magnification). Renal parenchyma with extensive areas of coagulative necrosis (N) between the cortex and the medulla were observed. These areas were characterized by a marked loss of architecture and cellular detail and were delimited by mononuclear inflammatory cells (arrows). d) Necrotic intestine (100× magnification). The intestine developed severe coagulative necrosis (N) throughout the mucosa. Additionally, inflammatory infiltrates of mononuclear cells were observed near the basal membrane of the mucosa (arrows).





**Figure 6.** a) Brain with neuronophagia and satellites (40× magnification). Neuronophagia (NF) is evident in the gray matter and is characterized by glial cells phagocytizing neurons and invading the perineural space surrounded by satellites (S). b) Liver with intranuclear inclusion bodies (INIB) (100× magnification). Multiple inclusion bodies (arrows) were observed in the liver parenchyma. c) Kidney with mononuclear infiltrate (MNI) and intranuclear inclusion bodies (100× magnification). In the renal parenchyma of the cortex at the tubular epithelium level, severe cellular swelling leading to coagulative necrosis was observed. As a result, the occurrence of pyknotic nuclei and karyolysis and presence of intranuclear inclusion bodies (INIB) were exacerbated. MNI took place in parallel.

colouring were identified in the liver (Figure 6 b) and kidneys (Figure 6 c). Lesions similar to those found in the liver and kidneys in this study have been previously reported. Although only 10% of the psittacine samples studied here exhibited clinical signs suggestive of herpesvirus infection, intranuclear inclusion bodies in the liver and kidneys were observed and were associated with severe mononuclear infiltrates in two psittacines. These findings suggest a strong tissue reaction to virus replication and infection in the tissues.<sup>17,18</sup> As described elsewhere and confirmed here, PCR is a useful technique for the identification of herpesvirus in apparently sick birds, although previous PCR-based detections were achieved using cell cultures for viral isolation.<sup>5,11,18,19</sup>

In the present study, 90 % (45/50) of the birds were clinically healthy, and PCR results revealed that of these 45 birds, eight were positive for herpesvirus. These results demonstrate that PCR is a good technique for diagnosing latent herpesvirus infections in psittacines. In contrast, herpesvirus infection was confirmed by PCR in only one psittacine with suggestive clinical signs and lesions of herpesvirus infection (data not shown) because an enema could only be performed in one of the birds that exhibited clinical signs. In the other four cases, only organ



collection was conducted. These results suggest that the PCR primers used in this study were adequate for the detection of latent infections in proctodaeal cells. Given that all herpesviruses remain in their natural hosts, generating latent infections and stress-induced asymptomatic reactivation that favour virus excretion and transmission to new susceptible individuals,<sup>3,4</sup> it is important to emphasize that among the psittacines identified as positive by PCR were several Monk parakeets (*M. monachus*) (5/9), an Agaporni, and a Mitred parakeet, which are exotic birds. Two domestic birds (a blue-and-yellow macaw and red-lored parrot) were also identified.

## Conclusions

The method of obtaining proctodaeal epithelial cells by enema proved to be efficient and allowed us to identify herpesvirus DNA in clinically healthy birds, thereby demonstrating latent infections. The results of PCR, along with the histopathological findings, revealed herpesvirus infection in clinically healthy endemic and exotic psittacines in Mexico, highlighting the need for broader studies on psittacine populations and the establishment of regulations by the country's health authorities to regulate the entry of imported birds, thereby preserving the health of Mexico's psittacines.

---

## Funding

This study was supported by PIAPIC27/FESC/UNAM.

## Acknowledgements

We thank bird's owners who kindly provided the samples.

## Conflicts of interest

The author(s) declare no potential conflicts of interest with respect to the research, authorship, and publication of this article.

## Author contributions

Montserrat Turrall performed the experimental work. Rodolfo Córdova and Hugo Ramírez led the research and experimental design, analysed the data and wrote part of the manuscript. Cynthia González, Germán Garrido and Ernesto Marín processed and interpreted the pathological results and wrote part of the manuscript, and Graciela Castañeda processed and interpreted the results obtained from proctodaeal cell swabs.

## References

1. International Committee on Taxonomy of Viruses ICTV [Internet]. Virus taxonomy; 2016. Available from: [www.ictvonline.org/virustaxonomy.asp](http://www.ictvonline.org/virustaxonomy.asp).
2. MacLachlan NJ, Dubovi EJ. Fenner's veterinary virology. 4th ed. London (UK): Elsevier Academic Press; 2011.
3. Norkin LC. Virology: Molecular biology and pathogenesis. Washington DC (US): ASM Press; 2010.

4. Carrasco-Llamas L, Almendral JM, Alcamí A, Carrascosa JL, Carrascosa ÁL, Enjuanes L, et al. Virus patógenos. Madrid (SP): Hélice y Fundación BBVA; 2006.
5. Tomaszewski EK, Wigle W, Phalen DN. Tissue distribution of psittacid herpesviruses in latently infected parrots, repeated sampling of latently infected parrots and prevalence of latency in parrots submitted for necropsy. *J Vet Diagn Invest.* 2006;18:536–44. doi: 10.1177/104063870601800603.
6. Bistyák A, Kecskeméti S, Glávits R, Tischler I, Nagy ST, Kardos G, et al. Pacheco's disease in a Hungarian zoo bird population: a case report. *Acta Vet Hung.* 2007;55:213–8.
7. Gilardi KV, Lowenstine LJ, Gilardi JD, Munn CA. A survey for selected viral, chlamydial, and parasitic diseases in wild dusky-headed parakeets (*Aratinga weddellii*) and tui parakeets (*Brotogeris sanctithomae*) in Peru. *J Wildl Dis.* 1995;31:523–8.
8. Ritchie BW, Harrison GJ, Harrison LR. Avian medicine. Principles and application. Florida (US) Wingers Publishing, Inc.; 1994.
9. Tomaszewski E, Wilson VG, Wigle WL, Phalen DN. Detection and heterogeneity of herpesviruses causing Pacheco's disease in parrots. *J Clin Microbiol.* 2001;39(2):533-8. doi: 10.1128/JCM.39.2.533-538.2001.
10. Cambrico Biotech [Internet]. Enfermedad de Pacheco: Herpesvirus. 2015. [Available from: [http://www.cambri.co/docs/aves/FichaTecnica\\_Pacheco.pdf](http://www.cambri.co/docs/aves/FichaTecnica_Pacheco.pdf).
11. Katoh H, Yamada S, Hagino T, Ohya K, Sakai H, Yanai T, et al. Molecular genetic and pathogenic characterization of psittacid herpesvirus type 1 isolated from a captive galah (*Eolophus roseicapillus*) in Japan. *J Vet Med Sci.* 2011;73(10):1341–5.
12. Procuraduría Federal de Protección al Ambiente (PROFEPA) [Internet]. Tráfico ilegal de especies. Ciudad de México (MX): gob.mx; c2010 [updated 27 November 2014]. 2014. Available from: [http://www.profepa.gob.mx/innovaportal/v/436/1/mx/trafico\\_ilegal\\_de\\_especies.html](http://www.profepa.gob.mx/innovaportal/v/436/1/mx/trafico_ilegal_de_especies.html).
13. Shivaprasad HL, Phalen DN. A novel herpesvirus associated with respiratory disease in Bourke's parrots (*Neopsephotus bourkii*). *Avian Pathol.* 2012;41:531-9. doi: 10.1080/03079457.2012.732692.
14. Tomaszewski EK, Kaleta EF, Phalen DN. Molecular phylogeny of the psittacid herpesviruses causing Pacheco's disease: correlation of genotype with phenotypic expression. *J Virol.* 2003;77:11260–7. doi: 10.1128/JVI.77.20.11260-11267.2003.
15. Skage M, Schander C. DNA from formalin-fixed tissue: extraction or repair? That is the question. *Mar Biol Res* 2007; 3:289–95. doi: 10.1080/17451000701473942.
16. Paireder S, Werner B, Bailer J, Werther W, Schmid E, Patzak B, et al. Comparison of protocols for DNA extraction from long-term preserved formalin fixed tissues. *Anal Biochem.* 2013; 439:152–60.
17. Katoh H, Ogawa H, Ohya K, Fukushi H. A review of DNA viral infections in psittacine birds. *J Vet Med Sci.* 2010; 72:1099–106. doi: 10.1292/jvms.10-0022.
18. Miranda-Luppi M, Luiz AP, Coelho FM, Malta MdC, Preis IS, Ecco R, et al. Identification and isolation of psittacid herpesvirus from psittacids in Brazil. *Vet Microbiol.* 2011;154(1-2):69-77. doi: 10.1016/j.vetmic.2011.06.027.
19. Tomaszewski EK, Gravendyck M, Kaleta EF, Phalen DN. Genetic characterization of a herpesvirus isolate from a superb starling (*Lamprolornis superbus*) as a psittacid herpesvirus genotype 1. *Avian Dis.* 2004;48(1):212–4.