

Natural *Cysticercus fasciolaris* infection in rodents from a rural area in Yucatan, Mexico

Rodrigo A. Medina-Pinto¹
Marco A. Torres-Castro^{2,*}
Rolando A. Medina-Pinto³
Manuel E. Bolio-González⁴
Roger I. Rodríguez-Vivas¹

¹Laboratorio de Parasitología,
Campus de Ciencias Biológicas y Agropecuarias,
Universidad Autónoma de Yucatán, Mérida,
Yucatán, México

²Laboratorio de Enfermedades
Emergentes y Reemergentes,
Centro de Investigaciones Regionales
Dr. Hideyo Noguchi, Mérida, Yucatán, México

³Facultad de Medicina,
Universidad Autónoma de Yucatán, Mérida,
Yucatán, México

⁴Departamento de Salud Animal
y Medicina Preventiva,
Campus de Ciencias Biológicas y Agropecuarias,
Universidad Autónoma de Yucatán,
Mérida, Yucatán, México

***Corresponding author:**
Tel: (999)9245809.
Email address:
antonio.torres@correo.uady.mx;
mrc.torres@gmail.com

Abstract

Cysticercus fasciolaris is the larval stage of *Taenia taeniaeformis*, a parasite that predominantly affects felines. It, however, has zoonotic significance since humans can be accidental hosts. Rodents and lagomorphs act as Intermediate hosts in this parasite's life cycle. The aim of this study was to determine the natural occurrence of infection with *Cysticercus fasciolaris* in rodents from a rural area in Yucatan, Mexico. Rodents were captured in 40 dwellings and two neighboring areas of low deciduous forest. A total of 153 individuals of seven different species were captured: 65 *Rattus rattus* (42.5%), 44 *Mus musculus* (28.8%), 22 *Heteromys gaumeri* (14.4%), 11 *Otodylomys phyllotis* (7.2%), 9 *Peromyscus yucatanicus* (5.9%), 1 *Peromyscus leucopus* (0.6%), and 1 *Sigmodon hispidus* (0.6%). All animals were examined for evidence of parasitic liver infection. *Rattus rattus* was the only species to present positive *Cysticercus fasciolaris* infection (18.5%, 12/65). We thus concluded that there was no evidence of a transmission cycle with wild rodent species.

Keywords: Natural infection, *Cysticercus fasciolaris*, *Rattus rattus*, Yucatan.

Accepted: 2019-03-21

Published: 2019-06-28

Additional information and declarations
can be found on page 7

© Copyright 2019
Rodrigo A. Medina-Pinto et al.

open access 



Distributed under Creative Commons CC-BY 4.0

Cite this as:

Medina-Pinto RA, Torres-Castro MA, Medina-Pinto RA, Bolio-González ME, Rodríguez-Vivas RI. Natural *Cysticercus fasciolaris* infection in rodents from a rural area in Yucatan, Mexico. VetMéxOA;2019(2). doi: [fmvz.24486760e.2019.2.590](https://doi.org/10.22201/fmvz.24486760e.2019.2.590).

Introduction

Cysticercus fasciolaris is the larval stage of the adult tapeworm *Taenia taeniaeformis* (Cestoda), a parasite that presents a global distribution and develops mainly in the small intestine of domestic (*Felis catus*) and wild felines (e.g., *Felis rufus*, *Felis silvestris*, and *Panthera pardus*).^{1,2} Felines get infected naturally by consuming contaminated livers from intermediate hosts.³ However, infection has also been identified in domestic (*Canis lupus familiaris*) and wild canines, such as red foxes (*Vulpes vulpes*), and coyotes (*Canis latrans*).^{4,5} Laboratory animals that have been experimentally infected with *C. fasciolaris* have a prepatent period of 34-80 days (41.1 ± 5.9), at the end of which the ingested larvae has developed and become fully infectious.⁶ An adult *T. taeniaeformis* tapeworm produces close to 12,000 partially developed eggs (called oncospheres) daily, which are released from the proglottids of the parasite, and shed into the environment with infected host feces.⁷ Intermediate hosts of *T. taeniaeformis* are mainly small rodents and lagomorphs, which can become infected by consuming food or water contaminated with viable oncospheres.⁸ Under experimental conditions, one-month old white mice can get infected with low numbers of eggs (200-500), and develop 11-250 metacestodes in the liver.^{9,10}

Taenia taeniaeformis eggs lose their membrane in the stomach or intestine of intermediate hosts soon after being ingested, releasing larvae that pass through the intestinal wall. Larvae then migrate via the hepatic portal system, reach the liver and develop into *C. fasciolaris* metacestodes (also known as *Hydatigera fasciolaris*, *Strobilocercus fasciolaris*, or *Taenia crassicolis*). The *Taenia taeniaeformis* life cycle is completed when a definitive host (feline) ingests an infected intermediate host.^{3,11}

Taenia taeniaeformis is a parasite with zoonotic significance because humans can act as accidental hosts. Adult parasites and metacestodes (*C. fasciolaris*) have been detected in intestines and liver of people from Argentina, Czech Republic, Denmark, Taiwan, and Sri Lanka.¹²⁻¹⁴

Synanthropic species such as *Rattus norvegicus*, *Rattus rattus*, and *Mus musculus* are the main intermediate hosts of this parasite, with prevalence ranging from 4.3%¹⁵ to 67.7%.¹⁶ *Cysticercus fasciolaris* infection has been reported in urban and wild rodents from Brazil,¹⁷ Korea,¹⁸ Egypt,¹⁹ India,²⁰ Malaysia,²¹ Thailand,²² and Mexico.²³⁻²⁵

Rodents from the *R. rattus* and *M. musculus* species have been found infected with *C. fasciolaris*, in Yucatan.²⁵ It is still unknown however if wild indigenous rodent species also act as intermediate hosts. This study aimed to determine if infection with *C. fasciolaris* occurs naturally in synanthropic and/or wild rodents, captured in a rural environment in Yucatan, Mexico.

Materials and methods

Study site

A rural tropical community in Cenotillo, Yucatan, Mexico (20°57'N, 88°36'W), with an annual average temperature and rainfall of 25.8 °C and 1,180 mm, respectively, was chosen for this study. The region has a rural settlement with neighboring areas of low deciduous forest, and small extensions of medium-highland forest.^{26,27}

Rodent capture

Rodents were captured from June to December 2016, in dwellings from the study locality and in two undisturbed small areas of low deciduous forest, located 9 km away from the rural settlement. Animal capture followed the guidelines of the American Society of Mammalogists (ASM).²⁸ Both capture and sampling were approved by the Bioethics and Animal Welfare Committees of the Autonomous University of Yucatan (Biological and Agricultural Sciences Campus) (Registry: CB-CCBA M-2016-004) and of the Ministry of Environment and Natural Resources of Mexico (Registry: SGPA/DGVS/00867/17).

Synanthropic rodents were captured by dividing the study locality in four quadrants, by tracing two perpendicular axes that crossed the center of the community, according to the methodology described by Torres-Castro *et al.*^{29,30} Ten dwellings (40 in total) were sampled in each quadrant over two consecutive nights and in two different weeks within one month. Twelve Sherman traps of 8 × 9 × 23 cm (HB Sherman traps Inc[®], Florida, USA) were placed inside the household and throughout the backyard, close to areas where there was evidence of or suspected rodent activity and near potential sources of food or/and lodging.

For wild rodent capture, 100 Sherman traps were distributed along 10 linear transects through the low deciduous forest extensions. Ten traps were placed per transect at 5-6 m intervals. Traps were checked with similar periodicity as that followed and previously described for dwelling quadrants.

All traps were placed in the morning and checked the following day. Bait was a mixture of oat flakes and artificial vanilla flavoring. Species identification of captured rodents was performed by veterinarians, based on the guidelines described in "A Field Guide to the Mammals of Central America and Southeast Mexico".³¹

Biological sampling

Captured rodents were transported alive to the parasitology laboratory of the Biological and Agricultural Sciences Campus at the Autonomous University of Yucatan. Animals were anesthetized upon arrival by intraperitoneal sodium pentobarbital injection (130 mg/kg) and euthanized by cervical dislocation, according to American Veterinary Medical Association guidelines.³² Species identification, biometry sex, and age of individuals were determined post mortem.

Abdominal cavity and liver of all rodents were macroscopically inspected to determine the presence of *C. fasciolaris* cysts. The larval capsule of found cysts was opened, metacestodes were extracted and preserved in 70% ethanol for morphological identification.

Metacestodes were stained with Semichon's acetic carmine, mounted on slides with Canada balsam medium and observed under a conventional stereoscope (OLYMPUS-SZ51, Tokyo, Japan). Characterization was performed according to morphological traits described by Bowman *et al.*³³ and Malsawmtluangi *et al.*²⁰

Results and discussion

A total of 153 rodents from seven different species were captured. Most individuals (107, 69.9%) were captured in households and backyards. From these, *R.*

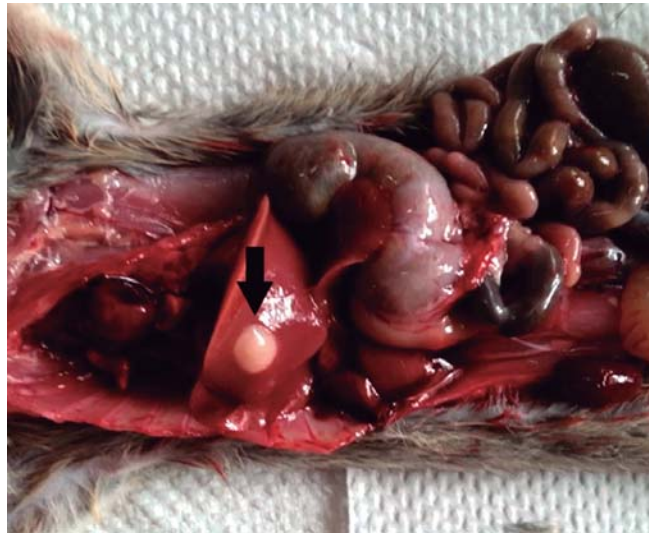


Figure 1. *Cysticercus fasciolaris* cyst (arrow) in a *Rattus rattus* liver. Cenotillo, Yucatan, Mexico.

rattus species was the most abundant (63/107, 58.9%), followed by *M. musculus* (43/107, 40.2%), and *Peromyscus yucatanicus* (1/107, 0.9%). For rodents captured in low deciduous forest areas (46, 30.1%), the most abundant species was *Heteromys gaumeri* (22/46, 47.8%), followed by *Otodylomys phyllotis* (11/46, 23.9%), *P. yucatanicus* (8/46, 17.4%), *R. rattus* (2/46, 4.3%), *Peromyscus leucopus* (1/46, 2.2%), *Sigmodon hispidus* (1/46, 2.2%), and *M. musculus* (1/46, 2.2%).

The overall infection was 7.8% (12/153). *Cysticercus fasciolaris* cysts were found only in animals of the *R. rattus* species captured in households. Frequency of infection in *R. rattus* captured both in households and forest patches was 18.5% (12/65), from which 91.7% of the animals (11/12) presented with a single cyst and 8.3% (1/12) with two cysts. Of these 12 infected *R. rattus*, 75% (9/12) were females and 25% (3/12) males; 58.3% (7/12) were juveniles and 41.7% (5/12) adults.

All *C. fasciolaris* cysts were almost white and slightly adhered to the liver parenchyma (Fig. 1). Each cyst presented a fibrous capsule of variable thickness, surrounding a slightly coiled white larva, suspended in an opalescent fluid. Extracted larvae measured between 2 and 11 cm in length.

Larvae were morphologically characterized by identifying a large extruded scolex with four lateral suckers and two rows of hooks (larger and smaller hooks in outer and inner rows respectively; Fig. 2). Also, pseudo-segmentations were detected along the strobila (which is found posterior to the scolex and includes the proglottids), and a relatively small terminal bladder was seen. *Cysticercus fasciolaris* is the only metacestode in which the scolex is not invaginated at the bladder but rather attached to it by the strobile.³³

The distribution of *Taenia taeniaeformis* and *C. fasciolaris* (larval stage) is ubiquitous. Adult parasites located in intestines of definitive hosts rarely cause clinical signs; however, evidence of disease can relate to the degree of infection, age, body condition, and even host species.³³ In contrast, intermediate hosts infected with *C. fasciolaris* tend to develop more signs and lesions.³⁴

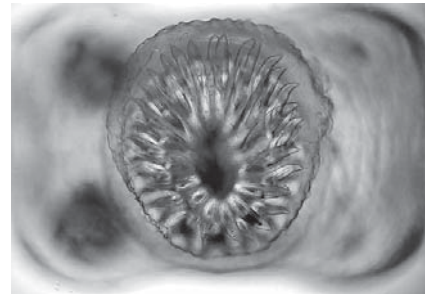


Figure 2. Scolex of *Cysticercus fasciolaris* with four lateral suckers and an armed rostellum with two rows of hooks. Sample collected from a *Rattus rattus* captured in Cenotillo, Yucatán, Mexico.

Two transmission cycles have been described for *C. fasciolaris*: an urban cycle, in which domestic cats and synanthropic rodents are definitive and intermediate hosts, respectively; and a wild cycle, in which a large variety of wild canines and felines, as well as various species of rodents, can be involved. Indeed, Theis and Schwab,³⁵ reported a 3.4% prevalence of *T. taeniaeformis* in *Peromyscus maniculatus* from California, and Wanas *et al.*¹⁹ found the parasite in *Gerbillus gerbillus* (33.3%), *Acomys cahirinus* (16.6%), and *Arvicanthis niloticus* (7.2%). Moreover, the presence of *C. fasciolaris* was established in *R. rattus* wild populations in bamboo forests from Mizoram, India.²⁰

None of the rodents captured from wild environments in this study were positive for *C. fasciolaris* infection. Absence of a wild transmission cycle that includes rodents may be due to the presence of five indigenous wild feline species that can act as final hosts: *Herpailurus yagouaroundi*, *Leopardus pardalis*, *Leopardus wiedii*, *Puma concolor*, and *Panthera onca*. Also, rodent relative population dispersion and density, associated with habitat loss, can adversely impact the efficacy of parasite life cycle maintenance in the region.³⁶⁻³⁹ Nonetheless, wild rodents from the Yucatan area can be infected by *C. fasciolaris* as documented for species such as *P. yucatanicus*, *H. gaumeri*, and *O. phyllotis*, that passthrough households located in rural communities that are associated with secondary forest patches.⁴⁰ These rodents could have become infected by consuming contaminated food or water contaminated with domestic cat feces parasitized with *T. taeniaeformis*. However, further studies are necessary to conclude this causal association.

Contrary to our findings, in which none of the sampled mice (*M. musculus*) were positive to infection. *Cysticercus fasciolaris* has been previously found in this species in a rural community in Yucatan.²⁴ This discrepancy between results could relate to genetic variations of the *C. fasciolaris* populations and their inherent ability to infect intermediate hosts. In effect, Brandt and Sewell reported distinct infectivity of four *T. taeniaeformis* isolates in mice and rats.⁴¹ Moreover, Nonaka *et al.* observed that *C. fasciolaris* cysts did not develop in rats, mice, or gerbils infected with *T. taeniaeformis* eggs derived from a metacestode isolated from a grey red-backed vole mouse (*Clethrionomys rufocanus bedfordiae*, currently *Myodes rufocanus*).⁴²

Other factors that affect *C. fasciolaris* transmission dynamics between intermediate (rodents) and definitive hosts (felids) are: 1) relative population density of hosts; 2) seasonal changes in host and parasite abundance; 3) seasonal vulnerability of parasite eggs due to changes of environmental conditions; 4) host sex; and

5) host age.^{24,35} Moreover, antibodies against *T. taeniaeformis* can be transmitted to the offspring of infected rats via colostrum⁴³. However, pups between 25 and 30 days of age seem to be more susceptible to experimental infection than adults or other age groups.^{44,45}

Stability and resilience of parasite eggs to changing environmental conditions may also impact infection prevalence in rodents since contaminated food and/or water sources can be constantly available for individuals geographically associated with definite hosts.²⁴

Conclusions

Results from this study confirm that synanthropic rodents in rural areas of the Yucatan region in Mexico are susceptible to *C. fasciolaris* infection. An infected *Rattus rattus* individual could hence contribute to maintain the parasite's life cycle as an intermediate host, potentially disseminating the infection to domestic cats. There was no evidence of a transmission cycle with wild rodent species.

Acknowledgements

We would like to thank the authorities and families from Cenotillo, Yucatan, Mexico, for their hospitality; Bayron Cruz, William Arcila and José Ortiz for their invaluable field work assistance; and LEII Irene Castillo-Rivas for manuscript revision and translation.

This research was partially supported by project "Vector-Borne Zoonosis in Yucatán: A One Health Approach" (FMVZ-2016-0007).

Conflicts of interest

The authors declare no conflicts of interest.

Author contributions

Rodrigo A.M.P.: animal capture and sampling, laboratory work, manuscript development and final approval; M.A.T.C.: project design, animal capture and sampling, manuscript development and final approval; Rolando A.M.P.: animal capture and sampling, laboratory work; M.E.B.G.: manuscript development and final approval; R.I.R.V.: project design, manuscript development and final approval.

References

1. Krone O, Guminsky O, Meinig H, Herrmann M, Trinzen M, Wibbelt G. Endoparasite spectrum of wild cats (*Felis silvestris* Schreber, 1777) and domestic cats (*Felis catus* L.) from the Eifel, Pfalz region and Saarland, Germany. *Eur J Wild Res.* 2008;54(1):95-100.
2. Stuti V, Swaid A, Deepesh S, Mir M. Parasitic ova and oocysts observed in intestinal contents of a leopard (*Panthera pardus*)-A case report. *J Vet Parasitol.* 2012;26(2):170-1.
3. Singla LD, Aulakh GS, Sharma R, Juyal PD, Singh J. Concurrent infection of *Taenia taeniaeformis* and *Isoospora felis* in a stray kitten: a case report. *Vet Med.* 2009; 54(2):81-3.
4. Custer JW, Pence DB. Ecological analyses of helminth populations of wild canids from the gulf coastal prairies of Texas and Louisiana. *J Parasitol.* 1981;67(3):289-307.
5. Smith GC, Gangadharan B, Taylor Z, Laurenson MK, Brandshaw H, Hide G, Hughes JM, Dinkel A, Romig T, Craig PS. Prevalence of zoonotic important parasites in the red fox (*Vulpes vulpes*) in Great Britain. *Vet Parasitol.* 2003;118(1-2):133-42.
6. Hutchison WM. Studies on *Hydatigera (Taenia) taeniaeformis*. II. Growth of the adult phase. *Exp Parasitol.* 1959;8(6):557-67.
7. Williams JF, Sheareer AM. Longevity and productivity of *Taenia taeniaeformis* in cats. *Am J Vet Res.* 1981;42(12):2182-3.
8. Karim AJ. Scanning electron microscopy and histological morphology of *Cysticercus fasciolaris*, which induced fibrosarcomas in laboratory rats. *Ann Micro.* 2010;10:44-8.
9. Hinz E. Vergleichende Untersuchungen an der experimentellen Zystizerkose von Ratte und Maus. *Z Tropenmed Parasitol.* 1962;13:182-94.
10. Yildiz K, Doganay A. The effect of albendazole and praziquantel on *Strobilocercus fasciolaris* in experimentally infected mice. *Turk J Vet Anim Sci.* 2001;25(3):287-94.

11. Moudgil AD, Singla LD, Gupta K, Daundkar PS, Vemu B. Histopathological and morphological studies on natural *Cysticercus fasciolaris* infection in liver of Wistar rats. *J Parasit Dis*. 2016;40(2):255-8.
12. Miyazaki I. An illustrated book of Helminthic zoonoses. Tokio: International Medical Foundation of Japan; 1991.
13. Ekanayake S, Warnasuriya ND, Samarakoon PS, Abewickrama H, Kuruppuarachchi ND, Dissanaikie AS. An unusual 'infection' of a child in Sri Lanka, with *Taenia taeniaeformis* of the cat. *Ann Trop Med Parasitol*. 1999;93(8):869-73.
14. Oryan A, Alidadi S. Public health concerns of *Taenidae* and their metacestodes. *Trop Med Surg*. 2015;3(1):e123.
15. Pakdel N, Naem S, Rezaei F, Chalehchaleh AA. A survey on helminthic infection in mice (*Mus musculus*) and rats (*Rattus norvegicus* and *Rattus rattus*) in Kermanshah, Iran. *Vet Res Forum*. 2013;4(2):105-9.
16. Sharma R, Tiwari K, Birmingham K, Armstrong E, Montanez A, Guy R, Sepúlveda Y, Mapp-Alexander V, DeAllie C. *Cysticercus fasciolaris* in Brown Rats (*Rattus norvegicus*) in Grenada, West Indies. *J Parasitol Res*. 2017;2017:1723406.
17. Bonfin TCB. Algumas observacoes sobre infeccao natural em *Rattus norvegicus* por *Cysticercus fasciolaris* (Eucestoda: Taeniidae). *Rev Bras Parasitol Vet*. 2001;10(2):79-82.
18. Lee BW, Jeon BS, Kim HS, Kim HC, Yoon BI. *Cysticercus fasciolaris* infection in wild rats (*Rattus norvegicus*) in Korea and formation of cysts by remodeling of collagen fibers. *J Vet Diagn Invest*. 2016;28(3):263-70.
19. Wanas MQ, Shehera KK, Rashed AA. Larval occurrence of *Hydatigera taeniaeformis* Batsch (1786) (Cestoda: Taeniidae) in the liver of wild rodents in Egypt. *J Egypt Soc Parasitol*. 1993;23(2):381-8.
20. Malsawmtluangi C, Prasad PK, Biswal DK, Tandon V. Morphological and molecular identification of the metacestode parasitizing the liver of rodent hosts in bamboo growing areas of mizoram, northeast India. *Bioinformation*. 2011;7(8):393-9.
21. Sinniah B, Narasiman M, Habib S, Bei O. Prevalence of *Calodium hepaticum* and *Cysticercus fasciolaris* in urban rats and their histopathological reaction in the livers. *J Vet Med*. 2014;2014:172829.
22. Ribas A, Saijuntha W, Agatsuma T, Thongjun C, Lamsan K, Poonlaphdecha S. Helminths in rodents from wet markets in Thailand. *Helminthologia*. 2016;53(4):326-30.
23. Pulido-Flores G, Moreno-Flores S, Monks S. Helminths of rodents (*Rodentia: muridae*) from Metztlán, San Cristóbal, and Rancho Santa Elena, Hidalgo, Mexico. *Comp Parasitol*. 2005;72(2):186-92.
24. Rodríguez-Vivas RI, Panti-May JA, Parada-López J, Hernández-Betancourt SF, Ruiz-Piña HA. The occurrence of the larval cestode *Cysticercus fasciolaris* in rodent populations from the Cuxtal ecological reserve, Yucatan, Mexico. *J Helminthol*. 2011;85(4):458-61.
25. Panti-May JA, Hernández-Betancourt SF, Rodríguez-Vivas RI, Robles MR. Infection levels of intestinal helminths in two commensal rodent species from rural households in Yucatan, Mexico. *J Helminthol*. 2015;89(1):42-8.
26. Secretaría de Desarrollo Social (SEDESOL). Unidad de microrregiones; Cédulas de información municipal, Cenotillo, Yucatán. [Internet]. 2017

- [cited 2018 Feb 3]; Available from: https://www.gob.mx/cms/uploads/attachment/file/47145/Yucatan_012.pdf
27. Instituto Nacional para el Federalismo y el Desarrollo Municipal (INAFED). Cenotillo; Enciclopedia de los municipios y delegaciones de México. [Internet]. 2017 [cited 2018 Feb 3]. Available from: <http://www.inafed.gob.mx/work/enciclopedia/EMM31yucatan/municipios/31012a.html>
 28. Sikes RS, the Animal Care and Use Committee of the American Society of Mammalogists. 2016 Guidelines of the American Society of Mammalogists for the use of wild mammals in research and education. *J Mammal*. 2016;97(3):663-88.
 29. Torres-Castro M, Gutiérrez-Ruiz E, Hernández-Betancourt S, Peláez-Sánchez R, Agudelo-Flórez P, Guillermo-Cordero L, et al. First molecular evidence of *Leptospira* spp. in synanthropic rodents captured in Yucatan, Mexico. *Revue Méd Vét*. 2014;165(7-8):213-8.
 30. Torres-Castro M, Cruz-Camargo B, Medina-Pinto R, Reyes-Hernández B, Moguel-Lehmer C, Medina R, et al. Detección molecular de leptospiras patógenas en roedores sinantrópicos y silvestres capturados en Yucatán, México. *Biomedica*. 2018;38(Supl 2):51-8.
 31. Reid FA. A field guide to the mammals of Central America and Southeast Mexico. New York: Oxford University Press; 1997.
 32. Leary S, Underwood W, Anthony R, Cartner S, Corey D, Grandin T, et al. AVMA guidelines for the euthanasia of animals. 2013 ed. Schaumburg, Illinois: American Veterinary Medical Association; 2013.
 33. Bowman DD, Lynn RC, Eberhard ML. Georgis' parasitology for veterinarians. 10th ed. Saint Louis, Missouri: Elsevier Saunders; 2014.
 34. Widmer D, Jurczynski K. Infection with the strobilocercus of *Taenia taeniaeformis* in a Malagasy giant jumping rat (*Hypogeomys antimena*). *J Zoo Wild Med*. 2012;43(4):914-21.
 35. Theis J, Schwab R. Seasonal prevalence of *Taenia taeniaeformis*: relationship to age, sex, reproduction and abundance of an intermediate host (*Peromyscus maniculatus*). *J Wild Dis*. 1992;28(1):42-50.
 36. Sosa-Escalante J, Hernández S, Segovia A, Sánchez-Cordero V. First record of the coyote, *Canis latrans* (Carnivora: Canidae) in the Yucatán Peninsula, Mexico. *Southwest Nat*. 1997;42(4):494-5.
 37. Faller-Menéndez JC, Urquiza-Haas T, Chávez C, Johnson S, Ceballos G. Registros de mamíferos en la reserva privada el zapotal, en el noreste de la península de Yucatán. *Rev Mex Mastozool*. 2005;9:128-40.
 38. Hernández-Pérez E, Reyna-Hurtado R, Castillo-Vela GC, Sanvicente-López M, Moreira-Ramírez FJ. Fototrampeo de mamíferos terrestres de talla mediana y grande asociados a petenes del noroeste de la península de Yucatán, México. *Therya*. 2007;6(3):559-74.
 39. Chávez C, Zarza H. Distribución potencial del hábitat del jaguar y áreas de conflicto humano-jaguar en la península de Yucatán. *Rev Mex Mastozool*. 2009;13(1):46-62.
 40. Panti-May JA, Hernández-Betancourt S, Ruiz-Piña H, Medina-Peralta S. Abundance and population parameters of commensal rodents present in rural households in Yucatan, Mexico. *Int Biodeterior Biodegradation*. 2012;66(1):77-81.
 41. Brandt JRA, Sewell MMH. Varying infectivity of *Taenia taeniaeformis* for rats and mice. *Vet Res Commun*. 1981;5(2):187-91.

42. Nonaka N, Iwaki T, Okamoto M, Ooi HK, Oku Y, Ohbayashi M, *et. al.* Infectivities of four isolates of *Taenia taeniaeformis* to various rodents. J Vet Med Sci. 1994;56(3):565-7.
43. Musoke AJ, Williams JF, Leid RW, Williams CSF. The immunological response of the rat to infection with *Taenia taeniaeformis*. IV. Immunoglobulins involved in passive transfer of resistance from mother to offspring. Immunology. 1975;29(5):845-53.
44. Singh BB, Rao BV. Experimental infection of *Cysticercus fasciolaris* in laboratory animals. Ann Parasitol Hum Comp. 1971;46(1):11-4.
45. Greenfield SH. Age resistance of the albino rat to *Cysticercus fasciolaris*. J Parasitol. 1942;28(3):207-11.